

## Diagnosis of the Early Lesions of Mycosis Fungoides

Bruce R. Smoller, MD  
Professor and Chair  
Hough Endowed Chair in  
Pathology  
Department of Pathology  
University of Arkansas for Medical  
Sciences

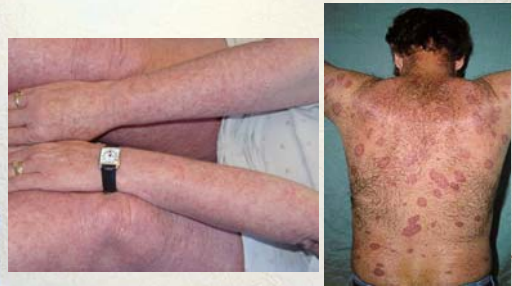## Context

- Early diagnosis is a clinical-pathologic correlation that often requires immunologic and molecular data to establish the diagnosis
- Reliance of purely histologic features raises a differential diagnosis (to be discussed in a later presentation)

## Context

- Usual clinical context is that of long-standing erythematous patches with slight scale
- Often on buttocks and flanks but can be any site
- Most common in middle-aged to elderly patients
- Most common type of CTCL; accounts for about 50% of all cutaneous lymphomas

## Clinical - Early MF



## Histologic features

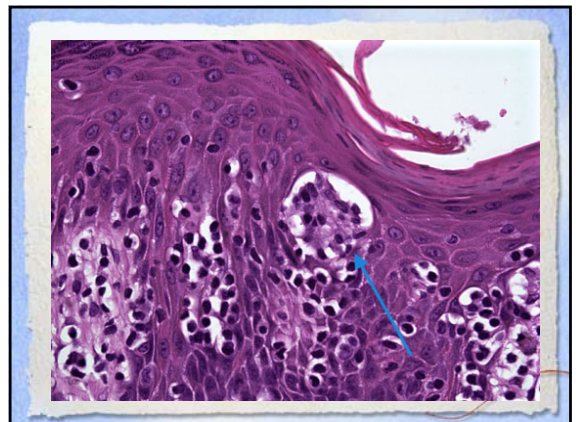
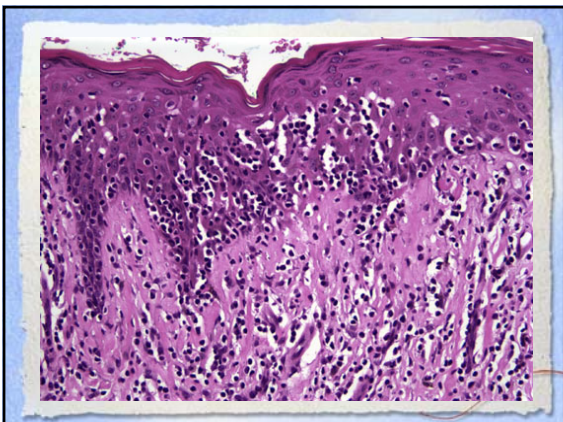
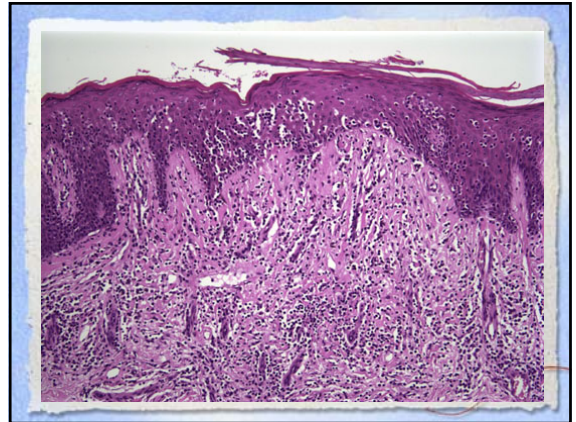
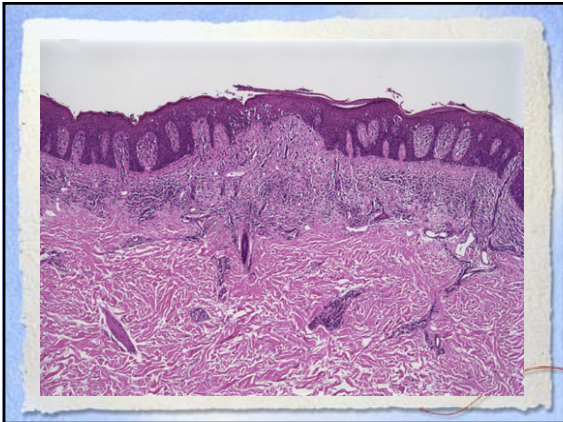
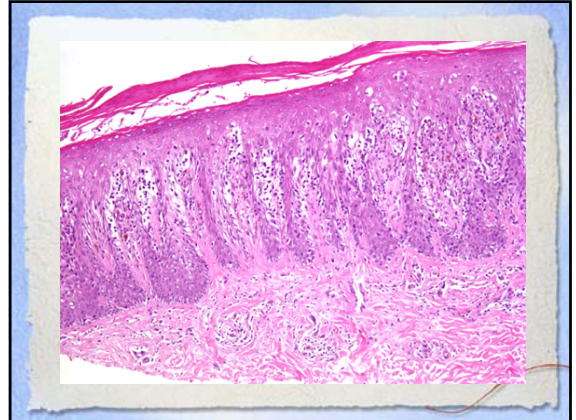
- Architectural
- Cytologic

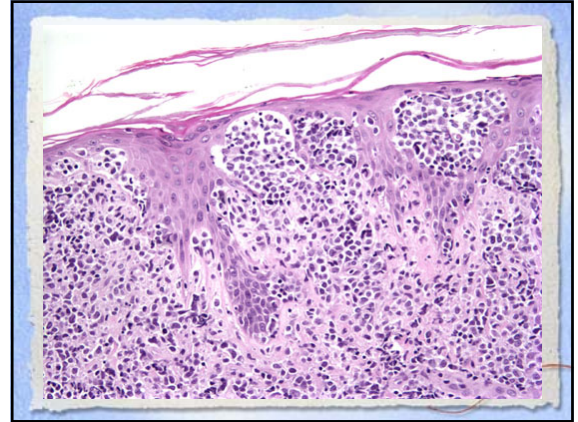
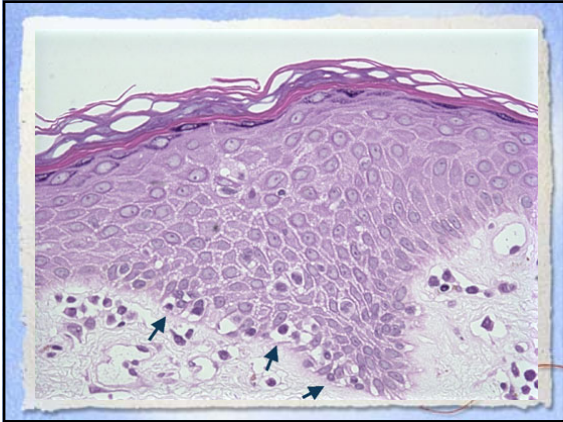
## Architectural features

- Cited in literature:
  - Psoriasiform epidermal hyperplasia or atrophy
  - Epidermotropism
  - Single lymphocytes along the DEJ
  - Collections of atypical lymphocytes within the epidermis (Pautrier's microabscesses)
  - Papillary dermal fibrosis
  - Superficial bandlike or patchy infiltrate of lymphocytes
  - "Naked underbelly" sign

## Architectural features

- Statistically good discriminators:
  - Halos around nuclei
  - Pautrier's microabscesses
  - Large single lymphocytes within epidermis
  - Single lymphocytes along dermal epidermal junction
  - Excess numbers of lymphocytes in epidermis compared with amount of spongiosis (epidermotropism)





## Architectural features

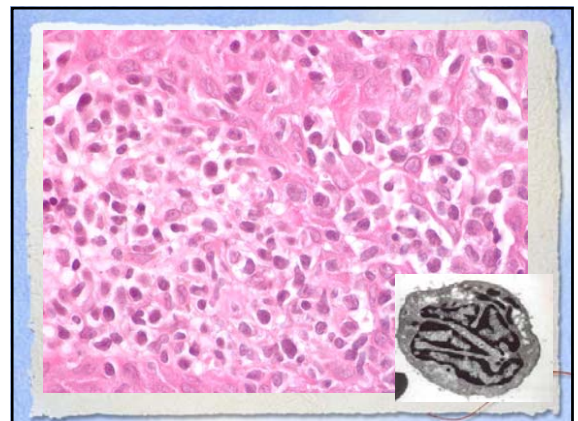
- Parameters that are not good discriminators:
  - Papillary dermal fibrosis
  - Acanthosis or atrophy
  - Dying keratinocytes
  - Dermal lymphocyte “atypia”
  - Presence of eosinophils and/or plasma cells
  - Mitotic activity - minimal in early stage lesions

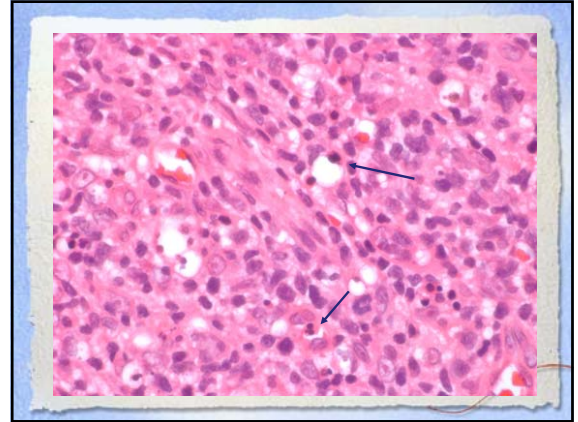
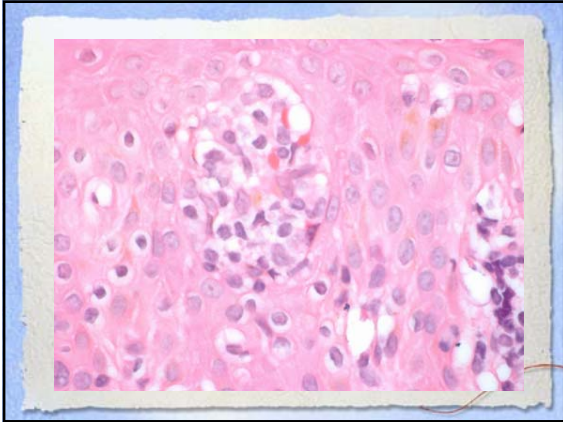
## Cytologic features

- Description in literature:
  - Small to medium-sized lymphocytes with indented, cerebriform nuclei (sometimes hyperchromatic)
  - Transformation to larger cells with vesicular nuclei and visible nucleoli occurs later in course of disease and is outside realm of this presentation

## Cytologic features

- Study results:
  - Intraepidermal lymphocytes - several studies confirm this as reproducible
    - Size - about size of keratinocyte nuclei
    - Shape - markedly convoluted as at low magnification
  - Dermal lymphocytes - not as useful - difficult to tell reactive dermal T cell from scattered atypical cells
    - Size
    - Shape





### Histologic features and prognosis

- Most patients with early patch/plaque stage MF have essentially normal life expectancy
- Small subset have rapidly progressive disease
- Not possible to discriminate these patients based upon histologic features of early biopsies - likely molecular fingerprint will provide the answers

### Overall prognosis

- Stage 1a (patches and plaques < 10% of body surface area): 97%-98% 10 year survival
- Stage 1b (patches and plaques > 10% of body surface area): 83% 10 year survival
- Tumors: 42% 10 year survival
- Lymph node involvement: 20% 10 year survival

### Ancillary techniques

- Immunostains
- T-cell gene rearrangement studies

### Useful Immunostains in Mycosis Fungoides

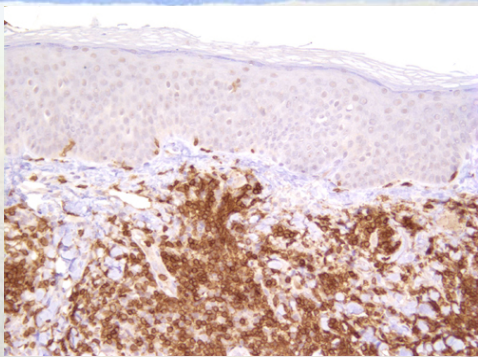
- CD2
- CD3
- CD4
- CD5
- CD8
- CD7
- CD30

## Immunostains in MF

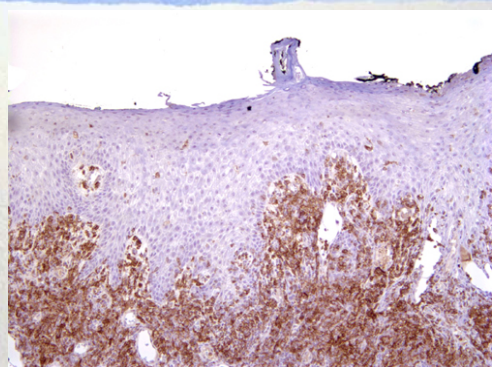
- Some disagreement about diagnostic criteria
  - Most authors include CD4+ and CD8+ epidermotropic T cell lymphomas into category of MF (WHO)
  - Minority prefer to separate CD8+ epidermotropic T cell lymphomas from the vast majority of CD4+ cases traditionally considered to be MF
  - Recent WHO Classification suggests same clinical course and prognosis and no reason to separate

## Immunostains in early lesions of MF

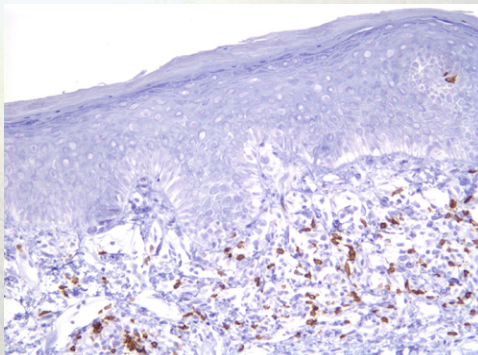
- Study results:
  - CD4+, CD8-, CD7- is most commonly observed phenotype
  - Loss of pan T-cell antigens CD2, CD3, CD5 also seen in minority of early cases
  - 75% of cases, immunostains served only to confirm H and E diagnosis
  - In series of 250 cases, immunostains based upon loss of pan T-cell surface antigens revealed an earlier diagnosis than H and E in 4% of cases - but remember the life expectancy data!



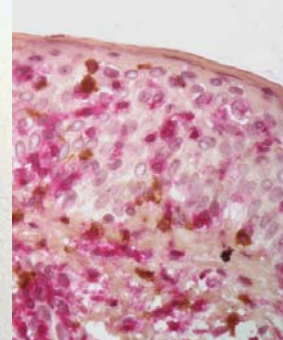
CD3



CD4



CD8



CD4/CD8 double labeling

Double-labeling of lymphocytes in the skin does not provide useful information

## T-cell gene rearrangements in Mycosis Fungoides

- Sensitivity
- Specificity

## T-cell gene rearrangements

- Sensitivity
  - > 80% of patch-stage lesions of MF will demonstrate a clonal rearrangement using PCR technology
    - Useful to confirm diagnosis if clinically suspicious and routine histology is less than fully diagnostic
    - “Negative” result does NOT rule out MF diagnosis
  - Close to 100% of later stage lesions demonstrate clonality, but not often needed in these cases

## T-cell gene rearrangements

- Specificity
  - Clonality has been demonstrated in lymphomatoid papulosis, “parapsoriasis” (small and large plaque), PLEVA, PLC - still controversial how these entities related to T cell lymphoproliferative disorders
  - Also demonstrated in disease with no known potential for malignant transformation:
    - Lichen planus
    - Pigmented purpuric eruption
  - Important to have high index of suspicion when ordering test and to interpret findings in context to avoid over diagnosis
    - “Positive” result does not necessarily imply MF diagnosis

## Genetic aberrations in MF

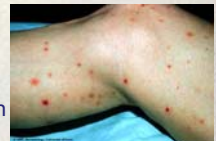- Chromosomal loss at 10q and abnormalities in p15, p16 and p53 tumor suppressor genes commonly seen in patients with MF - not specific
- No specific chromosomal translocations associated with MF

## Differential diagnosis

- Pityriasis lichenoides chronica
- Digitate dermatosis (small plaque parapsoriasis, guttate parapsoriasis)
- Pityriasis rubra pilaris
- Lymphomatoid papulosis

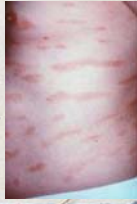## Pityriasis lichenoides chronica

- Smaller, more discrete lesions
- Less intense infiltrate
- Scattered dying keratinocytes (unusual finding in MF)
- Slight hemorrhage
- Lack of Pautrier’s microabscesses, single atypical lymphocytes within epidermis and along DEJ



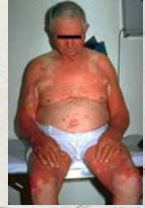## Digitate dermatosis

- Characteristic clinical appearance
- Small foci of epidermotropism, often with mild spongiosis
- Lymphocyte “atypia” not present
- No Pautrier’s microabscesses



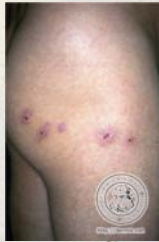## Pityriasis rubra pilaris

- Clinical “skip areas” helpful if present
- Psoriasiform hyperplasia with scattered dying keratinocytes
- Pattern of alternating ortho- and parakeratosis
- Folliculo-centric process
- Minimal lymphoid infiltrate



## Lymphomatoid papulosis

- Often multiple small papules/nodules without plaques
- Deeper infiltrate than MF
- Often many eosinophils
- Cytologic atypia in most cases more dramatic than in early MF



## Arriving at a final diagnosis

- In most cases, patients must have an appropriate clinical presentation and course
- Histologic findings should demonstrate many, if not all, of the established criteria
- In cases with some uncertainty, confirming the T cell nature (often with loss of surface antigens) can increase certainty
- Given a high index of suspicion, a positive gene rearrangement results in a high likelihood of a correct diagnosis

## Diagnostic possibilities

- Atypical lymphoid infiltrate
- Suggestive of mycosis fungoides
- Strongly suggestive of mycosis fungoides
- Consistent with mycosis fungoides
- Mycosis fungoides