

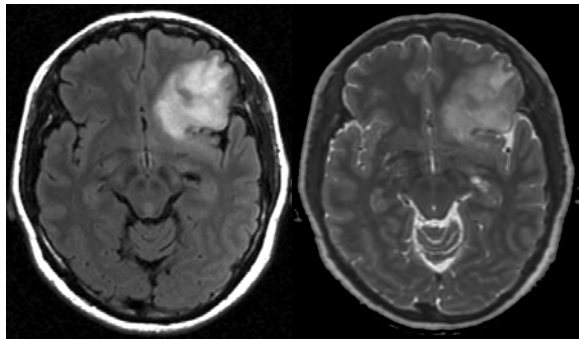
CASE
51 year old female with a frontal mass

Tarik Tihan, MD, PhD (UCSF)

Presentation

- 51-year-old woman admitted for a fine needle aspiration of a cystic thyroid mass.
- Developed a low grade, persistent headache, readmitted for evaluation.
- Radiological studies demonstrated a left frontal mass.
- Past medical history: Thyroid nodules (cystic), cesarean section, iron deficiency anemia

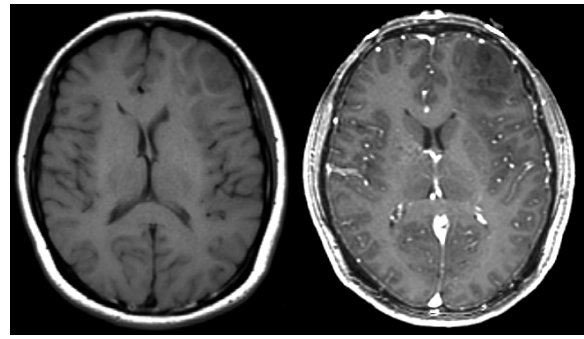
Radiographical Evaluation= Pre-op MRI



AXIAL FLAIR

AXIAL T2

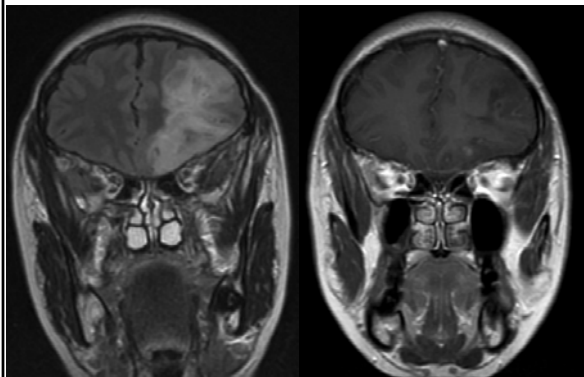
Radiographical Evaluation= Pre-op MRI



AXIAL T1

AXIAL T1-Contrast

Radiographical Evaluation= Pre-op Coronal MRI



Radiographical Evaluation=Pre-op MR Perfusion

