



MESONAT
 Registre Multicentrique
 à l'occasion Nationale
 du Mésothéliome

Specialty conference, USCAP San Diego
 Pulmonary Pathology
 Sunday march 25, 2007
Case n°3
 Françoise Galateau-Salle^{1,2,3},
 Centre Hospitalier Universitaire Caen, France
 ERI 3 INSERM¹
 MESONAT Registry²
 MESOPATH Group³





Clinical summary

- A 59-year-old white man, a storekeeper in a car factory from 1965 to 2000.
- Was hospitalized for a bilateral pleural effusion
- And a 3 months history of increasing dyspnea, cough, and fatigue.
- He also complained of fever, drenching night sweats and progressive body weight loss (8kg).
- At the time of admission asbestos exposure has ceased 5 years earlier.

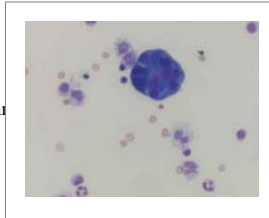
Clinical summary

- The patient had a previous history of:
 - systemic hypertension treated by hydrochlorothiazide
 - and Parkinson's disease diagnosed and treated by Celance® (pergolide) since 1998 1mg daily.
- The CT Scan confirmed bilateral pleural effusions
 - Diffuse bilateral pleural thickening
 - Rounded atelectasis



Laboratory data


- Normal WBC count with
 - 21% lymphocytes
 - Proteins:73g/L
 - C reactive protein:138mg/L
 - Sedimentation rate [ESR]:107mm
 - LDH:652
- Thoracentesis disclosed
 - lymphocytic and bloody fluid
 - Protein 39g/L
 - Normal Adenosine desaminase activity
 - No evidence of malignancy on cytology



Histopathologic findings

Representative slide is from the pleurectomy


- The pleural thickening ranged from 0.1 to 0.3 cm, and the pleura was white and firm



Histopathologic findings

H&E stained sections of the pleura showed:

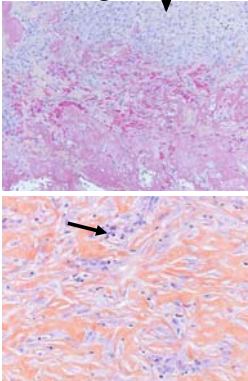
- severe diffuse thickened and fibrotic pleura
- With serofibrinous exudate at the surface
- And diffuse cellularity with fibrosis and inflammatory cells.



→ surface

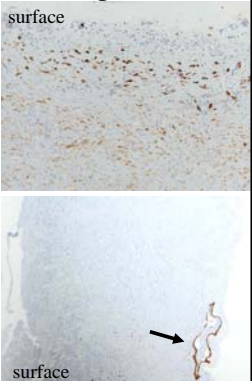
Histopathologic findings ↓

- At higher magnification
 - acute fibrinous pleuritis
- Cellularity was greater beneath the pleural surface
- Some plump, atypical fibroblasts were deeply seated with few mitosis



Histopathologic findings

- At higher magnification
 - Ipx with AE1/3 showed positive cells under effusion
 - the spindle cells deeply seated within the areas of fibrosis were also positive and parallel the surface mesothelium.
 - Sequestration of mesothelial cells (↓)



Panelists' Diagnoses Case 3

- Organizing fibrous pleuritis ? drug induced
- Acute fibrinous and chronic fibrous pleuritis, favor drug-induced injury
- Reactive pleural fibrosis ? Drug reaction
- Reactive pleural fibrosis ? Drug related

Diagnosis

Pergolide-induced fibrous pleuritis
in a patient with asbestos exposure

Discussion

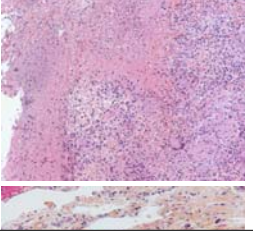
- The differential diagnosis included
 - Infection (tuberculosis)
 - Malignancy
 - Any other causes of recurrent exudative pleuritis
 - Benign asbestos related pleural effusion/fibrosis
 - Drug reactions

Infection /Tuberculosis

Clinical manifestations were suspicious for tuberculosis

- In tuberculosis, effusions are usually unilateral and massive
- associated with post-primary tuberculosis involving the apices of the upper lobes
- pleural fluid profile shows:
 - lymphocytic effusion,

- The diagnosis was excluded in view of:
 - the absence of necrotizing granulomas on serial recuts
 - negative findings with multiple cultures



Discussion

- The differential diagnosis included
 - Infection (tuberculosis)
 - Malignancy
 - Any other causes of recurrent exudative pleuritis
 - Benign asbestos related pleural effusion/fibrosis
 - Drug reactions

Discussion

Churg et al, Am J Surg Pathol, 2000; 24:1183-1200
Cagle and Churg, Arch Pathol Lab Med, 2005, 129:1421-7

Churg et al, covered the diagnostic criteria for the separation of benign from malignant mesothelial proliferations

Benign mesothelial reactions


- Zonation (higher cellularity under effusion)
- No true invasion of the parietal fat
- Storiform pattern absent or minimal
- Cytologic atypia beneath the surface
- Elongated capillaries perpendicular to the surface
- Mitoses may be present
- Necrosis usually absent

Desmoplastic mesothelioma

- No zonation (cellularity away from effusion)
- True invasion of the parietal fat
- Storiform pattern usually present
- Cytologic atypia present or absent in any area
- Capillaries haphazardly distributed and inconspicuous
- Many mesotheliomas show few mitoses
- Bland necrosis

Discussion

- Fibrous pleuritis
- Desmoplastic mesothelioma

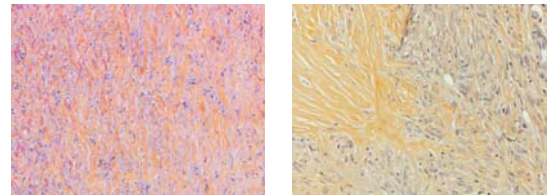


- Zonation (higher cellularity under effusion)
- Storiform pattern absent or minimal
- Absence of bland necrosis

- No zonation (cellularity away from effusion)
- Storiform pattern present
- Bland necrosis

Discussion

- Fibrous pleuritis
- Desmoplastic mesothelioma

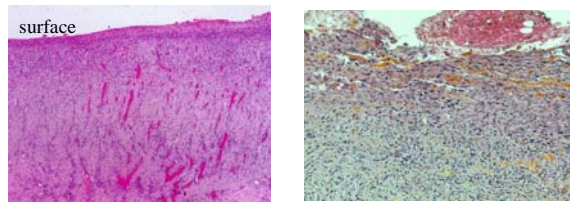


Spindle cells are oriented parallel to the surface mesothelium

Abrupt and haphazard transition in cellularity is one of the most useful clues favoring malignancy

Discussion

- Fibrous pleuritis
- Desmoplastic mesothelioma

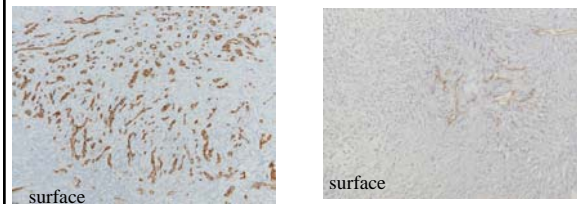


• Elongated capillaries perpendicular to the surface.

• Capillaries haphazardly distributed and inconspicuous.

Discussion

- Fibrous pleuritis
- Desmoplastic mesothelioma



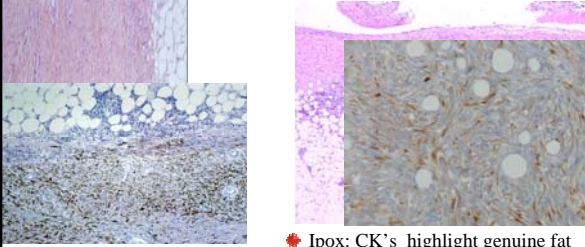
• Elongated capillaries perpendicular to the surface

• Capillaries haphazardly distributed and inconspicuous.

Discussion

Cagle et al, Hum Pathol, 1994
Mayall et al, J Pathol, 1992
Cury et al, J Pathol, 1999

- Fibrous pleuritis
- Desmoplastic mesothelioma



- Ipx: CK's , p53 and EMA may be positive
- Ipx: CK's highlight genuine fat invasion, p53 and EMA usually positive but not diagnostic

Discussion

- The differential diagnosis included
 - Infection (tuberculosis)
 - Malignancy
 - Any other causes of recurrent exudative pleuritis
 - Benign asbestos related pleural effusion/fibrosis
 - Drug reactions

Causes of pleural fibrosis

- Diffuse visceral and parietal fibrosis
 - Recurrent exudative effusion
 - Asbestos exposure
 - Collagen-vascular disease
 - Drug reactions
- Fibrothorax
- Pleural fibrosis secondary to renal disease
- Pleural fibrosis secondary to infections
- Pleural fibrosis secondary to trauma
- Pleural fibrosis secondary to asbestos


Discussion

- The differential diagnosis included
 - Infection (tuberculosis)
 - Malignancy
 - Any other causes of recurrent exudative pleuritis
 - Benign asbestos related pleural effusion/fibrosis
 - Drug reactions

Benign asbestos related pleural lesions

Churg et al, in Occupational Disorders of the Lung. Saunders

- Asbestos may cause acute pleurisy (5%)
- may recur on the same side or more commonly on the contralateral side after interval of months or years.
- Risk increase with the dose of asbestos
- Diffuse pleural fibrosis
 - This disorder usually involves the visceral pleura (parietal).
- Is believed to follow benign asbestos effusion
- Diffuse pleural fibrosis is usually unilateral but may be bilateral



Discussion

- The differential diagnosis included
 - Infection (tuberculosis)
 - Malignancy
 - Any other causes of recurrent exudative pleuritis
 - Benign asbestos related pleural effusion/fibrosis
 - Drug reactions

Drug induced pleural disease

- Drug-associated pleural effusion, pleuritis, and /or pleural thickening is an uncommon event compared to drug-induced parenchymal lung disease.
- Often misdiagnosed
- Drug effects are believed to be causal:
 - When exposure induces pleural disease
 - When the pleural response remits on discontinuation of the drug
 - And when the pleural disease recurs with re-exposure to the same drug

Drug induced pleural disease

- The first description of pleural adverse effects was made by Cooper et al, in 1986
- Drug induced pleural disease in [PUBMED](#)- 1176 -references

Drug induced pleural fibrosis

adapted from Morlock et al, Chest 1999

- | | |
|---|--|
| <ul style="list-style-type: none"> • Cardiovascular agents <ul style="list-style-type: none"> • Amiodarone • Minoxidil • Practolol • Ergoline drugs <ul style="list-style-type: none"> • Bromocriptine • Methysergide • Pergolide • Sclerotherapeutic agents • Drug induced lupus-like pleuritis <ul style="list-style-type: none"> • Procainamide • Hydralazine • Other drugs • Pleural fluid eosinophilia <ul style="list-style-type: none"> • Nitrofurantoin • Dantrolene • Valproic acid • Propylthiouracil | <ul style="list-style-type: none"> • Chemotherapeutic agents <ul style="list-style-type: none"> • Bleomycin • Mitomycin • Procarbazine • Methotrexate • Cyclophosphamide • Other agents <ul style="list-style-type: none"> • Acyclovir • Clozapine • D-penicillamine • Granulocyte stimulating factor • Interleukin-2 • Itraconazole • L-Tryptophan • Simvastin |
|---|--|

Pathogenic mechanisms

- Hypersensitivity or allergic reactions
- Direct toxic effect
- Increased free radical production
- Suppression of anti-oxidant defenses
- Chemical-induced inflammation

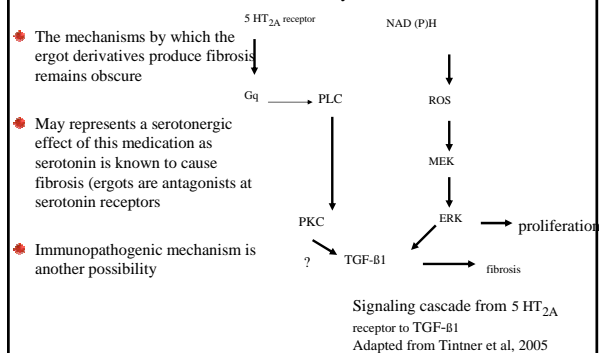
Pergolide

McElvaney et al, Arch Intern Med, 1988
 Danoff et al, Chest 2001
 Huggins et al, Clin Chest Med, 2004
 Hillerdal et al, Eur Respir J, 1997
 Knoop et al, Eur Respir J, 1997
 Brooks, JNNP, 2000
 Tintner et al, Archiv Neurol, 2005

- Pergolide is an ergot-derived dopamine agonist used in:
 - Parkinson's disease
 - Restless legs syndrome
- Has been reported to cause pleuro-peritoneal and retroperitoneal fibrosis.

Pergolide

Tintner et al, Arch Neurol, 2005
 Grewal et al, Am J Physiol, 1999



Pergolide induced pleural reaction

- A pergolide –induced fibrous pleuritis should be considered in a patient presenting with :
 - Bilateral pleural disease
 - Frequently associated with a systemic illness including fever, weight loss, and acute inflammatory syndrome
- Pergolide-induced pleural fibrosis usually occurs within 3 years of initiation of treatment.
- Is probably enhanced by asbestos exposure.

Conclusion

- A thorough work up to determine the cause (s) of pleural effusion in a patient taking pergolide is not only of academic or medico-legal interest but also of practical therapeutic importance to prevent at the early stage fibrosing complications.
- It is recommended not to use ergot-derivatives such as pergolide in Parkinson's disease in patients exposed to asbestos.
- Nowadays, the association of asbestos and Pergolide- induced pleural fibrosis does not seem fortuitous

Philippe Camus, and the GEPPi of the Department of Pulmonary Diseases and Intensive Care Unit. University Hospital, Dijon - FRANCE: www.pneumotox.com