

Microsatellite Instability Testing in Colon Cancer: The Role of the Pathologist

USCAP 2007 Annual Meeting

Companion Meeting: Association for Molecular Pathology

Antonia R. Sepulveda M.D., Ph.D.

Associate Professor of Pathology, University of Pittsburgh

The goals of this lecture are:

- 1: Introduction to microsatellite instability (MSI) testing in colorectal cancer (CRC), test interpretation, review the criteria for MSI testing in CRC and the role of the pathologist in requesting MSI tests
- 2: Discuss the use of integrated diagnostic/molecular pathology reports: reporting MSI test results and DNA mismatch repair protein immunohistochemistry (IHC) in CRC
- 3: Discuss the clinical applications of MSI testing:
 - a) Widely accepted clinical indication: To help identify patients who might have HNPCC
 - b) Possible indications in the future: To select patients for specific chemotherapy (such as 5FU) and to assess prognosis.

Microsatellite Instability Testing in CRC and Interpretation

Microsatellite instability is a type of mutation that occurs in short DNA segments known as microsatellite regions. Mutations that occur in the microsatellite repeats result in increased size (by addition of nucleotides) or reduced size (by loss of nucleotides) in the repeat. These changes in size of the microsatellite repeat are known as microsatellite instability.

Microsatellite instability occurs because of deficient/loss of DNA mismatch repair (MMR), which requires the function of several DNA mismatch repair proteins (hMLH1, hMSH2, hMSH6, hPMS2, hMSH3 and hMLH3) (reviewed in ¹). Loss of expression of these proteins in tumors can be detected by IHC performed on paraffin sections. **Microsatellite instability is the hallmark mutation in cancers of patients with hereditary non-polyposis colorectal cancer (HNPCC) and is currently used in clinical practice primarily to help identify patients who might have HNPCC.** Patients with HNPCC almost always show high levels of MSI in their CRC tissue. However, we need to be aware that approximately 15% sporadic colorectal cancers and other sporadic adenocarcinomas of the spectrum of HNPCC cancers can have MSI-positive status ². Therefore, confirmation of HNPCC requires identification of germline mutations (detected in peripheral blood DNA) in one of the DNA mismatch repair genes (reviewed in ¹), whereas somatic hypermethylation of the hMLH1 promoter leading to loss of hMLH1 expression is the underlying abnormality causing MSI in sporadic tumor tissues ³.

For the MSI test DNA is extracted from unstained sections from formalin fixed and paraffin embedded tissue specimens. PCR amplification is performed with sets of primers that amplify five microsatellite markers (BAT25, BAT26, D2S123, D5S346 and D17S250), known as the NCI panel ⁴. Using the NCI five microsatellite marker panel, tumors can be classified as: 1) **MSI-High level (MSI-H)** when MSI is detected in at least two of the five markers (30% or greater markers positive for MSI); 2) **MSI-Low (MSI-L)** if MSI is detected at only one marker (less than 30% of the markers positive for MSI); 3) **Microsatellite stable (MSS)** if none of the five markers shows MSI.

Alternative panels of microsatellite markers have been proposed and may be used in clinical practice, based on local laboratory preference⁵. If a tumor is MSI-H the patient might have HNPCC, and it is important that the MSI test report states that there are potential genetic implications of the test results and genetic counseling should be recommended. If a patient has an MSI-positive tumor, most specifically MSI-H, together with a detailed family history of cancer, germline mutations are required to confirm a diagnosis of HNPCC, and consent by the patient for testing is necessary for germline mutation testing (but not for MSI testing). If HNPCC is ruled out, MSI-H identifies a sub-group of sporadic adenocarcinomas that have distinct clinical pathological features namely better survival and resistance to 5-fluorouracil (5FU). Germline mutations of DNA MMR genes in HNPCC affect hMLH1 (approximately 40%), hMSH2 (approximately 40%), hMSH6 (approximately 10%), and PMS2 (approximately 5%) (reviewed in¹). In HNPCC, the specific MMR genes affected by germline mutation show loss of expression by IHC in the tumor tissue.

If no loss of expression of hMSH2 or hMLH1 is seen in MSI-H tumors by IHC or if the tumor is MSI-L or MSS but there is clinical suspicion of HNPCC, evaluation of other MMR genes, in particular hMSH6 and hPMS2 may be performed, by immunohistochemical stains and/or germline mutational analyses^{6,7}.

Correlation of MSI Test Results and DNA Mismatch Repair Protein IHC

The DNA mismatch repair proteins are normally present in the cell nucleus, therefore loss of nuclear expression is the pattern observed in MSI-H tumors. Most laboratories routinely testing for DNA mismatch repair proteins currently offer IHC for the 3 main repair proteins (hMLH1, hMSH2 and hMSH6). Interpretation of IHC when the 3 stains are done in the same tumor usually permits the successful identification of the DNA mismatch repair gene that underlies microsatellite instability. Note that when hMLH1 expression is lost hPMS2 is also lost because hPMS2 requires hMLH1 for stability through heterodimerization; in contrast, if hPMS2 is lost hMLH1 expression is preserved because hMLH1 also forms heterodimers with other proteins, thus being protected from degradation. Similarly, when hMSH2 expression is lost, hMSH6 is also lost because hMSH6 requires hMSH2 for stabilization through heterodimerization; in contrast, if hMSH6 is lost hMSH2 expression is preserved because hMSH2 also forms heterodimers and is stabilized by other proteins. The usual patterns of immunoreactivity are summarized in the table below.

	IHC MLH1	IHC PMS2	IHC MSH2	IHC MSH6
MLH1 Mutation	Loss	Loss	Preserved	Preserved
MSH2 Mutation	Preserved	Preserved	Loss	Loss
MSH6 Mutation	Preserved	Preserved	Preserved	Loss
PMS2 Mutation	Preserved	Loss	Preserved	Preserved

Clinical Indications for Microsatellite Instability Testing in Colorectal Cancer

The MSI test is currently used primarily to help identify patients who might have HNPCC. The most recent guidelines to help decide whether a patient should undergo molecular testing to rule out HNPCC, known as the revised Bethesda criteria^{7, 8}, are as follows:

- 1) **Patient is diagnosed with colorectal cancer before the age of 50 years.**
- 2) **Presence of synchronous or metachronous colorectal or other HNPCC related tumors** (stomach, urinary bladder, ureter and renal pelvis, biliary tract, brain (glioblastoma), sebaceous gland adenomas, keratoacanthomas and small bowel), regardless of age.
- 3) **Colorectal cancers with a high-microsatellite instability morphology** (Tumor infiltrating lymphocytes, Crohn's-like lymphocytic reaction, mucinous or signet-ring cell differentiation, poorly differentiated carcinomas with medullary growth pattern), diagnosed before the age of 60 years.
- 4) Colorectal cancer with one or more first degree relatives with colorectal cancer or other HNPCC-related tumors. One of the cancers must have been diagnosed before the age of 50 years (including adenomas, which must have been diagnosed before the age of 40 years).
- 5) Colorectal cancer with two or more relatives with colorectal cancer or other HNPCC-related tumors, regardless of age.

As can be seen from the above criteria, the pathologist can easily identify patients with criteria 1 and 2, and criterium 3 specifically depends on the identification by the pathologist of tumors that demonstrate MSI-suggestive histology. Using criterium 3 alone, in patients between 50 and 60 years of age we identified MSI-High in 57% of CRC tested⁹. In various Centers MSI reflex testing is requested by the pathologist in the cases identified by the pathologist as fulfilling one of the above criteria, and the results of the MSI test are then integrated with the surgical pathology report. While some Centers perform IHC for the main DNA mismatch repair proteins (hMLH1, hMSH2, and hMSH6) along with the MSI test, reporting the IHC results in the same final pathology report along with the MSI test results, others perform IHC and MSI tests sequentially, only in tumors that are found to be MSI-High, depending on local preference.

MSI and Prediction of Tumor Prognosis and of Response to Chemotherapy

Several studies have reported unique clinicopathological features of tumors related to their MSI status, namely a relationship with response to chemotherapy (5-FU) and an improved prognosis in tumors that are MSI-H.

Chemotherapy of stage II and III CRC with 5-fluorouracil did not improve survival if the tumor was MSI-High. In contrast, patients with microsatellite stable tumors treated with 5-FU had better survival compared with patients who were not treated. Therefore, treatment selection for colorectal cancer may be optimized by combining molecular testing of the tumor for MSI in addition to clinicopathological stage^{10, 11}.

Studies have shown that MSI-H colorectal cancers show less lymph node metastases burden and have better survival^{1, 12}. The relationship between MSI and improved prognosis was independent of stage, site, tumor grade, and age and was associated with a 60% decrease in death attributable to colon cancer¹². Other recent studies support these data¹³.

The application of MSI testing of colorectal cancers with the purpose of evaluating prognosis and selection of treatment is not currently part of routine practice but may receive support in the near future, as more studies continue to confirm the findings reported in the past few years.

REFERENCES

1. Gologan A, Sepulveda AR. Microsatellite instability and DNA mismatch repair deficiency testing in hereditary and sporadic gastrointestinal cancers. *Clin Lab Med* 2005;25:179-96.
2. Liu B, Nicolaides C, Markowitz S, Willson JKV, Parsons RE, Jen J, Papadopolous N, Peltomaki P, Chapelle A, Hamilton S, Kinzler KW, Vogelstein B. Mismatch repair defects in sporadic colorectal cancers with microsatellite instability. *Nature Genetics* 1995;9:48-55.
3. Herman JG, Umar A, Polyak K, Graff JR, Ahuja N, Issa JP, Markowitz S, Willson JK, Hamilton SR, Kinzler KW, Kane MF, Kolodner RD, Vogelstein B, Kunkel TA, Baylin SB. Incidence and functional consequences of hMLH1 promoter hypermethylation in colorectal carcinoma. *Proc Natl Acad Sci U S A* 1998;95:6870-5.
4. Boland CR, Thibodeau SN, Hamilton SR, Sidransky D, Eshleman JR, Burt RW, Meltzer SJ, Rodriguez-Bigas MA, Fodde R, Ranzani GN, Srivastava S. A National Cancer Institute Workshop on Microsatellite Instability for cancer detection and familial predisposition: development of international criteria for the determination of microsatellite instability in colorectal cancer. *Cancer Res* 1998;58:5248-57.
5. Murphy KM, Zhang S, Geiger T, Hafez MJ, Bacher J, Berg KD, Eshleman JR. Comparison of the microsatellite instability analysis system and the Bethesda panel for the determination of microsatellite instability in colorectal cancers. *J Mol Diagn* 2006;8:305-11.
6. Akiyama Y, Sato H, Yamada T, Nagasaki H, Tsuchiya A, Abe R, Yuasa Y. Germ-line mutation of the hMSH6/GTBP gene in an atypical hereditary nonpolyposis colorectal cancer kindred. *Cancer Res* 1997;57:3920-3.
7. Umar A, Boland CR, Terdiman JP, Syngal S, de la Chapelle A, Ruschoff J, Fishel R, Lindor NM, Burgart LJ, Hamelin R, Hamilton SR, Hiatt RA, Jass J, Lindblom A, Lynch HT, Peltomaki P, Ramsey SD, Rodriguez-Bigas MA, Vasen HF, Hawk ET, Barrett JC, Freedman AN, Srivastava S. Revised Bethesda Guidelines for hereditary nonpolyposis colorectal cancer (Lynch syndrome) and microsatellite instability. *J Natl Cancer Inst* 2004;96:261-8.
8. Syngal S, Fox EA, Eng C, Kolodner RD, Garber JE. Sensitivity and specificity of clinical criteria for hereditary non-polyposis colorectal cancer associated mutations in MSH2 and MLH1. *J Med Genet* 2000;37:641-5.
9. Gologan A, Krasinskas A, Hunt J, Thull DL, Farkas L, Sepulveda AR. Performance of the revised Bethesda guidelines for identification of colorectal carcinomas with a high level of microsatellite instability. *Arch Pathol Lab Med* 2005;129:1390-7.
10. Carethers JM, Smith EJ, Behling CA, Nguyen L, Tajima A, Doctolero RT, Cabrera BL, Goel A, Arnold CA, Miyai K, Boland CR. Use of 5-fluorouracil and survival in patients with microsatellite-unstable colorectal cancer. *Gastroenterology* 2004;126:394-401.
11. Warusavitarne J, Schnitzler M. The role of chemotherapy in microsatellite unstable (MSI-H) colorectal cancer. *Int J Colorectal Dis* 2006.
12. Samowitz WS, Curtin K, Ma KN, Schaffer D, Coleman LW, Leppert M, Slattery ML. Microsatellite instability in sporadic colon cancer is associated with an improved prognosis at the population level. *Cancer Epidemiol Biomarkers Prev* 2001;10:917-23.
13. Sinicrope FA, Rego RL, Halling KC, Foster N, Sargent DJ, La Plant B, French AJ, Laurie JA, Goldberg RM, Thibodeau SN, Witzig TE. Prognostic impact of microsatellite

instability and DNA ploidy in human colon carcinoma patients. *Gastroenterology* 2006;131:729-37.

Microsatellite Instability Testing in Colon Cancer: The Role of the Pathologist

**Antonia R. Sepulveda M.D., Ph.D.
University of Pittsburgh**

2007 USCAP Annual Meeting

- Introduction to microsatellite instability (MSI)
- MSI test for colorectal cancer (CRC) and test interpretation
- Review the criteria for MSI testing in CRC and the role of the pathologist in requesting MSI tests and reporting test results
- Discuss the use of integrated diagnostic/molecular pathology reports:
 - reporting MSI test results and DNA mismatch repair protein immunohistochemistry (IHC) in CRC

Microsatellite Instability

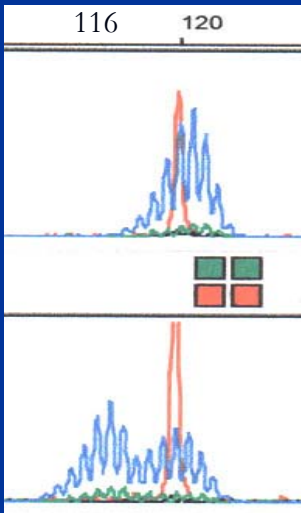
122 base pairs



AGCCCGG AAA AAAA CTAAACCC

AGCCCGG AAA AAAA CTAAACCC

116 base pairs



DNA Mismatch Repair (MMR) Proteins

- MutS: MSH2, MSH6, MSH3
- MutL: MLH1, PMS2, MLH3

MMR proteins function as heterodimers
The heterodimers are required for protein stability

MutS

MSH2-MSH6

MSH2-MSH3

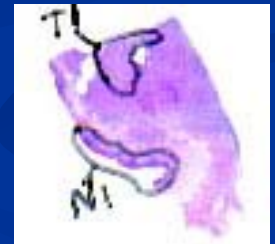MutL

MLH1-PMS2

MLH1-MLH3

TESTING MSI IN TUMORS PROTOCOL

- Unstained sections from formalin fixed paraffin embedded tissue
- Scrape selected areas for DNA extraction
- PCR amplification with MSI panel
- DNA fragment characterization by electrophoresis



MSI TEST PANEL OF MICROSATELLITE MARKERS

- NCI 5 microsatellite marker panel
 - Mononucleotide repeat: BAT 25 and BAT 26
 - Dinucleotide repeat: D2S123, D5S346 and D17S250

MSI SUB-TYPES

- High level MSI (MSI-H)
 - MSI in $\geq 30\%$ of markers tested (at least 2 markers out of five)
- Low level MSI (MSI-L)
 - MSI in $<30\%$ of markers tested (only 1 MSI-positive marker)
- Microsatellite stable (MSS)
 - No markers show MSI

CLINICAL IMPLICATIONS OF MSI-H

- MSI-H might indicate that the patient has HNPCC.
Family history/genetic testing required to rule-out this possibility.
- If HNPCC is ruled out:
 - MSI-H in sporadic carcinoma
 - Associated with loss of MLH1 in tumor cells by IHC
 - Associated with MLH1 promoter CpG hypermethylation

CLINICAL IMPLICATIONS OF MSI-H

- MSI-H sporadic tumors are associated with improved survival.
- Nodal involvement is less prevalent in MSI-positive tumors.
- Tumors with microsatellite instability may show increased resistance to chemotherapeutic agents.

Hereditary non-polyposis colorectal cancer (HNPCC)

- >90% germline mutations in **MLH1** and **MSH2** MMR genes with loss of protein in cancer tissue
- Few cases are associated with **MSH6**, **PMS2**, and rare **MSH3** mutation
- >90% CRC with MMR protein loss show MSI-H in cancer tissues, but there are exceptions
 - Cases of DNA repair protein loss by IHC (eg. **MSH6**) that are MSI-L or MSS
- Almost all MSI-H CRC show loss of main DNA repair proteins, but there are exceptions
 - Cases with DNA repair protein mutations without loss by IHC (but tumor is MSI-H)

Revised Bethesda Guidelines for HNPCC and MSI Testing

Umar, A. et al. JNCI 96: 261-268, 2004

PATHOLOGIST!

1-CRC diagnosed in a patient less than 50 years of age.

2-CRC with MSI-H histology diagnosed in a patient less than 60 years of age.

REGARDLESS OF AGE OF PATIENT :

3-Synchronous, metachronous CRC, or other HNPCC-associated tumors.

4-Individual with CRC and at least one first degree relative with CRC/HNPCC tumor less than 50 years of age.

5-Patient with CRC and two or more first- or second-degree relatives with CRC/HNPCC-related tumors.

Comparison Between Initial vs. Revised Bethesda Guidelines for HNPCC Testing

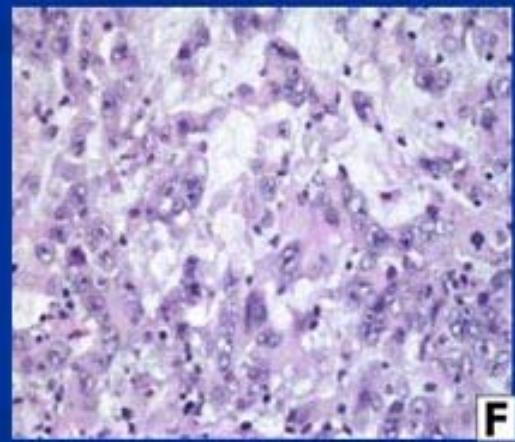
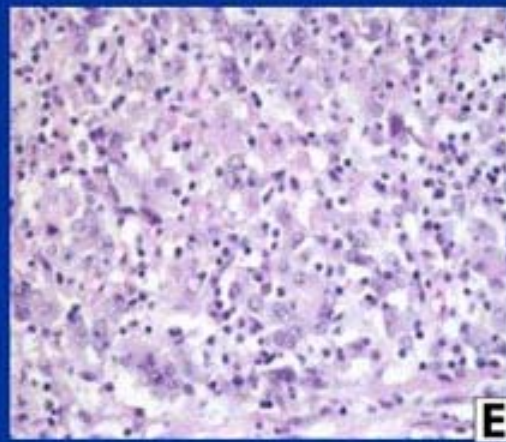
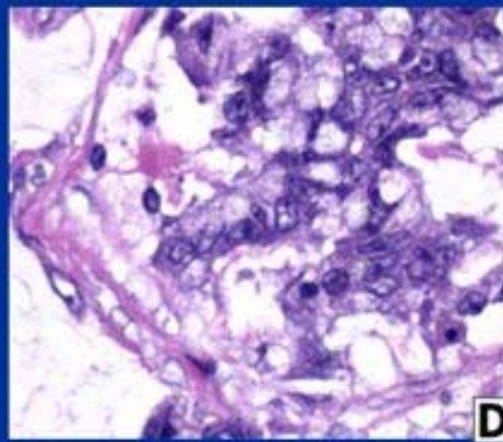
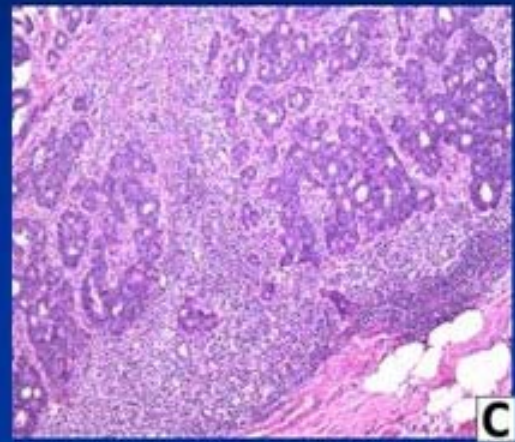
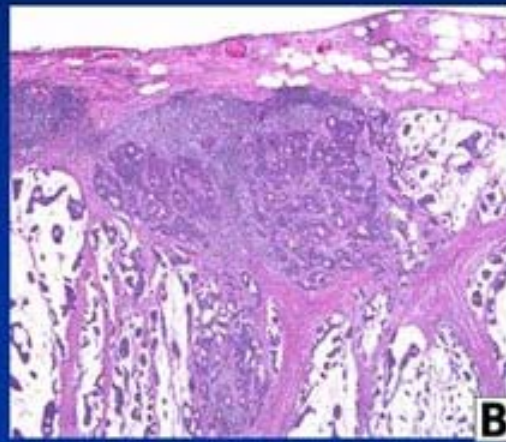
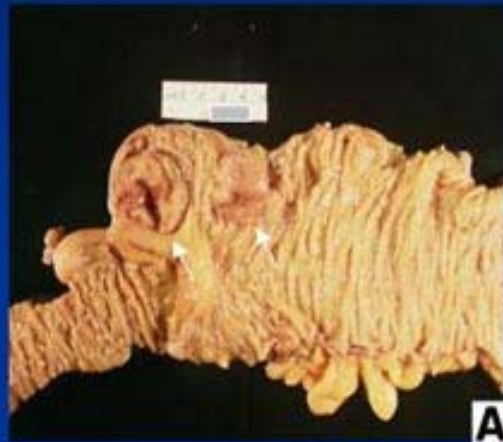Number of cases: 75	Bethesda	Revised Bethesda
MSI-H	8	17
MSS	37	58

- More MSS cases were identified
- The revised guidelines identified 9 additional MSI-H cases.

HNPPC Related Tumors

- Colorectal
- Small bowel
- Stomach
- biliary tract
- pancreas
- sebaceous gland adenomas and keratoacanthomas in Muir–Torre syndrome
- Endometrial
- ovarian
- Bladder, ureter and renal pelvis
- brain (usually glioblastoma as seen in Turcot syndrome)

Gross and Morphologic Features of MSI-H CRC

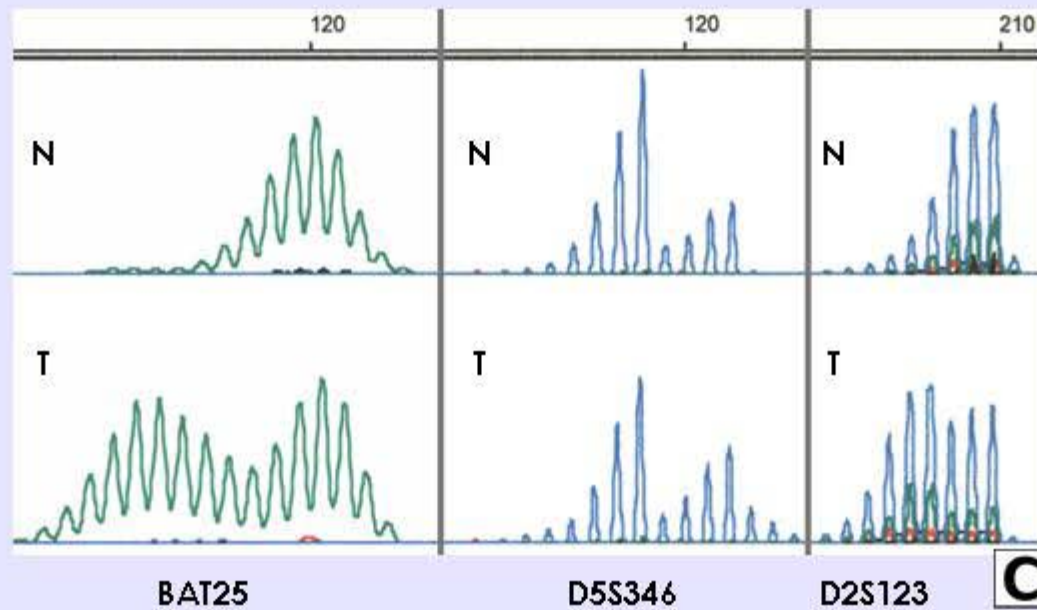
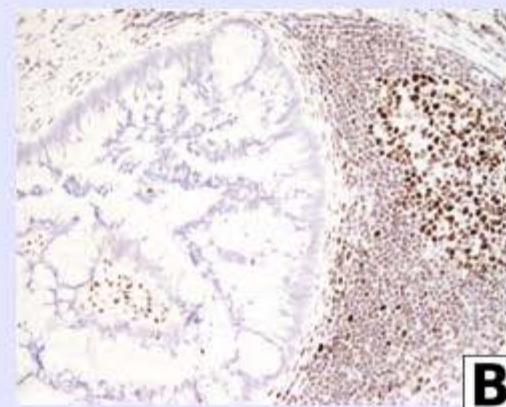
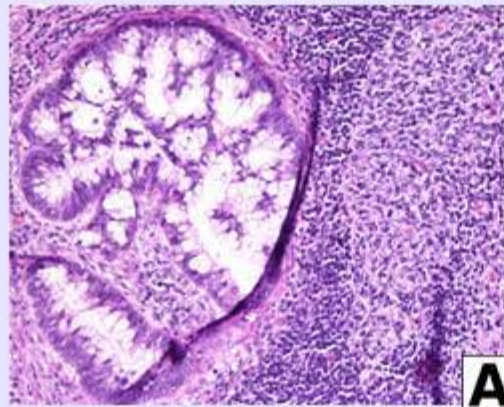


Gologan & Sepulveda et al.
Arch Pathol Lab Med 2005; 129: 1390-1397

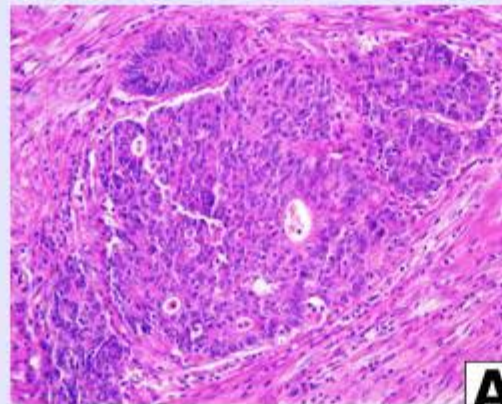
Microsatellite Instability Test Report

- High-level microsatellite instability detected (MSI-H).
- Low-Level microsatellite instability detected (MSI-L).
- No microsatellite instability detected (MSS).
- Immunohistochemistry for MLH1, MSH2 and MSH6 showed preserved /or loss of expression of...DNA repair proteins.

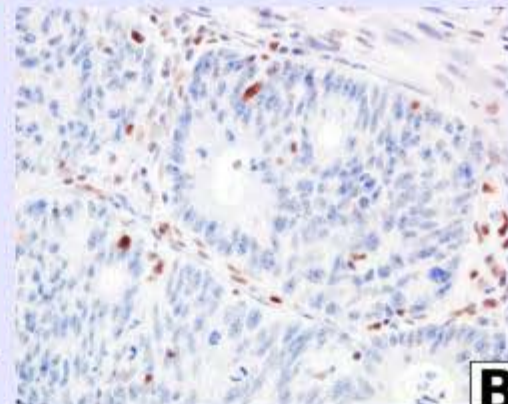
MSI-H COLORECTAL CARCINOMA hMSH2-Negative



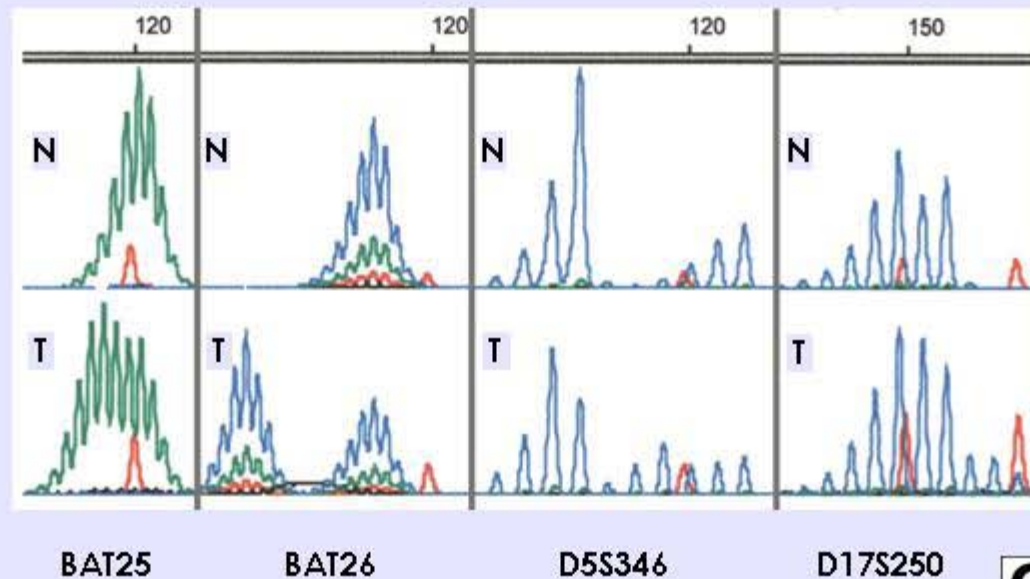
MSI-H COLORECTAL CARCINOMA hMLH1-Negative



A



B



C

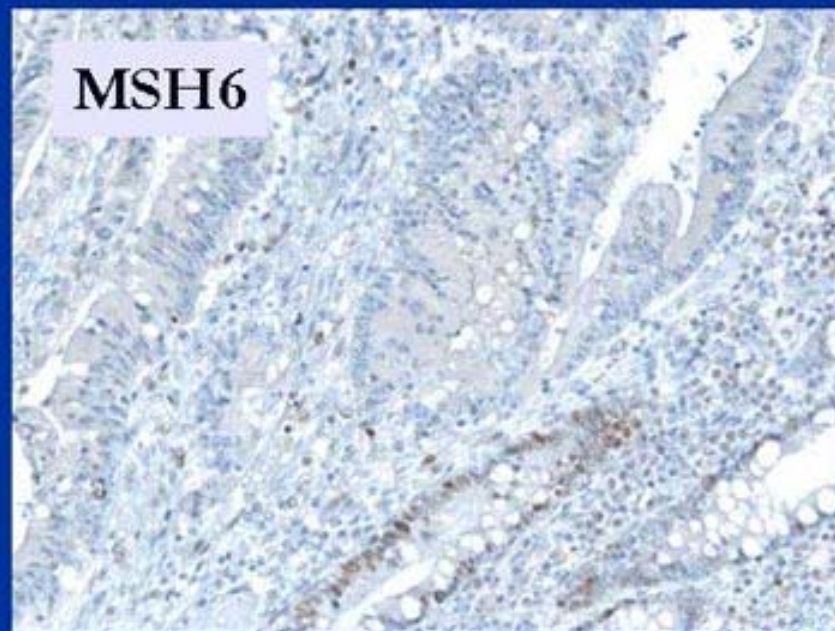
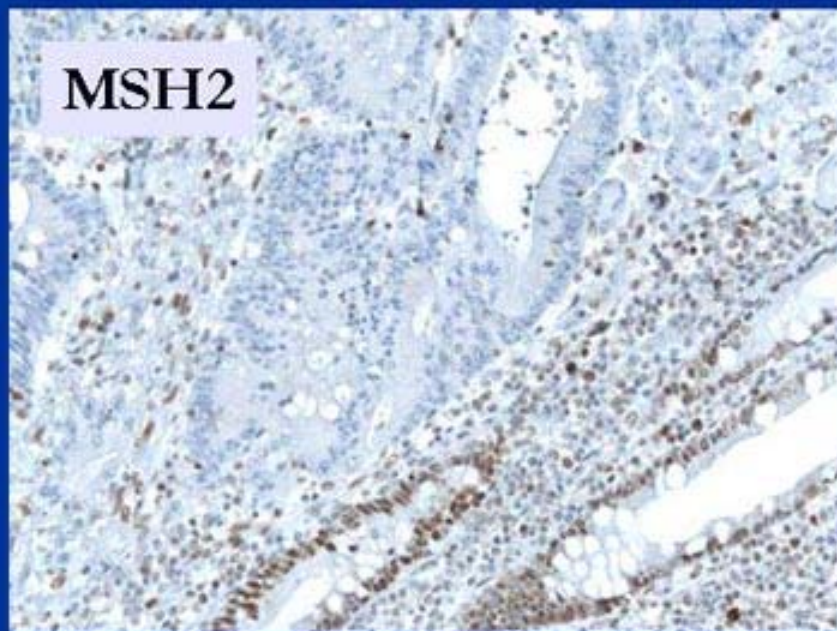
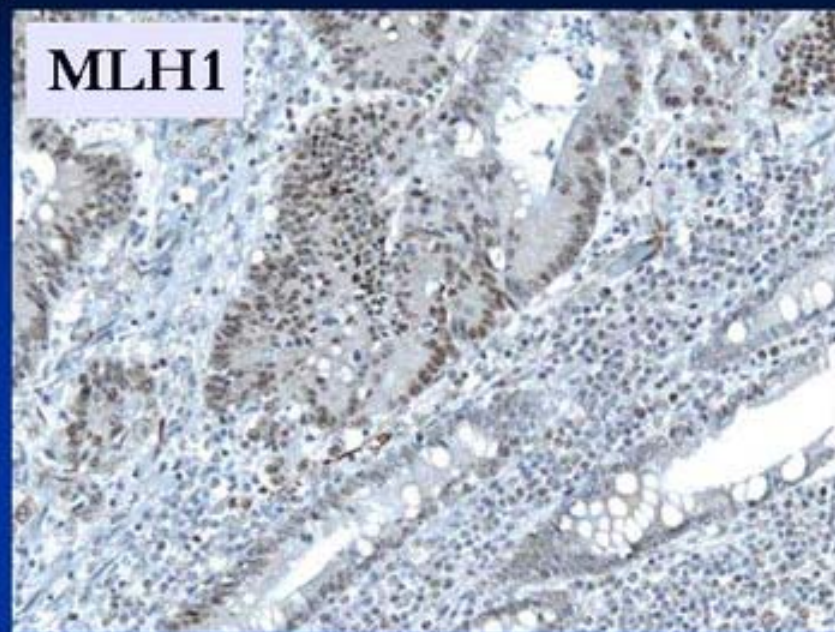
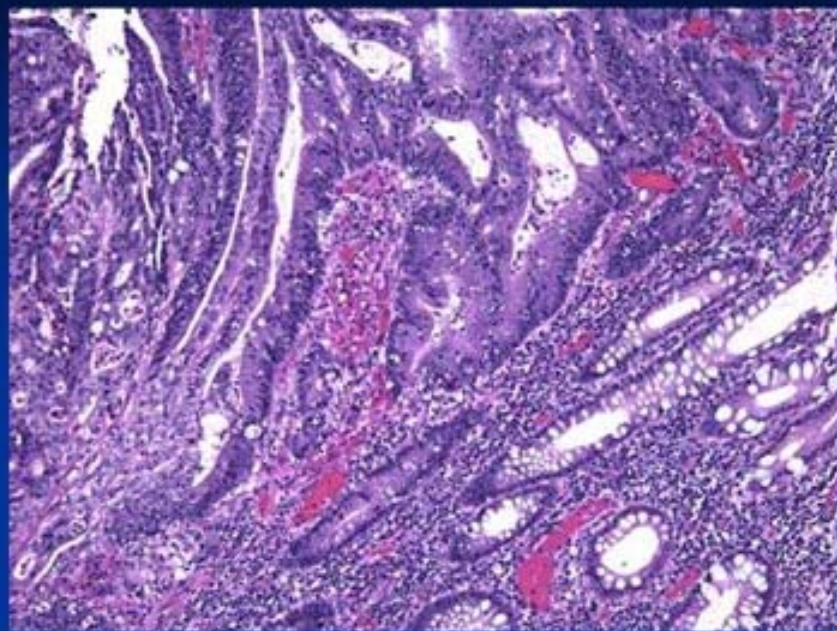
Immunohistochemical Patterns in MSI-H CRC

	IHC MLH1	IHC PMS2	IHC MSH2	IHC MSH6
MLH1 Mutation	Loss	Loss	Preserved	Preserved
MSH2 Mutation	Preserved	Preserved	Loss	Loss
MSH6 Mutation	Preserved	Preserved	Preserved	Loss
PMS2 Mutation	Preserved	Loss	Preserved	Preserved

Integrated Pathology Report: Example Case

- 45 year old man
- Transverse colon obstructing mass
- Right hemicolectomy: 10 cm exophytic mass (T3N0MX)
- MSI and IHC for MLH1, MSH2 and MSH6 performed-reflex test by pathologist

Morphology and IHC



Microsatellite Instability Test Report

- High-level microsatellite instability detected (MSI-H).
- Immunohistochemistry for MLH1, MSH2 and MSH6 showed loss of expression of MSH2 and MSH6 in tumor cell nuclei.
- Note: MSH2 is most likely to represent the underlying primary genetic defect in this MSI-H tumor.

CONCLUSIONS

- Microsatellite instability testing of CRC is currently indicated to help identify patients with HNPCC
- Pathologists can play a significant role in identifying patients for MSI test using the Bethesda guidelines
 - -Reflex testing-
- Important to establish a protocol for handling CRC specimens that may have MSI test performed in consensus with the local team of GI, Oncologists and Surgeons, and to have available genetic counseling
- Combined vs. sequential or alternative MSI and IHC for DNA repair proteins depends on local preferences