

# **New Developments in the Endoscopic Diagnosis and Management of Barrett's Esophagus**

Prateek Sharma, MD

## **Key Clinical Management Points:**

- Endoscopic recognition of a columnar lined distal esophagus is crucial to ensure an accurate diagnosis of Barrett's esophagus
- Treatment is currently aimed at controlling symptoms of GERD and does not appear to have a major impact on dysplasia or cancer risk
- Chemoprevention trials have been initiated in patients with Barrett's esophagus
- Endoscopic therapies benefit a sub group of patients with high grade dysplasia and early adenocarcinoma

# **New Developments in the Endoscopic Diagnosis and Management of Barrett's Esophagus**

Prateek Sharma, MD  
Associate Professor of Medicine  
University of Kansas School of Medicine  
VA Medical Center  
Kansas City, USA

## **Introduction**

Barrett's Esophagus (BE) is a metaplastic change in the esophagus that results in replacement of the normal squamous lined epithelium with intestinal metaplasia. The incidence of esophageal adenocarcinoma has rapidly increased in recent years and BE has been found to be present as a precursor lesion in many of these cases. Patient's with BE are thought to have an annual risk of developing esophageal cancer of 0.5% per year, substantially higher than the general population, but the absolute risk of developing cancer in BE patients is low.

## **Diagnosis of BE**

The definition of BE has evolved over time. BE was recently defined during a workshop sponsored by the American Gastroenterological Association in February 2003 (BE Chicago Workshop) as, "a displacement of the squamocolumnar junction proximal to the gastroesophageal junction with the presence of intestinal metaplasia." Endoscopic assessment of the extent of Barrett's esophagus (endoscopically visible esophageal columnar mucosa) is dependent on correctly locating esophageal landmarks such as the gastroesophageal junction (GEJ). Lack of simple, standardized criteria for identifying these landmarks and reliably measuring the extent of Barrett's esophagus has hindered consistency in research and clinical practice.

## **The Prague C and M criteria**

In BE patients, the proximal level of the squamocolumnar junction (SCJ or Z-line) is such that it no longer coincides with the gastroesophageal junction (GEJ). The resulting columnar-lined mucosa of the distal esophagus appears salmon-pink in color, and is readily visible by endoscopic examination. Biopsies can then be obtained from this area of suspected BE (endoscopic BE) to further characterize the tissue and to specifically document intestinal metaplasia. Thus, reliable diagnosis of BE, with its associated risk for esophageal adenocarcinoma, depends firstly on the effective recognition of endoscopic features of the suspected BE segment, followed by technically adequate histological sampling of the metaplastic esophageal mucosa to screen for intestinal-type metaplasia. Apart from biopsy sampling, measurement of the extent of BE is also clinically relevant, since this influences the risk of developing adenocarcinoma. For instance, the Rotterdam Esophageal Tumour Study Group found that a doubling of the length of BE increased the risk of adenocarcinoma by 1.7 times.

Despite the importance of accurate endoscopic recognition and grading of BE, there is no consensus-based, authoritative guidance on how this should be done. Accordingly, a variety of ad hoc and frequently inadequately specified and validated approaches have been used. For instance, grading of patients into those with variably defined 'short' and 'long' segments of BE is an unsatisfactorily crude approach. An international Barrett's esophagus working group was convened to standardize the endoscopic measurement of Barrett's esophagus. The working group developed criteria to assess the circumferential and the maximal extent of esophageal columnar tissue, the Prague C and M criteria. Using these criteria, circumferential Barrett's esophagus extending to 3 cm above the GEJ with a tongue extending 5 cm above the GEJ would be described as C3M5, while a tongue extending 3 cm above the GEJ with no circumferential extent of Barrett's esophagus would be designated C0M3.

For the detection of dysplasia in patients with BE, four quadrant biopsies every 1-2 cm of the endoscopically recognized area of BE should be obtained. Given that these biopsies are random in nature and sample only a small surface area of the BE segment, a number of new techniques (i.e. magnification endoscopy, spectroscopy, optical coherence

tomography, etc.) are being evaluated to increase the yield of detecting dysplastic and cancerous tissue. Although these technologies are not yet ready for routine clinical use, they will dramatically change surveillance practices in BE patients in the future.

## **Treatment**

A reasonable initial step in treatment of BE is eliminating symptoms of reflux, and healing esophagitis. The importance of reflux control has been proposed by studies that demonstrate that acid reflux predisposes to proliferation, and some studies have even cited gastroesophageal reflux in the activation of protein kinase regulated pathways resulting in decreased apoptosis in cell lines exposed to acid. Although proton pump inhibitors can heal and treat GERD in patients with BE, acid suppression therapy has not yet clearly demonstrated a reduction in cancer risk. The option of surgery can be considered in some individuals with BE for the treatment of their underlying gastroesophageal reflux disease. Although studies in the surgical literature argue for histological regression in individuals after antireflux surgery, cases of high grade dysplasia and cancer have been reported even after these procedures. Most recently, a meta-analysis concluded that the risk of adenocarcinoma in individuals with BE was not significantly decreased by anti-reflux surgical procedures.

Endoscopic therapies for the treatment of BE are a more recent mode of therapy. Although the majority of the area of BE can be replaced by neo-squamous mucosa, persistent metaplastic tissue is often detected underlying the squamous tissue. Given the low risk of cancer in patients with non dysplastic BE or even with low grade dysplasia, endoscopic ablation treatments cannot be recommended outside of protocols in these patients. In patients with high grade dysplasia, however, the risk of progression to cancer can be as high as 25-37%. In these patients, aggressive surveillance, early surgical resection, or endoscopic ablation may be considered. Endoscopic therapies including mucosal resection and photodynamic ablation hold promise given the alternative - esophagectomy. However, long term data are lacking in this field and the number of patients treated with endoscopic therapies have also been small. The group of investigators from Germany are to be commended for reporting 5 year follow up data on Barrett's esophagus with high grade dysplasia and early carcinoma. Excellent complete

remission rates (86%) were observed over a follow-up time period of 5 years. The 5 year survival rate was 89% with an overall complication rate of 15%. Recurrences as well as metachronous lesions were observed in 20% of the patients indicating that close follow up after endoscopic treatment is still required in these patients. Similarly, results from a large multicenter randomized trial showed a significant decrease in cancer progression in HGD patients treated with photodynamic therapy (PDT). Such patients should probably be referred to high volume and expert endoscopy centers to minimize the morbidity associated with endoscopic resection and ablation.

### **Key Clinical Management Points:**

- Endoscopic recognition of a columnar lined distal esophagus is crucial to ensure an accurate diagnosis of Barrett's esophagus
- Treatment is currently aimed at controlling symptoms of GERD and does not appear to have a major impact on dysplasia or cancer risk
- Chemoprevention trials have been initiated in patients with Barrett's esophagus
- Endoscopic therapies benefit a sub group of patients with high grade dysplasia and early adenocarcinoma

### **Recommended Reading:**

- Sharma P, McQuaid K, Dent J, et al. A critical review of the diagnosis and management of Barrett's esophagus: the AGA Chicago Workshop. *Gastroenterology* 2004;127(1):310-30.
- Ell C, May A, Pech O, et al. Curative endoscopic resection of early esophageal adenocarcinomas (Barrett's cancer). *Gastrointest Endosc* 2007;65(1):3-10.
- Montgomery E, Bronner MP, Goldblum JR, et al. Reproducibility of the diagnosis of dysplasia in Barrett esophagus: a reaffirmation. *Hum Pathol* 2001;32(4):368-78.
- Sampliner RE; Practice Parameters Committee of the American College of Gastroenterology. Updated guidelines for the diagnosis, surveillance, and therapy of Barrett's esophagus. *Am J Gastroenterol* 2002;97(8):1888-95.

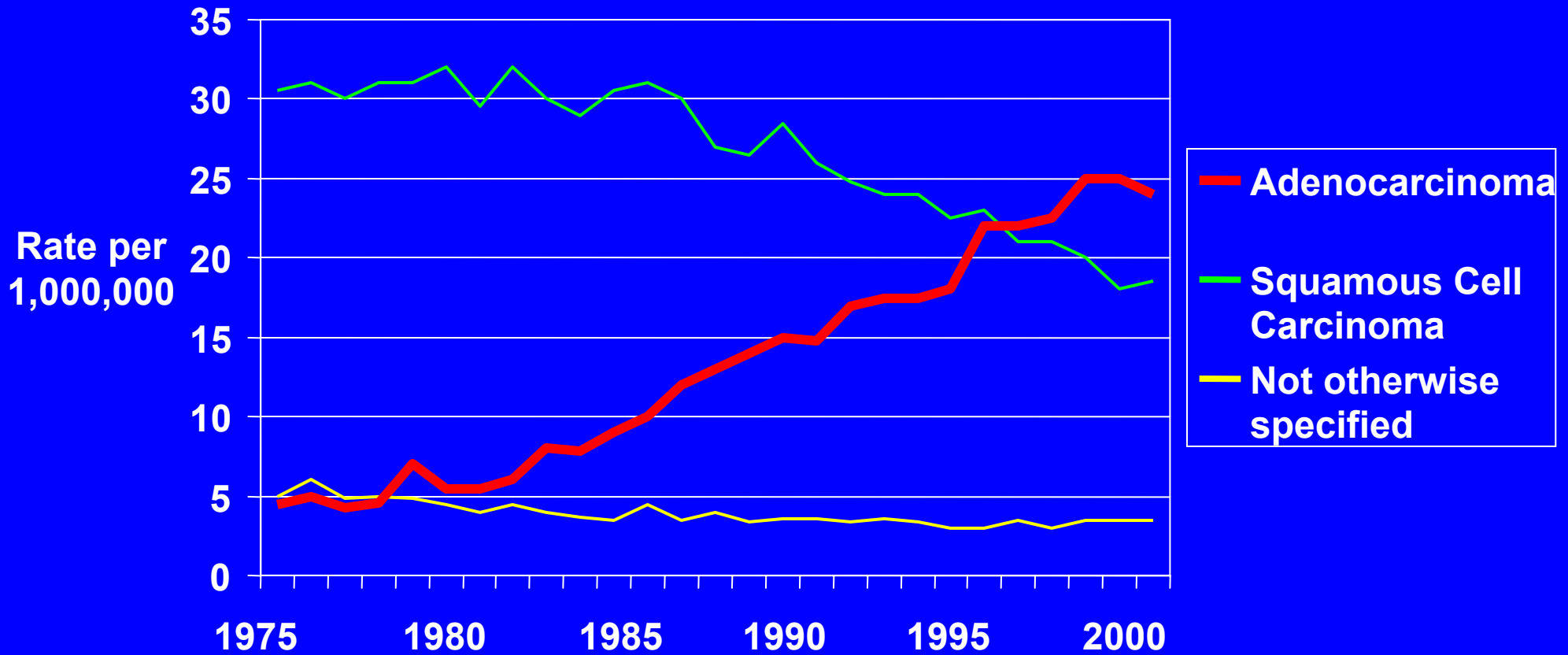
- Overholt BF, Lightdale CJ, Wang KK, et al. Photodynamic therapy with porfimer sodium for ablation of high-grade dysplasia in Barrett's esophagus: international, partially blinded, randomized phase III trial. *Gastrointest Endosc* 2005;62(4):488-98.
- Sharma P, Dent J, Armstrong D, et al. The development and validation of an endoscopic grading system for Barrett's esophagus: the Prague C & M criteria. *Gastroenterology* 2006;131(5):1392-9.

# **New Developments in the Endoscopic Diagnosis and Treatment of Barrett's Esophagus**

**Prateek Sharma, MD**

Kansas City

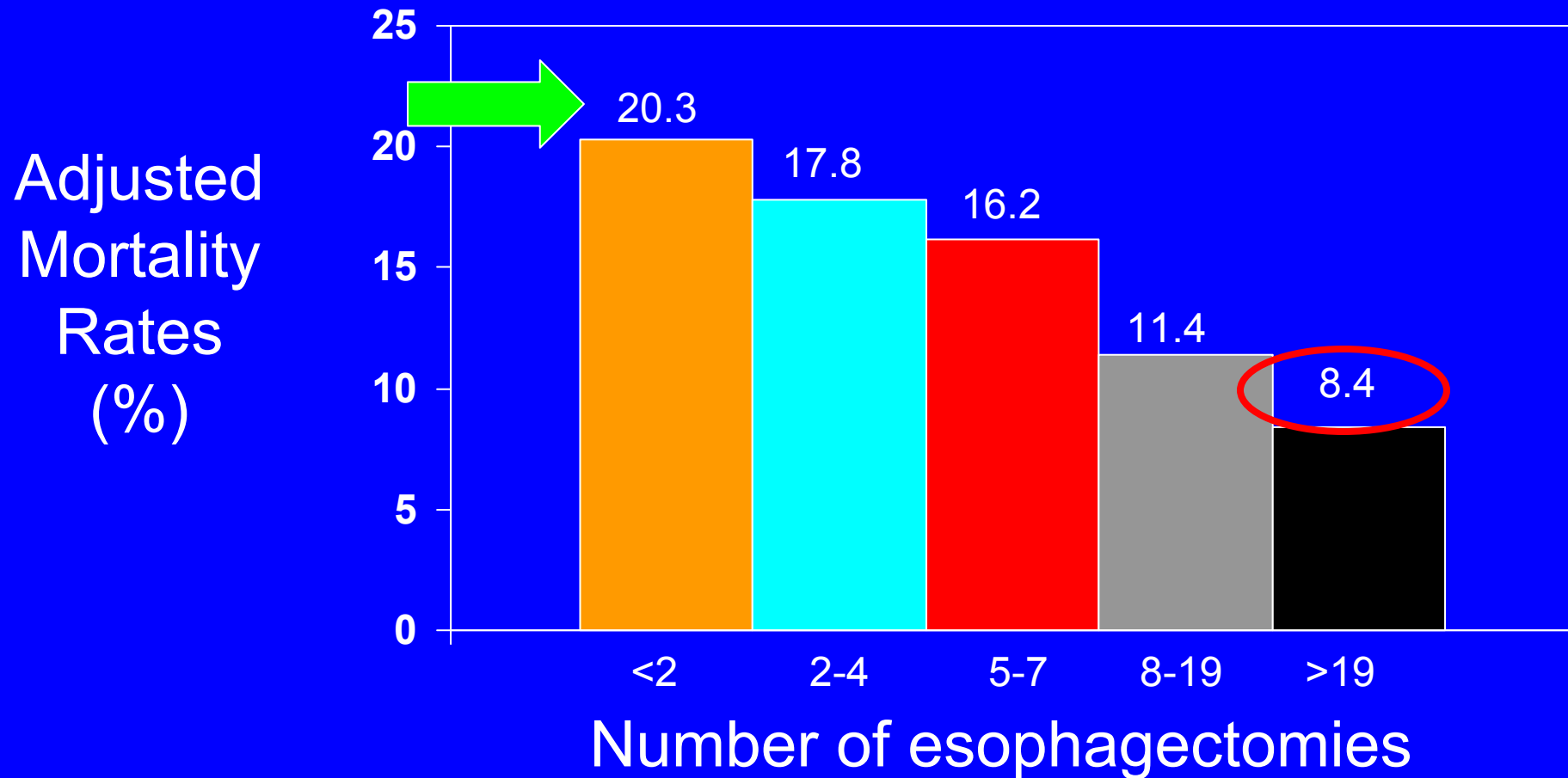
# Rising Incidence of Esophageal Adenocarcinoma



# Why have an Endoscopic classification system for Barrett's Esophagus?

- BE is common
- BE is associated with dysplasia and esophageal adenocarcinoma
- Terminology issues
- Recognition of endoscopic landmarks

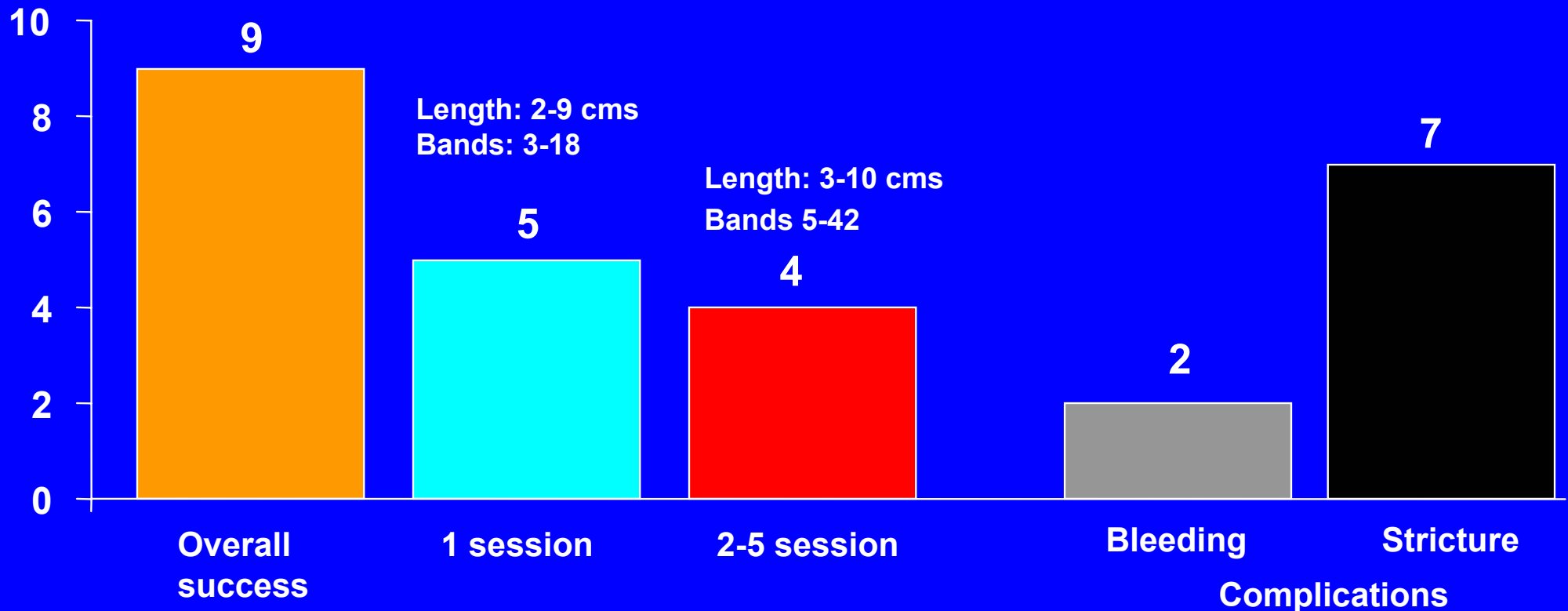
# Esophagectomy: High-Volume Hospitals Have Lower Mortality Rates



# Circumferential EMR for BE

10 patients (8 cancer, 2 HGD)

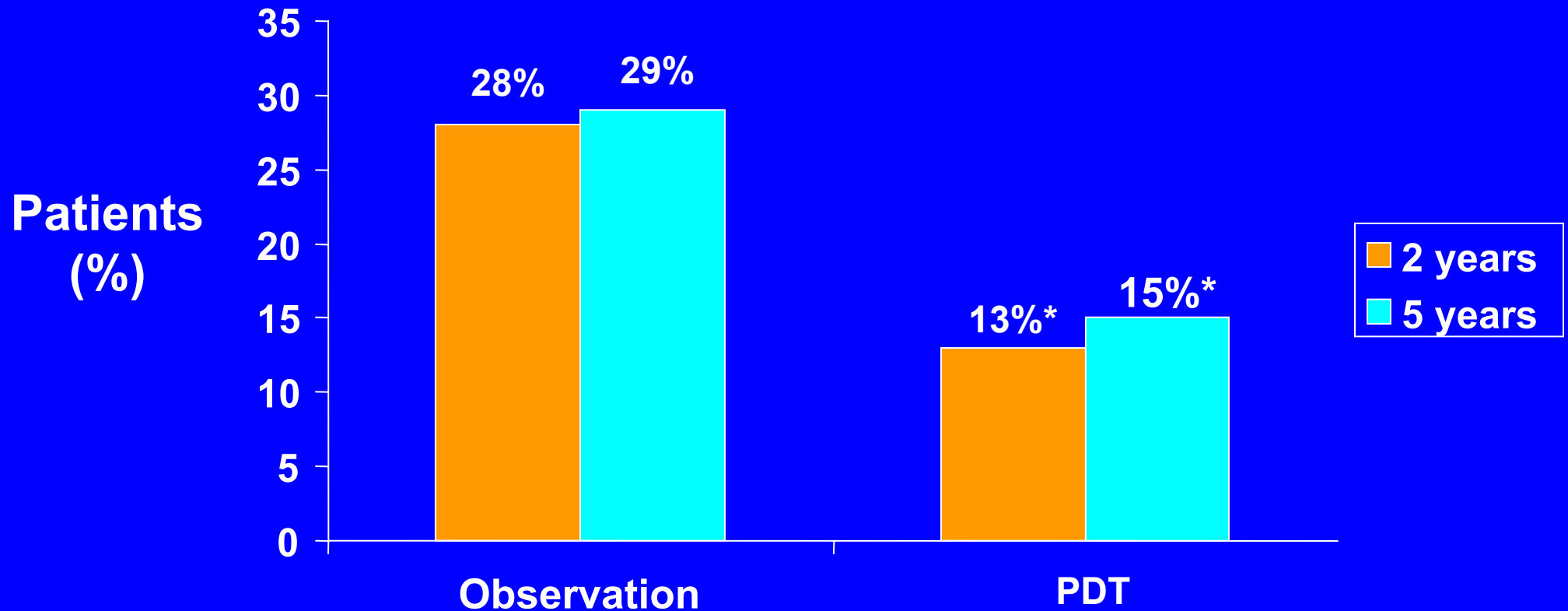
Median age: 62 years



# PDT: 5 Year Follow Up

- 208 HGD patients
- PDT (138), observation (70)

## Progression to cancer



\*p = 0.02

# Endoscopic Therapy: Limitations

- Strictures: EMR >75% circumference
- *En bloc* resection difficult: Margins +
- Non uniform light exposure
- Persistence of genetic abnormalities

# Conclusions: Endoscopic Diagnosis

- **Clear identification of endoscopic landmarks is the basis for an endoscopic diagnosis**
- **The reliability of using the Prague C&M criteria for the endoscopy grading of BE is excellent**
- **Endoscopic recognition of lengths of BE < 1cm have very low reliability**
- **The reliability for the endoscopic recognition of landmarks (eg. GEJ, hiatus) are excellent**

# Summary

## Endoscopic Treatment

- Endoscopic therapies appear very promising in the treatment of dysplasia and cancer of the esophagus
- The goal should be complete eradication of at risk mucosa
- Patient factors (age, extent of disease, comorbidities, multiple procedures) and endoscopist factors (expertise) should be taken into consideration