



Unusual Hematologic Tumors of the Genitourinary Organs

Lynne V. Abruzzo, M.D., Ph.D.
Department of Hematopathology
March 24, 2007

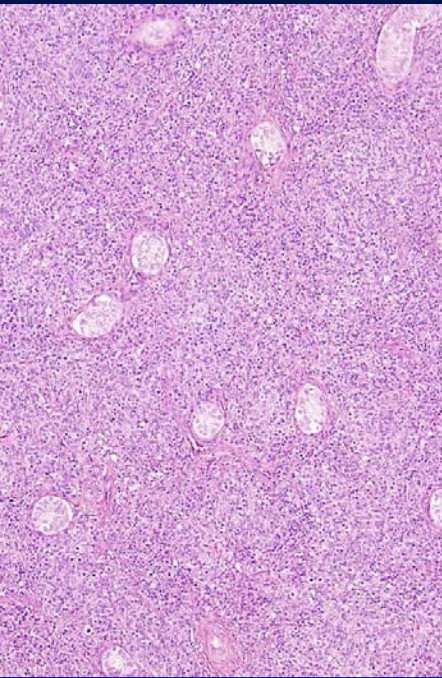
THE UNIVERSITY OF TEXAS
MD ANDERSON
CANCER CENTER
Making Cancer History[®]

Case 1

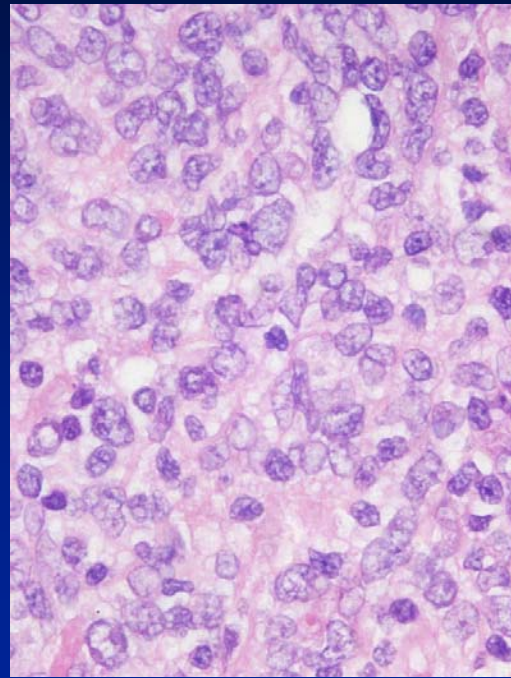
Case History

- The patient was a 6 year old boy who presented with painless enlargement of the right testis. He was otherwise well. Physical examination was remarkable only for the enlarged testis. Laboratory tests, including a complete blood count and serum chemistries, and a bone marrow examination were within normal limits. Ultrasound of the scrotum showed an enlarged right testis with a focal hypoechoic mass. Chest radiograph, CT scans of the chest and abdomen, and bone scan were unremarkable.
- The patient underwent a right radical orchiectomy and right inguinal lymph node biopsy.

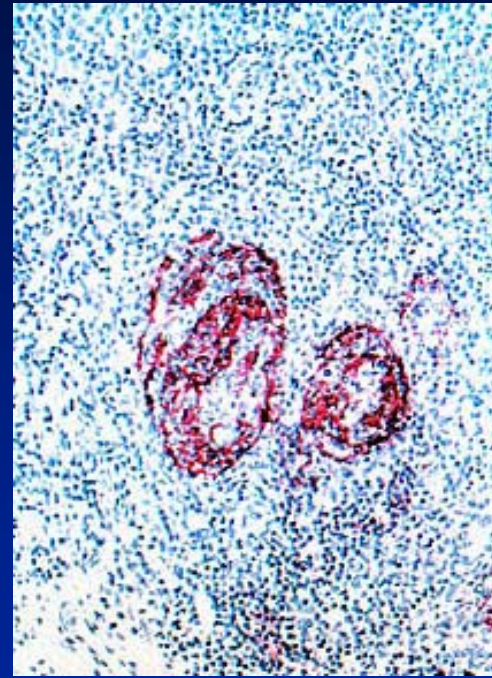
Histology and Immunophenotype



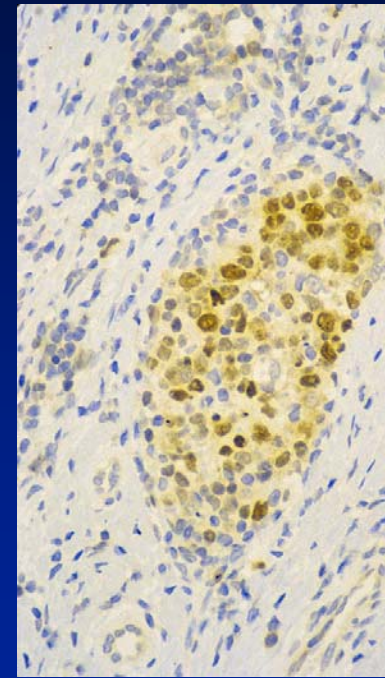
H&E x 40



H&E x 400



CD21 x 200



BCL6 x 200

Diagnosis

Primary follicular lymphoma of the testis in childhood

Lymphoma of the Testis

- Lymphoma can involve the testis as
 - Disseminated nodal disease
 - Primary site of presentation of clinically occult nodal disease
 - True primary extranodal disease
- Presents as a hard, painless, usually unilateral scrotal mass
- Disseminated nodal lymphoma - common in adults and children
 - Adults
 - Most common testicular neoplasm in men older than 60 years
 - Usually diffuse large B-cell lymphoma
 - Follicular lymphoma rare

Lymphoma of the Testis

- Disseminated nodal NHL
 - Children
 - Usually precursor B or T lymphoblastic leukemia/lymphoma or Burkitt lymphoma
- Primary testicular lymphoma - rare in adults and children
 - Adults
 - Usually diffuse large B-cell lymphoma
 - Aggressive clinical course with propensity to spread to nasopharynx and central nervous system
 - Children
 - Usually follicular large cell lymphoma
 - Excellent prognosis

Follicular Lymphoma

Comparison of Adults and Children

	Adults	Children
Occurrence	Common	Rare
Median age	59 years	11 years
M:F ratio	1:1.7	2.3:1
Stage	III/IV	I
Site	Widespread	Head and neck (esp. tonsil), testis
Grade	I/II	II/III
t(14;18)/BCL2	Positive	Negative
Course	Indolent, progressive	Usually curable

Follicular Lymphoma of Testis in Children

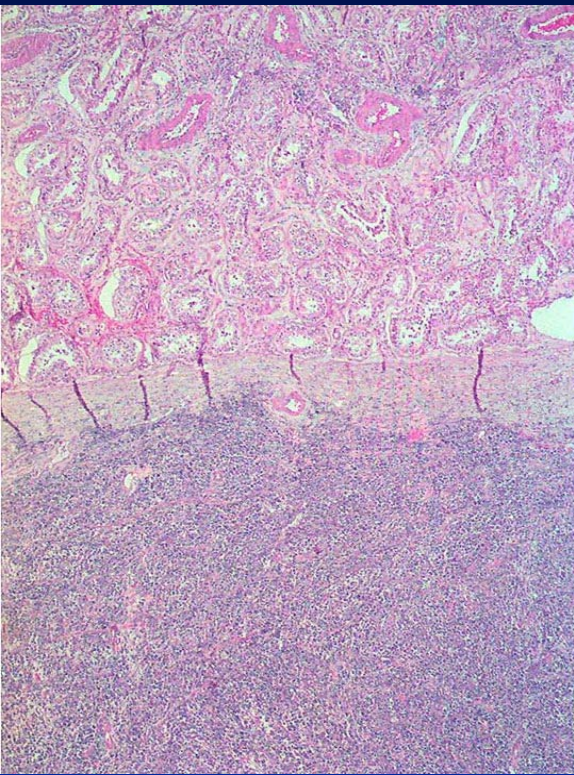
- Exceedingly rare
 - 11 reported cases
- Median age
 - 5 years (range 3-11 years)
- Stage IE
- Histology
 - Follicular, some cases with focal diffuse areas
 - Grade 3 (large cell) with no low-grade component
- Immunophenotype
 - CD20+ , CD10 (5/8+), BCL6 (9/10+), BCL2-
- Excellent prognosis
 - All in complete remission (median 10 months, range 7-59 months)

Case 2

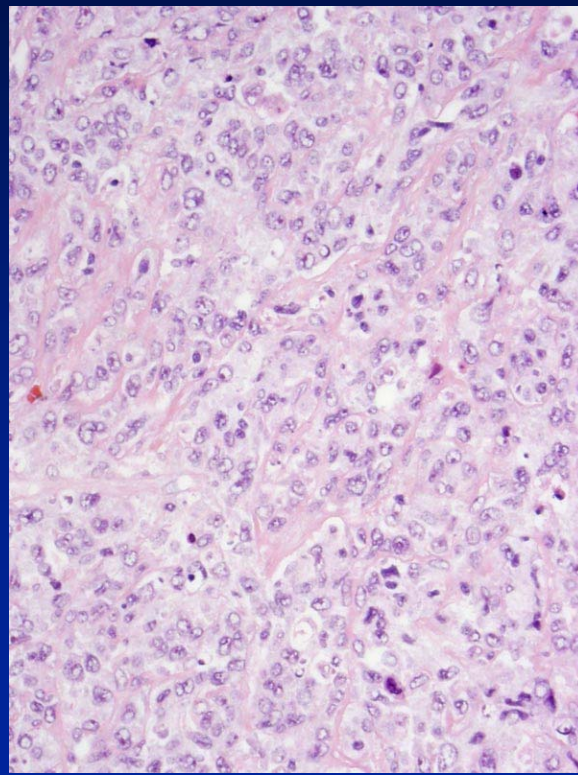
Case History

- The patient was a 35 year old man who presented with a painless 8 cm left scrotal mass that had been waxing and waning in size over the past 2 years. He was otherwise well. Physical examination was remarkable only for the mass. Laboratory tests, including a complete blood count and serum chemistries, and a bone marrow examination were within normal limits. Chest radiograph and CT scans of the chest and abdomen were unremarkable.
- The patient underwent a left orchiectomy.

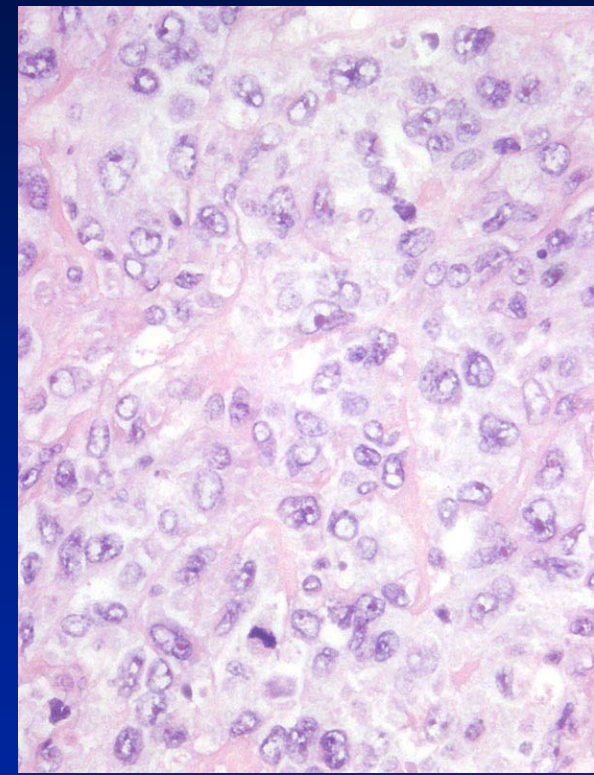
Histology



H&E x 40

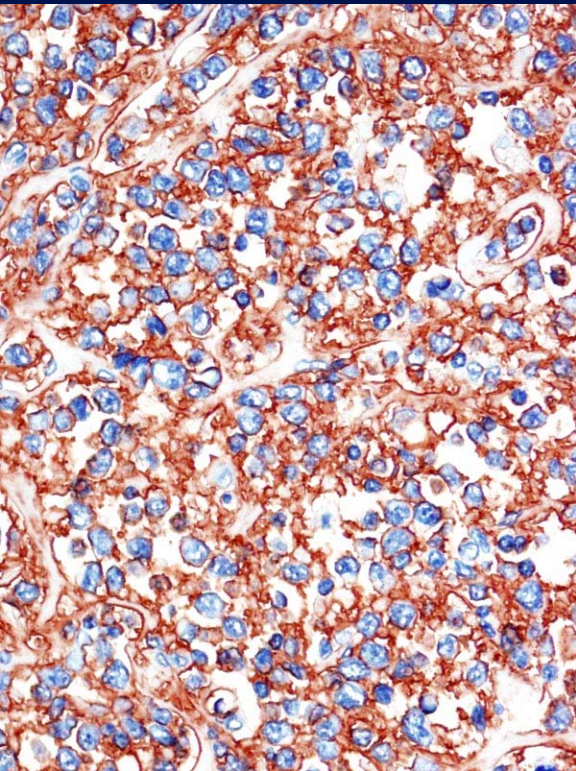


H&E x 200

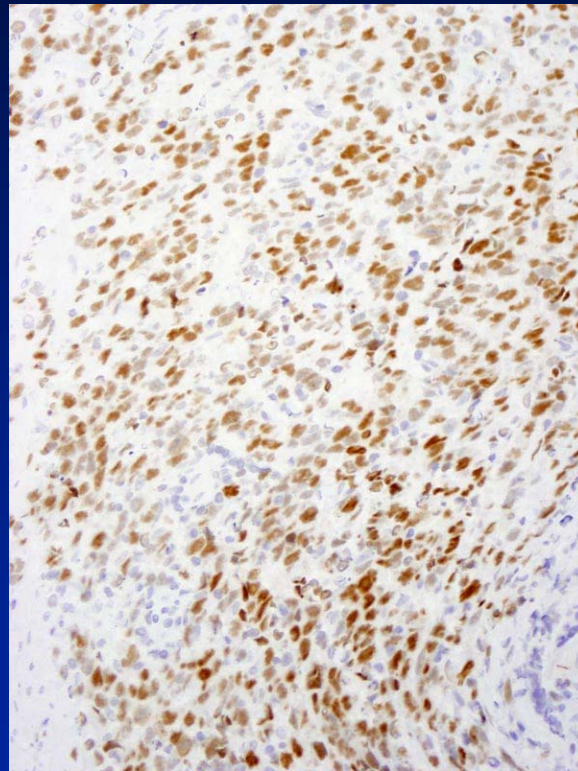


H&E x 400

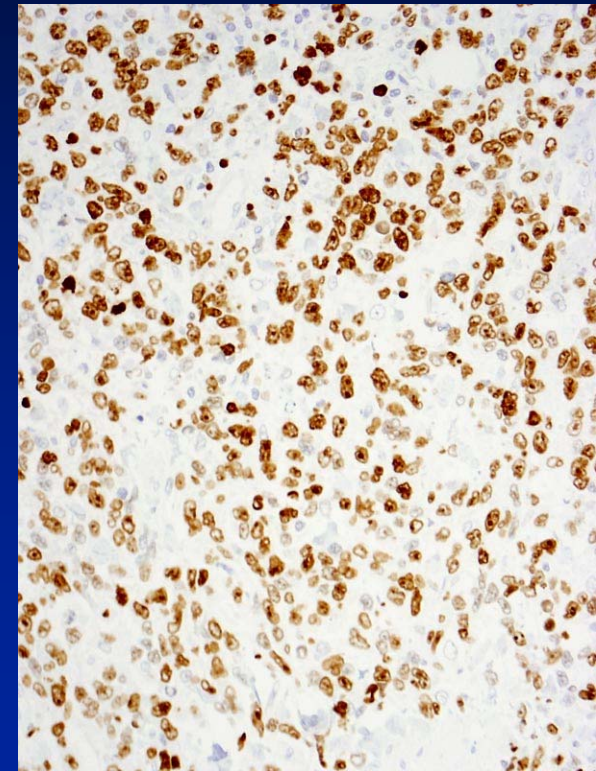
Immunophenotype



CD20 x 200



BCL6 x 200



Ki-67 x 200

Diagnosis

Primary diffuse large B-cell
lymphoma of the epididymis

Primary Lymphoma of the Epididymis

Clinical Features

Case	Age, y	Stage	Histology/ Immunophenotype	Therapy	Response	Follow-up, mos
1	35	IE	Diffuse large cell/B	O, CT, RT	CR	NED, 6
2	26	IE	"Histiocytic"/NA	O, RT	CR	NED, 12
3	73	IE	"Histiocytic"/NA	RT	CR	NED, 12
4	68	IE	Diffuse large cell/NA	O, CT	NR	DOD, 12
5	34	IE	Follicular lymphoma, grade 3/B	O, CT	CR	NED, 79
6	20	IE	MALT lymphoma/B	SR	CR	NED, 36
7	56	IE	Intravascular lymphoma/T	CT	NR	DOD, 11
8	25	IE	Diffuse large cell/NA	CT	CR	NED, 18

Primary Lymphoma of the Epididymis

Clinical Features

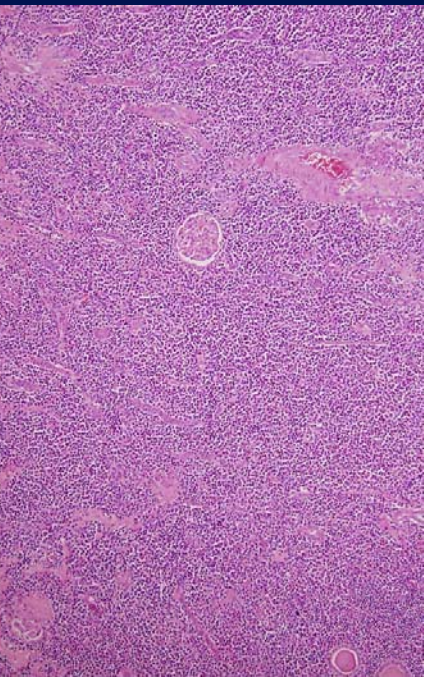
- Extremely rare
- Relatively young age
 - Range 20-73 years (median 34.5 years)
- Right side involved more often than left
 - 6 right, 1 left, 1 bilateral
- Low stage at presentation (IE)
- Intermediate to high-grade histology
- Difficult to determine behavior and survival due to small number of cases and short follow-up

Case 3

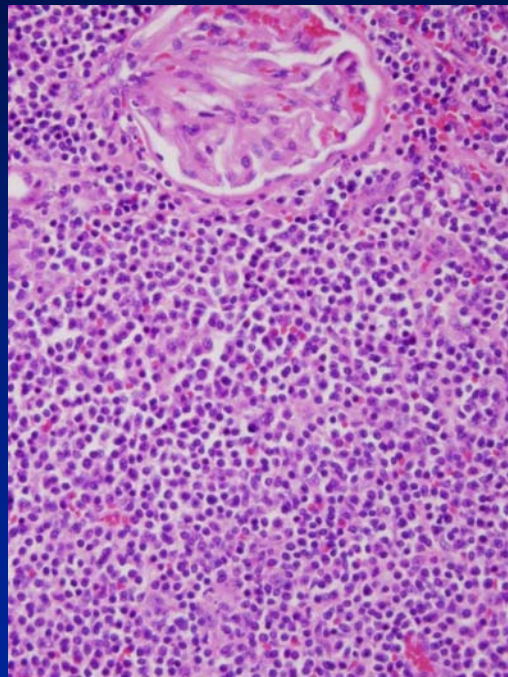
Case History

- The patient was a 76 year old woman who presented with right flank pain, anorexia, and weight loss for one month. Her past medical history was significant for essential hypertension, but she had been otherwise well. Physical examination was unremarkable. Laboratory tests, including a complete blood count and serum chemistries were remarkable only for an elevated serum creatinine of 127 $\mu\text{mol/L}$ (normal, 53-106 $\mu\text{mol/L}$). Urinalysis showed >30 leukocytes per high power field, but was negative for protein and glucose. Bone marrow examination was unremarkable. A CT scan of the abdomen showed a 5x3x3 cm mass in the anteroinferior aspect of the right kidney, with no evidence of lymphadenopathy.
- The patient underwent a right radical nephrectomy.

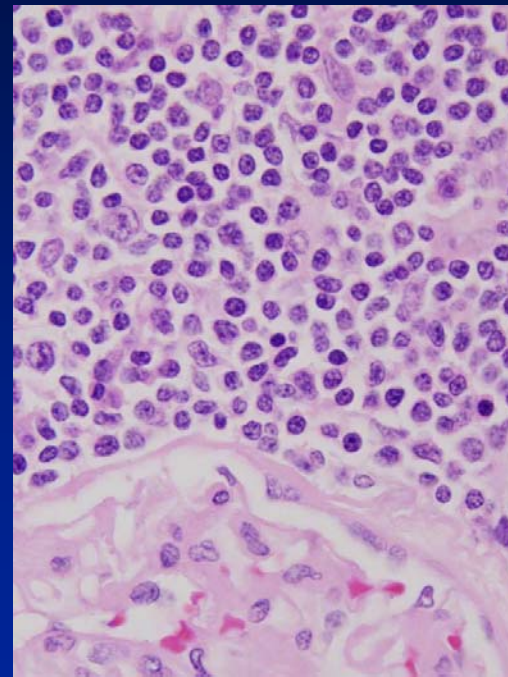
Histology and Immunophenotype



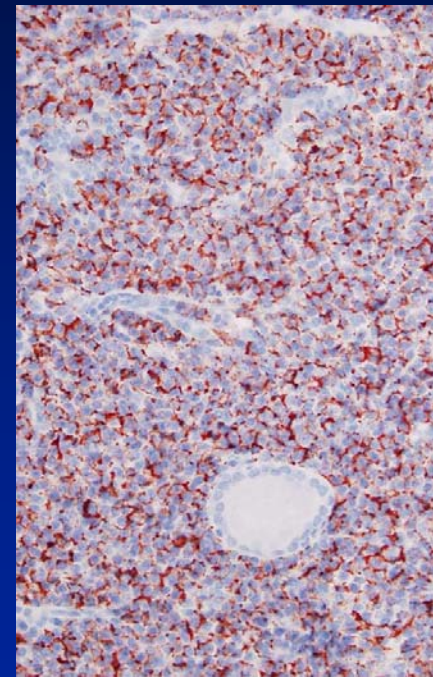
H&E x 100



H&E x 400



H&E x 1000



CD20 x 400

Diagnosis

Primary low-grade MALT
lymphoma of the kidney

Low-Grade MALT Lymphoma

Clinical Features

- Median age 61 years
- Slight female preponderance (M:F = 1:1.2)
- Low stage at presentation (I/II)
- Sites of involvement
 - Stomach (85%)
 - Other common sites are lung, small intestine and colon (IPSID), salivary glands, ocular adnexae, skin, thyroid, breast
- Association with chronic inflammation
 - Stomach - *H. pylori*
 - Thyroid - Hashimoto thyroiditis
 - Salivary glands - Sjögren syndrome
- Indolent clinical course

Low-Grade MALT Lymphoma

Morphologic and Immunophenotypic Features

- Morphology
 - Characteristic marginal zone B cells
 - Small to medium-sized cells with slightly irregular nuclear contours, dispersed chromatin, inconspicuous nucleoli, relatively abundant pale cytoplasm
 - Plasmacytic differentiation is common
 - Reactive germinal centers
 - Lymphoepithelial lesions
- Immunophenotype
 - CD20+, CD5-, CD10-
 - Monotypic immunoglobulin light chain

Low-Grade MALT Lymphoma

Specific Chromosomal Translocations

- **t(11;18)(q21;q21)** - *API2* and *MALT1*
 - Fusion transcript
 - ~15% of MALT lymphomas - 30% gastric, 40% lung
- **t(14;18)(q32;q21)** - IgH and *MALT1*
 - Overexpression of MALT1
 - ~10% of MALT lymphomas - liver, lung, ocular adnexae
- **t(1;14)(p22;q32)** - *BCL10* and IgH
 - Overexpression of BCL10
 - <5% of MALT lymphomas – often advanced stage
- **t(3;14)(p14.1;q32)** – *FOXP1* and IgH
 - Recently described (2005)
 - <10% of MALT lymphomas – thyroid, ocular adnexae, skin

Primary Low-Grade MALT Lymphoma of Kidney

Clinical Features

- Rare
 - 16 reported cases
- Median age
 - 65 years (range 43-83 years)
- Slight male preponderance
 - M:F = 1.3:1
- No apparent side preference
 - 7 left, 6 right, 3 not specified
- No known predisposing inflammatory condition
- No association with a specific chromosomal translocation
- Most patients achieve clinical remission

Primary Low-Grade MALT Lymphoma of Kidney

Differential Diagnosis

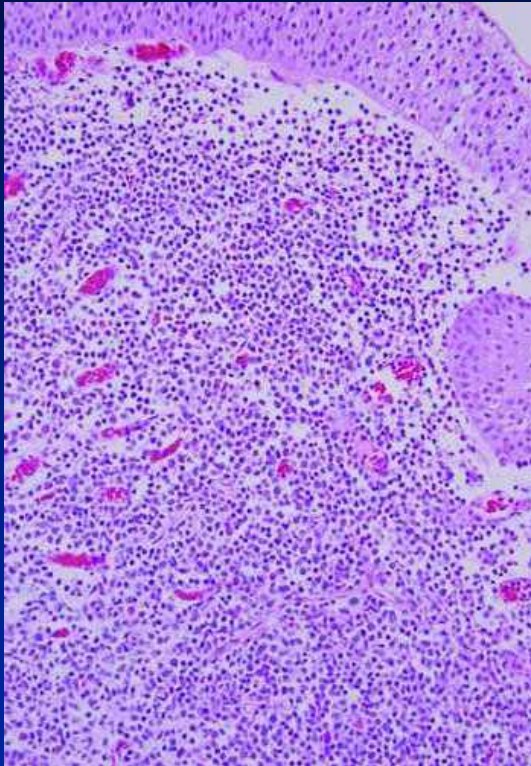
- Reactive processes
- Low-grade MALT lymphoma secondarily involving kidney
 - Also rare
- Small lymphocytic lymphoma/Chronic lymphocytic leukemia
 - Proliferation centers
 - CD5+
- Lymphoplasmacytic lymphoma/Waldenström macroglobulinemia
 - IgM monoclonal gammopathy
- Mantle cell lymphoma
 - Cytologically monotonous without plasmacytoid differentiation
 - Positive for CD5 and cyclinD1

Case 4

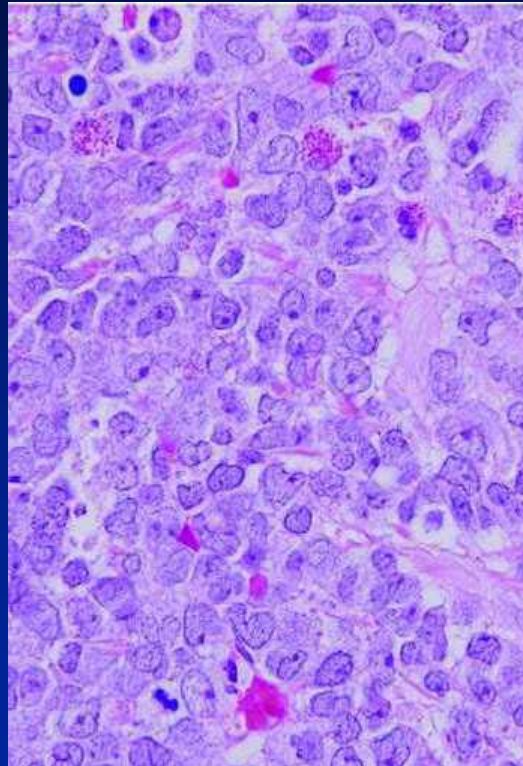
Case History

- The patient was a 47 year old man who presented with intermittent hematuria, slight swelling of the right testis, and flank pain. He was otherwise well. Physical examination was remarkable only for a 4 cm hard painless mass in the right epididymis. Laboratory tests, including a complete blood count and serum chemistries, were within normal limits. Bone marrow examination showed only a slight monocytosis. CT scan of the abdomen and pelvis showed a 4x2x3 cm mass in the right posterior wall of the urinary bladder and right hydroureter.
- Cystoscopic examination demonstrated a sessile bladder mass in the trigone that obstructed the right ureteral orifice. The patient underwent an excisional biopsy and placement of a right ureteral stent .

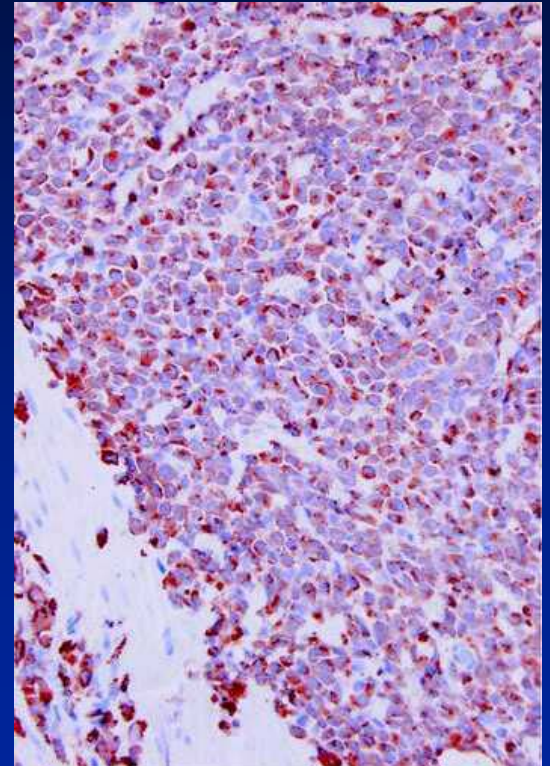
Histology



H&E x 200



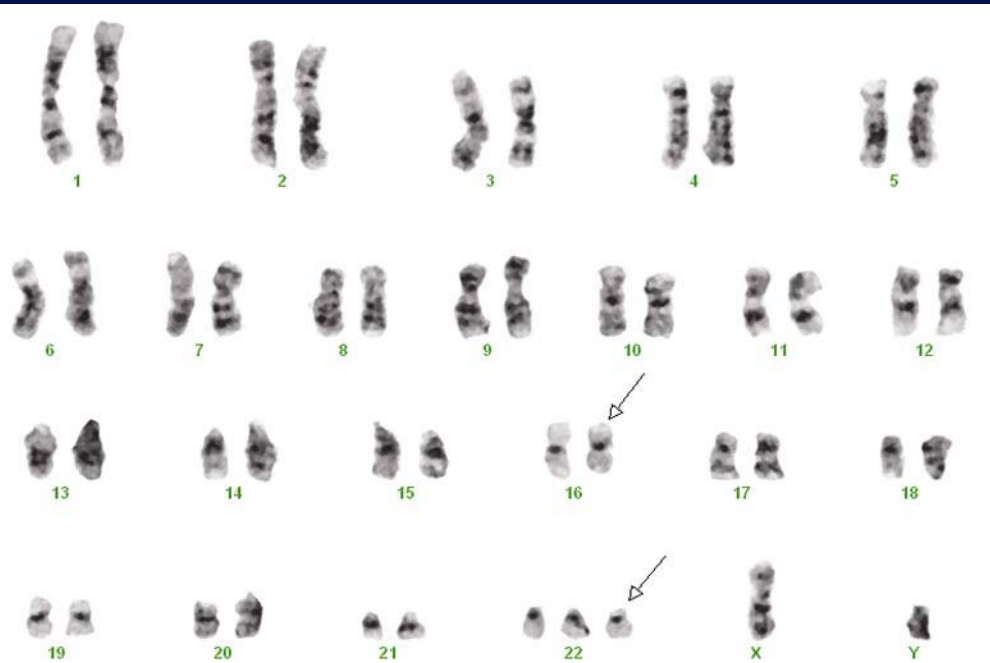
H&E x 1000



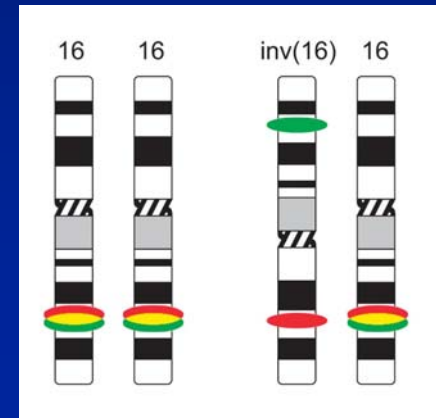
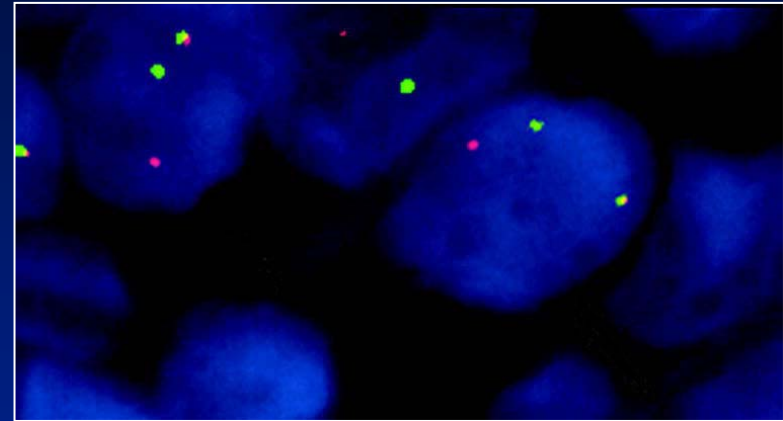
MPO x 400

Cytogenetics

inv(16)(p13.1q22)



47,XY,inv(16)(p13.1q22),+22



Diagnosis

Myeloid sarcoma of the urinary
bladder with inv(16)

Myeloid Sarcoma

- Definition: a tumor mass of myeloblasts, immature myeloid cells, or monoblasts in an extramedullary site or in bone
- Synonyms: chloroma, granulocytic sarcoma, extramedullary myeloid cell tumors

Myeloid Sarcoma

Clinical Features

- May occur *de novo* or concurrently with AML, CML, MPD, or MDS
- May precede AML by months to years
- May be the initial manifestation of relapse in a patient previously treated for AML
- Myeloid sarcoma is more commonly found in patients with
 - AML with maturation and t(8;21)(q22;q22)
 - Myeloid leukemias with monocytic differentiation
 - acute myelomonocytic leukemia with eosinophilia with inv(16)(p13q22) or t(16;16)(p13;q22)
 - acute monocytic leukemia
 - chronic myelomonocytic leukemia

Myeloid Sarcoma

Histologic Features

- Most MS are composed of myeloid precursors and can be divided into three subtypes based on the degree of differentiation
 - Well-differentiated
 - Neoplastic cells at all stages of differentiation
 - Admixed eosinophilic myelocytes common
 - Poorly-differentiated
 - Large cells with irregular nuclear contours, vesicular chromatin, distinct nucleoli
 - Admixed eosinophilic myelocytes infrequent
 - Blastic
 - Medium or large cells with blastic chromatin and inconspicuous nucleoli
 - Eosinophilic myelocytes usually absent

Myeloid Sarcoma Prognosis

- In patients with a previous history of MPD (including CML) or MDS, MS is equivalent to blast transformation
- In patients with AML, the prognosis is equivalent to that of the underlying AML
- Isolated MS may respond to localized radiation therapy

Myeloid Sarcoma

Cytochemical and Immunohistochemical Features

- Cytochemical reactions (touch preparations)
 - Myeloperoxidase
 - Naphthol ASD chloroacetate esterase
 - Non-specific esterase
- Immunohistochemical stains
 - CD43
 - Myeloperoxidase
 - Chloroacetate esterase
 - Lysozyme
 - CD68

Myeloid Sarcoma

Differential Diagnosis

- Poorly-differentiated carcinoma
- Non-Hodgkin lymphoma
 - Lymphoblastic lymphoma
 - Burkitt lymphoma
 - Large cell lymphoma
- Small round cell tumors
 - Neuroblastoma
 - Ewing's sarcoma/PNET
 - Rhabdomyosarcoma

References

Follicular Lymphoma of the Testis in Childhood

- Moertel CL, et al. Follicular large cell lymphoma of the testis in a child. *Cancer*. 1995;75:1182-1186.
- Finn LS, et al. Primary follicular lymphoma of the testis in childhood. *Cancer*. 1999;85:1626-1635.
- Lu D, et al. Primary follicular large cell lymphoma of the testis in a child. *Arch. Pathol. Lab. Med.* 2001;125:551-554.
- Pileri SA, et al. Primary follicular lymphoma of the testis in childhood: an entity with peculiar clinical and molecular characteristics. *J. Clin. Pathol.* 2002;55:684-688.
- Pakzad K, et al. Follicular large cell lymphoma localized to the testis in children. *J. Urol.* 2002;168:225-228.
- Lorsbach RB, et al. Clinicopathologic analysis of follicular lymphoma occurring in children. *Blood*. 2002;99:1959-1964.
- Heller KN, et al. Primary follicular lymphoma of the testis: excellent outcome following surgical resection without adjuvant chemotherapy. *J. Pediatr. Hematol. Oncol.* 2004;26:104-107.

References

Primary Lymphoma of the Epididymis

- Schned AR, et al. Primary histiocytic lymphoma of the epididymis. *Cancer*. 1979;43:1156-1163.
- Heaton JP and Morales A. Epididymal lymphoma: an unusual scrotal mass. *J. Urol*. 1984;131:353-354.
- Ginaldy L, et al. Epididymal lymphoma: a case report. *Tumori*. 1993;79:147-149.
- Ferry JA, et al. Malignant lymphoma of the testis, epididymis, and spermatic cord: a clinicopathologic study of 69 cases with immunophenotypic analysis. *Am J. Surg. Pathol*. 1994;18:376-390.
- McDermott MB, et al. Malignant lymphoma of the epididymis: a case report of bilateral involvement by a follicular large cell lymphoma. *Cancer*. 1995;75:2174-2179.
- Kausch I, et al. Primary lymphoma of the epididymis. *J. Urol*. 1998;160:1801-1802.
- Au WY, et al. T-cell intravascular lymphomatosis (angiotropic large cell lymphoma): association with Epstein-Barr viral infection. *Histopathology*. 1997;31:563-567.
- Novella G, et al. Primary lymphoma of the epididymis. *Urol. Int*. 2001;67:97-99.
- Vega F, et al. Primary paratesticular lymphoma: a report of two cases and review of the literature. *Arch. Pathol. Lab. Med*. 2001;125:428-432.

References

Primary Low-Grade MALT Lymphoma of Kidney

- Parveen T, et al. Low-grade B-cell lymphoma of mucosa-associated lymphoid tissue arising in the kidney. *Arch. Pathol. Lab. Med.* 1993;117:780-783.
- Jindal B, et al. Indolent behaviour of low-grade B cell lymphoma of mucosa-associated lymphoid tissue arising in the kidney. *Urol. Int.* 2001;67:91-93.
- Qiu L, et al. Low-grade mucosa-associated lymphoid tissue lymphoma involving the kidney: report of three cases and review of the literature. *Arch. Pathol. Lab. Med.* 2006;130:86-89.
- Colovic M, et al. Primary MALT lymphoma of the kidney. *Hematol Cell. Ther.* 1999;41:229-232.
- Mita K, et al. Primary mucosa-associated lymphoid tissue lymphoma in the renal pelvis. *Urol. Int.* 2002;69:241-243.
- Stokes MB, et al. Membranoproliferative glomerulonephritis associated with low-grade B-cell lymphoma presenting in the kidney. *Clin. Nephrol.* 2002;57:303-309.
- Tuzel E., et al. Primary renal lymphoma of mucosa-associated lymphoid tissue. *Urology.* 2003;61:463.
- Mhaweck P, et al. Pathologic case quiz: a unilateral renal mass in an elderly woman. *Arch. Pathol. Lab. Med.* 2000;124:919-920.
- Garcia M, et al. Low-grade AMLT lymphoma involving kidney: a report of 9 cases and review of the literature. (submitted).

References

Myeloid Sarcoma of the Urinary Bladder

- Liu PI, et al. Autopsy study of granulocytic sarcoma (chloroma) in patients with myelogenous leukemia, Hiroshima-Nagasaki 1949-1969. *Cancer*. 1973;31:948-955.
- Chaitin BA, et al. Hematologic neoplasms with initial manifestations in lower urinary tract. *Urology*. 1984;23:35-42.
- Cartwright PC, et al. Leukemic relapse presenting with ureteral obstruction caused by granulocytic sarcoma. *J. Urol*. 1991;146:1354-1355.
- Bekassy AN, et al. Granulocytic sarcoma after allogeneic bone marrow transplantation: a retrospective multicenter survey. *Bone Marrow Transplant*. 1996;17:801-808.
- Aki H, et al. Primary granulocytic sarcoma of the urinary bladder: case report and review of the literature. *Urology*. 202;60:345-347.
- Kerr P, et al. Bladder chloroma complicating refractory anemia with excess blasts. *Br. J. Haematol*. 2002;118:688.
- Uner A, et al. Granulocytic sarcoma of the urinary bladder. *Am J. Hematol*. 2004;75:262-263.
- Al-Quran A, et al/ Myeloid sarcoma of the urinary bladder and epididymis as a primary manifestation of acute myeloid leukemia with inv(16). *Arch Pathol. Lab. Med*. 2006; 130:862-866.



Courtesy of K. Coombes, Ph