

Is Cytomegalovirus Associated With Human Colorectal Tumorigenesis?

Olaronke Akintola-Ogunremi, MD,¹ Qing Luo, MD,² Tong-Chuan He, MD, PhD,² and Hanlin L. Wang, MD, PhD¹

Key Words: Cytomegalovirus; Colorectal; Adenoma; Adenocarcinoma; Immunohistochemistry; Polymerase chain reaction

DOI: 10.1309/9QVRHDJUK6H2TURB

Abstract

Despite the rapid advance in the understanding of molecular pathways underlying human colorectal tumorigenesis, the causes that initiate dysregulation of the pathways remain largely unknown. Human cytomegalovirus (CMV) has been implicated as a potential etiopathogenetic agent. To further investigate whether CMV participates in human colorectal tumorigenesis, we examined 23 colorectal hyperplastic polyps, 65 colorectal adenomas, and 51 colorectal adenocarcinomas by immunohistochemical analysis using 2 antibody mixtures that recognize CMV immediate early, early, and delayed gene products. The results show that while typical nuclear staining (with or without cytoplasmic positivity) was observed in control cases of CMV colitis, no nuclear positivity was detected in any cases studied. Focal and weak cytoplasmic staining was noted in a subset of cases, particularly when a higher antibody concentration was used. This staining was believed to be nonspecific, however, because it also was observed in normal-appearing colonic mucosa. In addition, polymerase chain reaction failed to detect the presence of CMV DNA in 24 selected cases showing nonspecific cytoplasmic immunostaining. These observations demonstrate an absence of CMV proteins and DNA in human colorectal adenocarcinomas and their precursor lesions.

Colorectal adenocarcinoma is the third most common cancer in men and women and is the second leading cause of cancer death in the United States.^{1,2} Harkins et al³ recently detected cytomegalovirus (CMV) nucleic acids and proteins in a high proportion of human colorectal tumors but not in nonneoplastic colonic mucosa. These findings raise the question of whether persistent CMV infection can induce oncogenic pathways that eventuate in colorectal adenocarcinoma.

Detection of an infectious agent in human cancers might have important implications in cancer treatment and prevention. To further study whether CMV participates in human colorectal tumorigenesis, we examined colorectal hyperplastic polyps, adenomas, adenocarcinomas, and normal-appearing colonic mucosa for the presence of CMV proteins and DNA.

Materials and Methods

Specimens

The specimens included in the study consisted of 23 colorectal hyperplastic polyps, 65 colorectal adenomas, and 51 colorectal adenocarcinomas. All hyperplastic polyps were obtained by endoscopic biopsy and all adenocarcinomas by surgical resection. Of the adenomas, 54 were biopsy specimens, and the remaining 11 were surgically resected. All cases were sporadic with no known association with cancer-predisposing syndromes. Formalin-fixed, paraffin-embedded tissue blocks were available for each case. H&E-stained slides were reexamined to confirm the original diagnosis. In 77 cases, the selected blocks contained sizable, histologically normal-appearing colonic mucosa.

Immunohistochemical Analysis

Immunohistochemical staining was performed on 4- μ m tissue sections using the LSAB Plus system (DAKO, Carpinteria, CA) and the ABC kit (Vector Laboratories, Burlingame, CA) according to the manufacturers' instructions with slight modifications. Briefly, deparaffinized tissue sections first were treated with 3% hydrogen peroxide for 15 minutes to inhibit endogenous peroxidase activity followed by antigen retrieval using microwave heating in a 10-mmol/L concentration of citrate buffer (pH 6.0) for 8 minutes. After incubation with blocking serum for 20 minutes, sections were incubated with primary antibodies (described in the next paragraph) for 1 hour at room temperature. After further incubation with biotinylated link antibody and peroxidase-labeled streptavidin, the staining was developed by reaction with diaminobenzidine substrate-chromogen solution followed by counterstaining with hematoxylin 7211 (Richard-Allan Scientific, Kalamazoo, MI). In each experiment, a negative control sample in which the primary antibodies were replaced by preimmune mouse IgG was included. Four cases of CMV colitis with nuclear and cytoplasmic viral inclusions identified on routine H&E-stained slides were used as positive control samples.

The primary antibodies used in the study included 2 antibody mixtures. One was DAKO-CMV (DAKO) that contained 2 mouse monoclonal antibodies, DDG9 and CCH2, recognizing CMV immediate early and early gene products, pp76 and pp43, respectively. A 1:80 dilution was used. The other mixture, NCL-CMVpp65 (Novocastra, Newcastle upon Tyne, England), contained clones 2 and 6 mouse monoclonal antibodies that recognized CMV delayed gene product pp65. This was used at dilutions of 1:400 and 1:40.

The immunostained slides were reviewed independently by 2 observers (O.A.O., H.L.W.). Nuclear staining (with or without cytoplasmic positivity) was considered positive. Cytoplasmic staining only (without nuclear staining) also was recorded and stratified as diffuse (>50% of the cells stained) or focal and strong or weak according to the staining intensity; *strong* was defined as intensity comparable to that seen in positive control samples of CMV colitis. Normal-appearing colonic mucosa, when present in the same tissue sections, was evaluated similarly.

Isolation of Genomic DNA From Paraffin-Embedded Sections

Two 6- μ m sections of each sample were deparaffinized and stained with H&E. After examination under a microscope, the tumor-containing regions were scraped carefully with sterile razor blades and collected into a set of 1.7-mL Eppendorf tubes containing 30 μ L of a 0.2-mol/L concentration of sodium hydroxide and a 1.0-mmol/L concentration of EDTA. The tubes were incubated at 80°C for 30 minutes, followed by

mixing and centrifugation at 13,000 rpm at room temperature for 10 minutes. The supernatants were collected and transferred into a new set of 1.7-mL Eppendorf tubes containing 180 μ L of polymerase chain reaction (PCR)-grade DNase-free deionized water. The resultant genomic DNA was kept at -20°C and ready for use in PCR amplification. DNA quality was examined using a pair of PCR primers specific for the human β -actin gene.

Nested PCR Amplification

The first-round PCR amplification was performed in a 25- μ L reaction volume containing 5 μ L of each genomic DNA sample, using the following pair of oligonucleotides: 5'-TCCAACACCCACAGTACCCGT-3' and 5'-CGGAAACGATGGTGTAGTTCG-3', according to Kühn et al.⁴ A touch-down cycling program was performed as follows: 95°C for 2 minutes, 1 cycle; 92°C for 20 seconds, 68°C to 55°C (1°C decrease per cycle) for 30 seconds, 70°C for 30 seconds, 12 cycles; 92°C for 20 seconds, 55°C for 30 seconds, 70°C for 30 seconds, 30 cycles; and 70°C for 5 minutes, 1 cycle. Five microliters of the PCR products was analyzed on 1.2% agarose gels. The expected product was a 268-base-pair (bp) fragment.

The second-round (nest) PCR amplification was carried out by using 1 μ L of the first-round PCR products as templates in 25- μ L reactions. The sequences of the inside primer pair were as follows: 5'-GCCCGCCGCGGCAGCACCTGGCT-3' and 5'-GTAAACCACATCACCCGTGGA-3'.⁴ A regular PCR cycling protocol was used: 95°C for 2 minutes, 1 cycle; 92°C for 20 seconds, 55°C for 30 seconds, and 70°C for 30 seconds, 30 cycles. At the end of amplification, 10 μ L of the PCR products was analyzed on 1.2% agarose gels. The resultant product was expected to be a 106-bp fragment.

Results

Although typical nuclear staining was observed in all 4 cases of CMV colitis using both anti-CMV antibody mixtures **Image 1**, no nuclear immunoreactivity was detected in any cases of colorectal hyperplastic polyp, adenoma, or adenocarcinoma included in the study. Instead, focal cytoplasmic staining was observed in a small fraction of the cases. As shown in **Table 1**, cytoplasmic staining was seen not only in adenomas **Image 2** and adenocarcinomas **Image 3** but also in hyperplastic polyps and histologically normal-appearing colonic mucosa **Image 4**. The frequency of cytoplasmic staining in normal-appearing mucosa was similar to the frequencies in adenomas and adenocarcinomas. This was demonstrated with both anti-CMV antibody mixtures used at optimal dilutions determined on positive control samples. In approximately one third of the cases in which the normal-appearing mucosa showed cytoplasmic

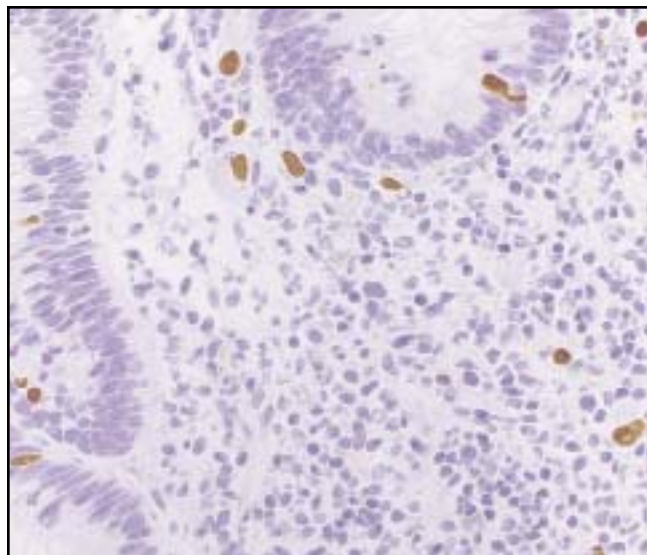


Image 1 Typical nuclear staining (with or without cytoplasmic positivity) observed in cytomegalovirus (CMV) colitis. The antibody mixture used for this case was DAKO-CMV, but similar results were obtained using NCL-CMVpp65 (original magnification $\times 400$). For proprietary information, see the text.

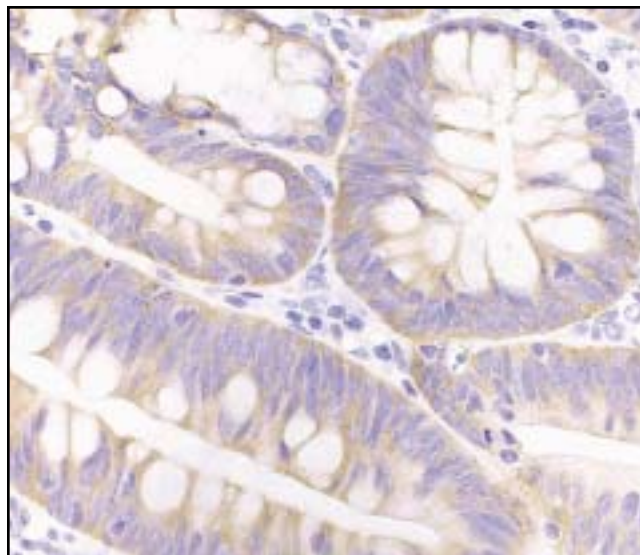


Image 2 Cytoplasmic staining observed in a subset of colorectal adenomas, which was locally diffuse. No nuclear staining was noted. The antibody mixture used for this case was DAKO-CMV (cytomegalovirus), but similar results were obtained using NCL-CMVpp65 (original magnification $\times 400$). For proprietary information, see the text.

Table 1
Cytoplasmic Staining in Human Neoplastic and Nonneoplastic Colorectal Epithelial Cells Using Two Different Anti-CMV Antibody Mixtures*

	No. (%) Positive	
	DAKO-CMV	NCL-CMVpp65
Adenocarcinoma (n = 51)	15 (29)	9 (18)
Adenoma (n = 65)	16 (25)	10 (15)
Hyperplastic polyp (n = 23)	2 (9)	3 (13)
Normal-appearing mucosa (n = 77)	16 (21)	9 (12)

CMV, cytomegalovirus.

* The antibody dilutions were 1:80 and 1:400 for DAKO-CMV and NCL-CMVpp65, respectively. For proprietary information, see the text.

staining, the neoplastic component present on the same sections was not stained simultaneously. In some of the cases in which cytoplasmic staining was observed in both neoplastic and nonneoplastic components, the stained areas were not contiguous topographically.

Although the overall cytoplasmic staining intensity was comparable among the positive cases including normal-appearing colonic mucosa, it was always weaker than that of nuclear staining seen in control cases of CMV colitis (Image 1). In every positive case, cytoplasmic positivity was locally diffuse, continuously involving all epithelial cells within the positive region (Images 2-4). This differed markedly from CMV colitis in which the infected cells with nuclear positivity were always individually and haphazardly distributed (Image 1).

Table 2 shows that when immunostaining was performed using a higher antibody concentration as used by Harkins et al,³ more pronounced cytoplasmic staining at a higher frequency was detected. However, no nuclear staining was observed.

PCR analysis for CMV genomic DNA was performed on 24 selected cases that showed cytoplasmic immunostaining. These included 1 hyperplastic polyp, 10 adenomas, and 13 adenocarcinomas. As shown in **Image 5**, although the expected band (106 bp) was demonstrated in 2 cases of CMV colitis, no distinct band was detected in any of the 24 cases under the same amplification conditions. To ensure adequate quality of genomic DNA prepared from tissue blocks, PCR analysis for the presence of human β -actin gene also was performed. The results showed that all 24 samples and 2 positive control samples were amplified effectively to a very similar extent under the same PCR amplification conditions used for CMV (data not shown).

Discussion

CMV is a member of the herpesvirus family that is a ubiquitous human pathogen worldwide. In the United States, 40% to 90% of adults are seropositive owing to exposure to the virus at some time during life.^{5,6} CMV infection is lifelong, and the latent virus can reactivate to cause serious illnesses when the host is immunocompromised.^{7,8} Various in vitro studies have demonstrated that the gene products of CMV are capable of modulating cell cycle progression and apoptosis by regulating the expression of a number of important

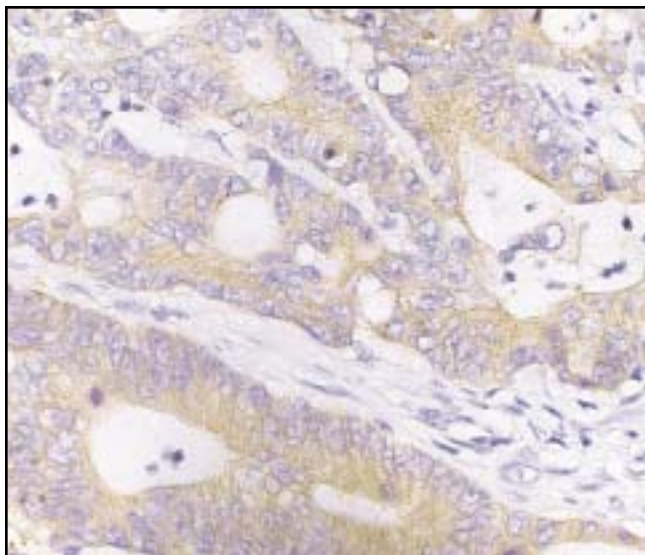


Image 3 Cytoplasmic staining observed in a subset of colorectal adenocarcinomas, which was locally diffuse. No nuclear staining was noted. The antibody mixture used for this case was DAKO-CMV (cytomegalovirus), but similar results were obtained using NCL-CMVpp65 (original magnification $\times 400$). For proprietary information, see the text.

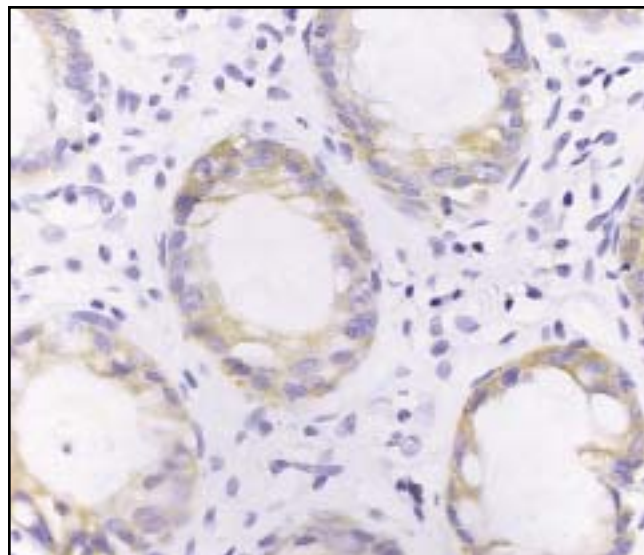


Image 4 Cytoplasmic staining observed in areas of nonneoplastic colorectal epithelium, which was locally diffuse. No nuclear staining was noted. The antibody mixture used for this case was DAKO-CMV (cytomegalovirus), but similar results were obtained using NCL-CMVpp65 (original magnification $\times 400$). For proprietary information, see the text.

host genes.⁸⁻¹¹ For example, CMV infection has been shown to transcriptionally activate the expression of the proto-oncogenes *c-fos*, *c-jun*, and *c-myc*.^{12,13} The immediate early viral proteins also can block the induction of apoptosis by tumor necrosis factor α or the adenovirus E1A proteins.¹⁴ In addition, CMV has been shown to transform a variety of mammalian cells that are tumorigenic in nude mice.⁹ One of the viral morphologic transforming regions, *mtrII*, encodes a 79 amino acid protein that is capable of binding to tumor suppressor p53 to inhibit p53-activated transcription.¹⁵ More recently, Kalejta and Shenk^{16,17} and Kalejta and colleagues¹⁸ reported that the CMV UL82 gene product pp71 stimulates cell cycle progression by inducing protein degradation of another important tumor suppressor Rb and its family members p107 and p130. Taken together, these experimental observations strongly suggest CMV to be a potential carcinogenic agent.

Despite the accumulation of in vitro evidence, the role of CMV infection in the development of human cancers has not been established. This is in contrast with other members of the herpesvirus family, such as Epstein-Barr virus and human herpesvirus 8, that are linked convincingly to several human malignant neoplasms.^{19,20} The association of CMV with human cancers has been studied in the uterine cervix, prostate, and colorectum, but the data have been conflicting and inconclusive.^{9,21}

CMV infects a wide range of human cells,²² including colonic epithelial cells that give rise to adenomas and adeno-

Table 2
Cytoplasmic Staining in Human Neoplastic and Nonneoplastic Colorectal Epithelial Cells Using the NCL-CMVpp65 Mixture at a Higher Concentration*

	No. (%) Positive
Adenocarcinoma (n = 8)	4 (50)
Adenoma (n = 9)	4 (44)
Hyperplastic polyp (n = 5)	2 (40)
Normal-appearing mucosa (n = 10)	4 (40)

* The antibody dilution was 1:40. For proprietary information, see the text.

carcinomas. The possible association of CMV with human colorectal adenocarcinomas was reported first in 1978 by Huang and Roche,²³ who detected CMV DNA in 4 of 7 colonic adenocarcinomas by membrane complementary RNA-DNA hybridization. It is interesting that CMV DNA also was detected in 1 of 2 cases of familial adenomatous polyposis but not in normal colonic tissues from the same patients or control cases of Crohn disease. However, several subsequent studies performed on small samples using various techniques²⁴⁻²⁹ have shown inconsistent results but overall demonstrated a lack of association of CMV with human colorectal adenocarcinomas.²⁶⁻²⁹ Considering the limitations of technologies and reagents available in the 1970s and 1980s, as pointed out by Harkins et al,³ it is necessary to revisit this important subject because it might have a great impact on cancer prevention and treatment and on our understanding of tumorigenesis.

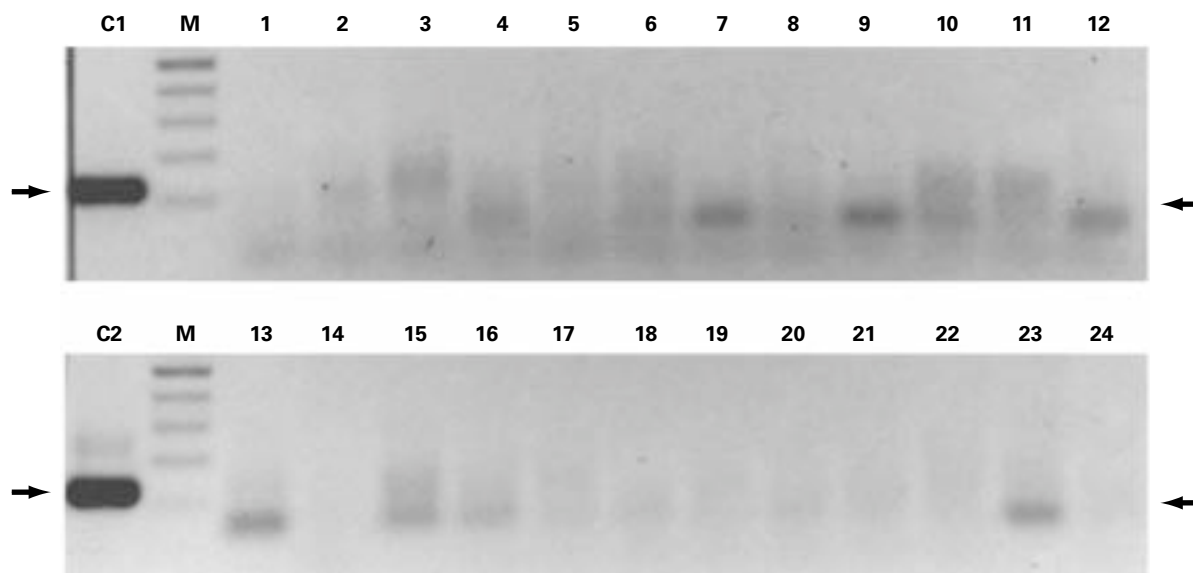


Image 5 Polymerase chain reaction analysis for the detection of cytomegalovirus (CMV) genomic DNA performed on 24 selected cases that showed cytoplasmic staining using anti-CMV antibodies. C1 and C2 represent 2 cases of positive control of CMV colitis that showed a distinct band (106 base pairs) as indicated by arrows. Note that no distinct band was detected in any of the 24 cases. The smears noted in some of the lanes likely represent primer dimers or oligomers. M, molecular weight size markers.

In the present study, we examined a large number of colorectal hyperplastic polyps, adenomas, and adenocarcinomas for the presence of CMV proteins and DNA by immunohistochemical and PCR analyses. We demonstrated no evidence of association between CMV and human colorectal tumorigenesis. The findings of focal cytoplasmic positivity in a small subset of the cases are best interpreted as nonspecific staining because no nuclear immunoreactivity was noted in any of these cases and because a similar staining pattern also was present in normal-appearing colonic mucosa at a similar frequency. In addition, the positivity frequency increased as the antibody concentration was increased. Furthermore, no CMV DNA was detected in cases that showed cytoplasmic staining. Our results are in contrast to those reported by Harkins et al,³ who detected CMV proteins, early gene messenger RNA, and DNA in a small series of human colorectal polyps (including hyperplastic polyps and tubular adenomas) and adenocarcinomas at a very high frequency. Although we noticed that the antibody concentrations used in that study were high (1:40 dilution for anti-pp65 and 1:20 for anti-IE1-72) and that the immunoreactivity appeared to be diffusely cytoplasmic, no immunoreactivity was detected in normal-appearing colonic epithelium adjacent to the polyps and adenocarcinomas by these authors. It is interesting to note that the same group of researchers also has recently reported that CMV proteins, RNA, and DNA were detected in 27 of 27, 10 of 10, and 6 of 6 human malignant gliomas, respectively, but not

in normal brain tissues,³⁰ and in 20 of 20, 4 of 4, and 8 of 9 cases, respectively, of human prostatic carcinoma and intraepithelial neoplasia.³¹

The data presented herein demonstrate no direct immunohistochemical and molecular evidence to support an association of CMV with human colorectal tumorigenesis. These results, however, do not exclude the possibility of a “hit-and-run” oncogenic mechanism proposed based on experimental observations that in most CMV-transformed cells, viral DNA is not detected, suggesting that the retention of CMV DNA is not essential for the transformed phenotype.^{9,32} Some of the CMV proteins might have mutagenic potential, which might be expressed only transiently in host cells to induce mutations in cellular genes leading to oncogenic transformation.³²

From ¹Department of Pathology and Immunology, Washington University School of Medicine, St Louis, MO; and ²Molecular Oncology Laboratory, Department of Surgery, University of Chicago Medical Center, Chicago, IL.

Presented in abstract form at the 93rd annual meeting of the United States and Canadian Academy of Pathology, Vancouver, Canada, March 6-12, 2004.

Address reprint requests to Dr Wang: Lauren V. Ackerman Laboratory of Surgical Pathology, Dept of Pathology and Immunology, Washington University School of Medicine, Campus Box 8118, 660 S Euclid Ave, St Louis, MO 63110-1093.

Acknowledgment: We thank Prosperidad Amargo for excellent technical assistance.

References

1. Landis SH, Murray T, Bolden S, et al. Cancer statistics, 1999. *CA Cancer J Clin*. 1999;49:8-31.
2. Stewart SL, King JB, Thompson TD, et al. Cancer mortality surveillance, United States: 1990-2000. *MMWR Surveill Summ*. 2004;53:1-108.
3. Harkins L, Volk AL, Samanta M, et al. Specific localisation of human cytomegalovirus nucleic acids and proteins in human colorectal cancer. *Lancet*. 2002;360:1557-1563.
4. Kühn JE, Wendland T, Eggers HJ, et al. Quantitation of human cytomegalovirus genomes in the brain of AIDS patients. *J Med Virol*. 1995;47:70-82.
5. Mocarski ES Jr, Courcelle CT. Cytomegaloviruses and their replication. In: Knipe DM, Howley PM, eds. *Fields Virology*. Philadelphia, PA: Lippincott Williams & Wilkins; 2001:2629-2673.
6. Singh N, Wannstedt C, Keyes L, et al. Impact of evolving trends in recipient and donor characteristics on cytomegalovirus infection in liver transplant recipients. *Transplantation*. 2004;77:106-110.
7. Vancikova Z, Dvorak P. Cytomegalovirus infection in immunocompetent and immunocompromised individuals: a review. *Curr Drug Targets Immune Endocr Metabol Disord*. 2001;1:179-187.
8. Landolfo S, Gariglio M, Gribaudo G, et al. The human cytomegalovirus. *Pharmacol Ther*. 2003;98:269-297.
9. Doniger J, Muralidhar S, Rosenthal LJ. Human cytomegalovirus and human herpesvirus 6 genes that transform and transactivate. *Clin Microbiol Rev*. 1999;12:367-382.
10. Kalejta RF, Shenk T. Manipulation of the cell cycle by human cytomegalovirus. *Front Biosci*. 2002;7:d295-d306.
11. Castillo JP, Kowalik TF. HCMV infection: modulating the cell cycle and cell death. *Int Rev Immunol*. 2004;23:113-139.
12. Hagemeyer C, Walker SM, Sissons PJ, et al. The 72K IE1 and 80K IE2 proteins of human cytomegalovirus independently trans-activate the *c-fos*, *c-myc* and *hsp70* promoters via basal promoter elements. *J Gen Virol*. 1992;73:2385-2393.
13. Boldogh I, AbuBakar S, Deng CZ, et al. Transcriptional activation of cellular oncogenes *fos*, *jun*, and *myc* by human cytomegalovirus. *J Virol*. 1991;65:1568-1571.
14. Zhu H, Shen Y, Shenk T. Human cytomegalovirus IE1 and IE2 proteins block apoptosis. *J Virol*. 1995;69:7960-7970.
15. Muralidhar S, Doniger J, Mendelson E, et al. Human cytomegalovirus mtrII oncoprotein binds to p53 and down-regulates p53-activated transcription. *J Virol*. 1996;70:8691-8700.
16. Kalejta RF, Shenk T. The human cytomegalovirus UL82 gene product (pp71) accelerates progression through the G₁ phase of the cell cycle. *J Virol*. 2003;77:3451-3459.
17. Kalejta RF, Shenk T. Proteasome-dependent, ubiquitin-independent degradation of the Rb family of tumor suppressors by the human cytomegalovirus pp71 protein. *Proc Natl Acad Sci U S A*. 2003;100:3263-3268.
18. Kalejta RF, Bechtel JT, Shenk T. Human cytomegalovirus pp71 stimulates cell cycle progression by inducing the proteasome-dependent degradation of the retinoblastoma family of tumor suppressors. *Mol Cell Biol*. 2003;23:1885-1895.
19. Thompson MP, Kurzrock R. Epstein-Barr virus and cancer. *Clin Cancer Res*. 2004;10:803-821.
20. Aoki Y, Tosato G. Pathogenesis and manifestations of human herpesvirus-8-associated disorders. *Semin Hematol*. 2003;40:143-153.
21. Rapp F. Cytomegalovirus and carcinogenesis. *J Natl Cancer Inst*. 1984;72:783-787.
22. Pass RF. Cytomegalovirus. In: Knipe DM, Howley PM, eds. *Fields Virology*. Philadelphia, PA: Lippincott Williams & Wilkins; 2001:2675-2705.
23. Huang ES, Roche JK. Cytomegalovirus DNA and adenocarcinoma of the colon: evidence for latent viral infection. *Lancet*. 1978;1:957-960.
24. Hashiro GM, Horikami S, Loh PC. Cytomegalovirus isolations from cell cultures of human adenocarcinomas of the colon. *Intervirology*. 1979;12:84-88.
25. Roche JK, Cheung KS, Boldogh I, et al. Cytomegalovirus: detection in human colonic and circulating mononuclear cells in association with gastrointestinal disease. *Int J Cancer*. 1981;27:659-667.
26. Brichacek B, Hirsch I, Zavadova H, et al. Absence of cytomegalovirus DNA from adenocarcinoma of the colon. *Intervirology*. 1980;14:223-227.
27. Hart H, Neill WA, Norval M. Lack of association of cytomegalovirus with adenocarcinoma of the colon. *Gut*. 1982;23:21-30.
28. Ruger R, Fleckenstein B. Cytomegalovirus DNA in colorectal carcinoma tissues. *Klin Wochenschr*. 1985;63:405-408.
29. Boguszakova L, Hirsch I, Brichacek B, et al. Absence of cytomegalovirus, Epstein-Barr virus, and papillomavirus DNA from adenoma and adenocarcinoma of the colon. *Acta Virol*. 1988;32:303-308.
30. Cobbs CS, Harkins L, Samanta M, et al. Human cytomegalovirus infection and expression in human malignant glioma. *Cancer Res*. 2002;62:3347-3350.
31. Samanta M, Harkins L, Klemm K, et al. High prevalence of human cytomegalovirus in prostatic intraepithelial neoplasia and prostatic carcinoma. *J Urol*. 2003;170:998-1002.
32. Shen Y, Zhu H, Shenk T. Human cytomegalovirus IE1 and IE2 proteins are mutagenic and mediate "hit-and-run" oncogenic transformation in cooperation with the adenovirus E1A proteins. *Proc Natl Acad Sci U S A*. 1997;94:3341-3345.