

**Liver tumor gray zones: how do we shine some light in there?**

**Focus on dysplastic nodules & hepatocarcinogenesis**

**Neil Theise MD**

**Depts of Pathology and Medicine**

**Beth Israel Medical Center – Albert Einstein College of Medicine**

**New York NY**

Introduction

In recent years, a growing literature has supported the concept that large nodules usually found in cirrhotic livers represent premalignant lesions in the setting of chronic liver disease. With the use of advanced imaging techniques in high risk populations in Japan, nodules suspicious for malignancy have often been identified and resected. While some resected lesions were found to be small HCCs, others were not. Some of these non-malignant nodules were devoid of atypia, some had architectural or cytological atypia insufficient for a diagnosis of HCC though suggestive of a premalignant state, while others contained microscopic subnodules of HCC. In follow-up studies from Japan, North America, Europe, and South Asia, including autopsy series and series of explants from liver transplant centers, the occasional finding of microscopic foci of HCC in the nodules was confirmed and significant associations with HCC elsewhere in the same liver were established. Such findings suggested that these nodular lesions are probably a frequent pathway of human hepatocarcinogenesis in a wide array of liver diseases and in diverse populations of patients.

Definitions and Observations

Dysplastic nodules (DNs) consist of hepatocytes and almost always contain some intact, normal appearing, portal tracts. Since they are most often found in the setting of cirrhosis they seem to correspond to what Edmondson called "adenomatous hyperplasia" (AH), though he viewed these lesions as having "limited growth potential". Other terms used include macroregenerative nodule (MRN), dysplastic nodule, hepatocellular pseudotumor, and adenomatoid hyperplasia. AH has been most widely used, though not exclusively, by researchers from Japan. MRN, coined by Furuya et al for the first Japanese autopsy study of the nodules, became the most widely accepted term in the earliest publications from North America and Europe. In 1997 a consensus document co-authored by International Working Party (with clinicians/investigators from Japan, North America, and Europe) rejected all of these terms as being imprecise if not actually misleading, suggesting the term "dysplastic nodule", with further classification as low or high grade, to replace them. Though researchers outside of Japan have generally accepted this new terminology, investigators in Japan have inconsistently adopted it, usually continuing to use AH as the nomenclature of choice. In his review dysplastic nodule will be the preferred term, however, recognizing at the same time that it, too, is problematic.

DNs are defined grossly as large hepatic nodules that are distinct from the surrounding liver parenchyma in terms of size, color, texture, or the degree to which they bulge from the cut surface of the liver. Confirmation that a nodule is in fact a DN comes with histologic examination and the identification of intact portal structures distributed

through the lesion. The number of these portal structures may be mildly or greatly reduced compared to a similar area of non-diseased hepatic parenchyma.

DNs have been found in a wide variety of chronic liver diseases, including processes which are hepatitic (hepatitis B, C, and autoimmune hepatitis), cholangitic (primary biliary cirrhosis, primary sclerosing cholangitis), metabolic (alpha-1-antitrypsin deficiency, primary hemochromatosis), and toxic (alcoholic liver injury). Typically, livers with DNs contain a small number of these nodules, rarely more than ten, although there are exceptions which will be discussed further on. DNs may be sub-classified as low grade or high grade. Low grade lesions may be devoid of atypia or display features of large cell change. They may be iron or copper retentive or they may be diffusely steatotic. They should not contain nodule-in-nodule type lesions or small cell change, let alone features closely associated with HCC; these changes would be indicative of the lesion being high grade. It is usually not possible at this time to radiographically distinguish small HCCs from DNs or high grade (HG) DNs from low grade (LG) DNs with complete confidence, nor is it usually possible to reliably make such distinctions on the basis of gross morphology. Histologic examination, either by biopsy or examination of a resected specimen, is required for accurate classification.

#### Histologic Features of Low grade DNs

Low grade DNs are very well defined nodules, being surrounded by a condensed rim of fibrous tissue similar to that of surrounding cirrhotic nodules. The nodules are thus not truly encapsulated. Portal tracts, present in virtually all DNs, are most often uniformly distributed in low grade DNs and may even be distributed in a virtually normal fashion with regularly intervening terminal hepatic venules. In some nodules, portal structures may be caught up in fibrous septa which partially subdivide the nodule. The hepatocytes of low grade DNs tend to be of comparable size to hepatocytes outside the lesion. The hepatocytes may display changes characteristic of the underlying liver disease affecting the surrounding liver, such as fatty change, Mallory bodies, or increased iron or copper deposition. These changes will be distributed in the DN as they are in surrounding cirrhotic nodules. Occasionally, a DN in a non-siderotic liver may contain increased iron or a DN in an otherwise siderotic liver will be iron free; it would still be classified as low grade. Rarely, a similar increase in copper, in an otherwise copper-free liver, is also seen. These changes in DNs, when not confined to a subnodule within the lesion, i.e. copper or iron retention and fat accumulation, may represent a marker of the clonality in the DN hepatocytes. We will return to this subject below.

Studies of large cell change in cirrhosis and statistical evaluation of the association of this feature in DNs and HCC indicate the likelihood that large cell change is usually a reactive, not a premalignant change (though it also may serve as a marker for livers at increased risk for HCC). Therefore, it has been recommended that DNs containing large cell change without other atypical features be classified as low grade lesions.

Scirrhou changes, stellate fibrosis of DN portal tracts or diffuse pericellular fibrosis in regions of DN parenchyma, have previously been thought to be features of high grade DNs; however, careful analysis of scirrhou change highlights that it does not segregate with other features of high grade lesions, appearing in otherwise low grade or high grade lesions equally (author's unpublished data). Thus we would recommend that scirrhou change be excluded from the diagnostic criteria for high grade DNs.

### Histologic Features of High grade DNs

High grade DNs are defined by the presence of small cell change and/or architectural atypia. They are usually well circumscribed and surrounded by a condensed rim of fibrous tissue, like low grade lesions, though some may merge focally with adjacent liver parenchyma. The atypical features in high grade DNs may take a variety of forms and may be diffuse throughout the nodule or focal. Diffuse changes most often fall into the category of cellular atypia.

The definition of cellular atypia in this setting should be limited to small cell change: small, crowded hepatocytes with basophilic cytoplasm and an increased nuclear:cytoplasmic ratio. Small cell change appears to be consistently related to the development of HCC in a variety of studies and should remain a criterion for "atypical." This cellular feature is reported more frequently in studies from Japan than those from other countries; this discrepancy remains unexplained. Pseudoacinar structures resembling those seen in well differentiated HCC are a form of architectural atypia in high grade DNs and may be either focal or diffuse.

Focal atypia may merge with the surrounding DN parenchyma, but it more often occurs instead as a "nodule-in-nodule" lesion. Such subnodules often appear to compress the adjacent DN parenchyma and studies of proliferative rates of the cells making up these lesions indicate that they are proliferating more rapidly than the surrounding tissue. These subnodules may display small cell change, but may also show changes which are not classically "atypical" including fatty change, clear cell change, clusters of hepatocytes with Mallory's hyaline, increased iron uptake within the DN, iron resistance in an otherwise siderotic nodule, and accumulation of copper binding protein. Some expansile subnodules do not display any distinctive cytological features though, architecturally, they may display a pseudoacinar growth pattern. We have argued that all subnodules, with or without distinctive cellular changes, are appropriately defined as architectural atypia on the basis of the expansile growth and should warrant classification of the entire DN as a high grade lesion.

HCC may be identified in high grade DNs. These microfoci of HCC may display any of the features seen in larger HCCs, though they are usually well-differentiated. Typical growth patterns include pseudoacinus formation, thickened trabeculae or a scirrhous growth. Common cytological features include intracytoplasmic Mallory's hyaline, fatty change, clear cell change, iron resistance, and multinucleation. Multiple foci of HCC may also be found in a single DN and the histologic features of these foci are often different from each other. The DN parenchyma surrounding a microfocus of HCC will usually contain portal tracts and may consist of normal appearing hepatocytes, suggesting a background of a low grade MRN, or may show atypia, indicating a high grade background. Either way, by convention, DNs containing foci of HCC are classified as high grade.

### The Premalignant Nature Of DNs

The association of DNs with HCC is demonstrated in two ways. First, DNs are sometimes found in livers which also contain grossly apparent HCC elsewhere. Second, as mentioned above, DNs sometimes contain one or multiple microscopic foci of HCC. Both of these relationships have been found to achieve statistical significance. Beyond this statistical correlation, the atypical features often found in DNs include many which have previously been thought to be premalignant. Clustering of hepatocytes containing Mallory's hyaline and foci of iron resistance in siderotic nodules have been independently described as

pre-malignant changes. Small LCD, considered pre-malignant on the basis of morphometric analysis, is also seen and, in some series, is very common.

Other features which are commonly identified in mature HCC are found in high grade DN. For example, immunohistochemical studies of DN sinusoids reveals increasing degrees of "capillarization" (i.e. loss of endothelial fenestration, deposition of basement membrane and expression of antigens such as factor VIII and CD34) with the development of atypia and HCC. Studies of ploidy indicate increased frequency of aneuploidy in high grade DN. Immunohistochemical staining for AFP and p-ras demonstrates expression of these proteins in atypical foci and micro-foci of HCC. Clonal stepwise progression has also been demonstrated in a subnodule of HCC arising in a DN by Tsuda et al. In their study, they exploited integration of the hepatitis B surface antigen gene into host hepatocytes using restriction length polymorphism analysis, demonstrating that a micro-focus of HCC consisted of cells derived from the same clone as the surrounding DN parenchyma. The issue of clonality will be examined in more detail below.

These findings all represent static samplings of the process of malignant transformation. From the association of DN with HCC elsewhere in the same liver we deduce that DN is at least a marker of a liver with a tendency to generate malignancies. Several studies however now demonstrate that, when followed over time by serial biopsies or biopsy and then radiographic changes indicative of expansile growth, there is in fact progression from at least high grade DN to HCC.

In these longitudinal studies, it is interesting to note that low grade DN is not as obviously pre-malignant or as indicative of neighboring malignant transformation as are high grade DN. The data addressing this difference appears contradictory. Studies of the various aspects of DN mentioned -- proliferation, p-ras expression, ploidy, endothelial and extracellular matrix alterations -- find similarities between high grade DN and HCC. In the absence of these similarities between low grade DN and HCC, most of these researchers conclude that high grade lesions are related to HCC, whereas low grade lesions are related to regenerative nodules and are less clearly implicated in hepatocarcinogenesis.

Data from the largest series of liver explants both supports and goes against this view of low grade lesions (Hytioglou et al). On the one hand, a subset of livers was identified (n=13, of 155) which contained so many DN as to be virtually uncountable. When large LCD was excluded as a criterion for atypia, in all but one of these livers all the sampled DN were low grade. None of these livers contained HCC. All such livers were in patients with chronic hepatitis (hepatitis B, hepatitis C, or autoimmune hepatitis) and the mean age of these patients was significantly lower than the other patients with few or no DN. These findings suggest that these DN are actually large regenerative nodules that have not yet scarred down into smaller nodules, examples of the original "adenomatous hyperplasia" of Edmondson rather than neoplastic lesions. They might also correlate with large cirrhotic nodules which became undetectable on long term ultrasound surveillance in a study by Kondo et al. On the other hand, statistical associations of low grade lesions with co-existent HCC in this, as in earlier, series are strong even when high grade lesions are excluded from analysis.

Thus, the neoplastic, pre-malignant nature of low grade lesions seems more open to question than it does for high grade lesions, though perhaps a majority of researchers (authors included) favor a distinction between these lesions. An explanation for the discrepancies, which possibly resolves the apparent contradictions, has been suggested on the basis of hepatic stem cells.

### Speculations on the Early Stages of Human Hepatocarcinogenesis

How DNs actually form has not yet been firmly established. One early view suggested that an ordinary regenerative nodule in cirrhosis becomes more rapidly proliferative, therefore becoming larger. In turn, with the increased proliferation it also becomes at greater risk for the carcinogenic "hits", thereby giving rise to atypia and carcinoma. While simple, this hypothesis does not take into consideration three known facts about DNs. First, they can be found in livers in advance of cirrhosis and therefore do not always arise from a pre-existent regenerative nodule. Second, the presence of many intact portal tracts in most DNs, which have not yet been demonstrated to fully reconstitute after scarring and injury, suggests that they must be pre-existent to the formation of the DN, making it unlikely that a small cirrhotic nodule with few if any portal tracts could enlarge to a nodule with many portal tracts. Third, some DNs have been demonstrated to be clonal lesions, not hyperplastic phenomenon.

To account for these features, we have suggested an alternative process of DN development. This alternate hypothesis has been able to predict some previously unexplored features of DNs and, perhaps, can be broadened to explain other types of borderline or early carcinoma features. The steps of this hypothesis are as follows:

- 1) A clonal expansion of hepatocytes follows on the earliest carcinogenic events in response to any diffuse injury of the liver which leads to increased hepatocyte turn over;
- 2) These early hits lead to a clonal expansion of hepatocytes which spreads around adjacent portal structures rather than displacing them;
- 3) As the rest of the liver becomes scarred, progressing to later stages of disease and eventually cirrhosis, the island of clonal hepatocytes, if resistant to the scarring affecting the rest of the liver, would remain intact -- an island of relatively preserved hepatic parenchyma made up of neoplastic, clonal hepatocytes;
- 4) With establishment of cirrhosis in the adjacent liver, the clonal expansion takes on the appearance of a large cirrhotic nodule;
- 5) Having already undergone the earliest transforming events of hepatocarcinogenesis, the clonal, hepatocyte expansion remains at increased risk for later developments and, thus, the lesion becomes the likeliest site of full malignant transformation.

This hypothesis suggested a number of testable predictions that have resulted in supportive studies. First, expansion of a clonal population as described would not necessarily depend on rapid proliferation, but might arise from a relatively low proliferation rate balanced by inhibition of apoptosis. In fact, many studies of proliferation have confirmed that the low grade DNs and the background parenchyma of nodule-in-nodule type high grade DNs is no more highly proliferative, and is often less proliferative, than surround cirrhotic nodules.

Of course, if these hepatocytes had a survival advantage compared to surrounding non-neoplastic hepatocytes they would expand in a clustered fashion. One possibility is that they might be resistant to the disease damaging the surrounding parenchyma (e.g. inability to be virally infected, absence of antigen presentation once infected, etc.) or they might have impaired mechanisms of apoptosis. We tested this latter possibility and found that apoptosis did appear diminished in low grade DNs, only increasing with the emergence of atypia. The rates of apoptosis in low grade DNs were not significantly lower than those of surrounding regenerative nodules, however the ratio of apoptosis to proliferation was

increased in regenerative nodules, indicating that the hepatocyte populations, as expected, did have a survival advantage when compared to non-DN hepatocytes.

A key feature of our hypothesis of DN development is that the nodular appearance arises not from expansile growth, but because the clonal hepatocytic expansion with reduced or absent scarring while the surrounding, non-neoplastic liver becomes cirrhotic. Thus we made a second testable prediction: that there would be diminished stellate cell activation in dysplastic nodules. Again, our prediction was confirmed: activated stellate cells, as demonstrated by immunohistochemical staining for smooth muscle actin, were in significantly few number within dysplastic nodules than in the surrounding cirrhotic nodules. To our knowledge no other studies of this aspect of DN pathophysiology have been reported.

Finally, clonality of many, if not all, dysplastic nodules has been demonstrated in a number of studies. Interestingly, many regenerative-appearing nodules have also been identified as clonal expansions, and still more intriguingly, neighboring, clustered smaller cirrhotic nodules are often of the same clone. This suggests, once again, that the clonal expansion preceded the development of cirrhosis and that scarring subsequently subdivided the clonal expansion into separate nodules. Moreover, clonality of fields of hepatocytes has been identified in advance of cirrhosis, even in normal liver. Loss of heterozygosity studies show similar results.

This suggests that some clonality is not related to neoplastic transformation but is rather a product of liver tissue formation in embryogenesis. However, these data confirm that clonal expansions can in fact occur without displacing original portal structures, as we predicted in our model of DN development. How this precedes architecturally remains unclear. But in animal models of hepatocyte transplantation in which a small population of transplanted cells completely repopulates a genetically damaged liver, such as in the tyrosinemia mice of Markus Grompe and colleagues, complete repopulation around native structures, is readily demonstrated.

#### A generalized model of hepatocarcinogenesis

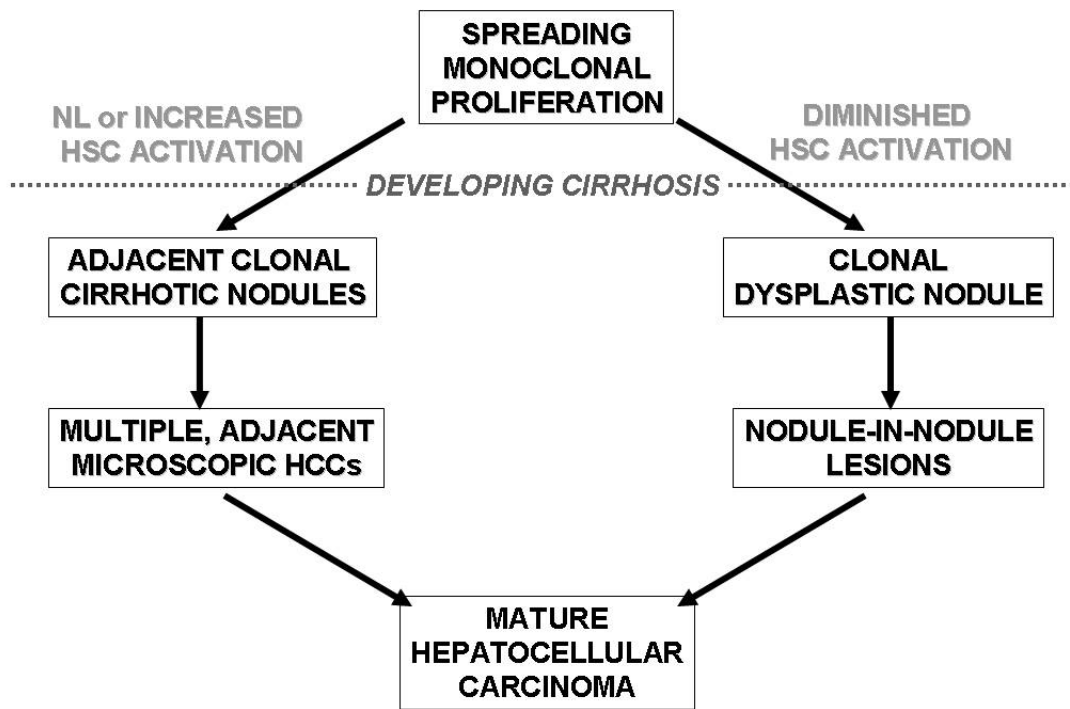
Thorough, routine examination of cirrhotic liver explants inevitably will yield some early HCCs which do not appear to arise within a demonstrable DN. These are relatively infrequent and fall in to two basic categories. The first is an HCC arising in a cirrhotic nodule that is not distinctive in any way, failing to differ from its neighbors in terms of color, texture, bulging, or size, i.e. what might be called a “de novo” HCC. This is very easy to contain within our concept of DN, simply showing up our inability to distinguish neoplastic nodules unless they supply us with a clear morphologic marker of their distinctiveness. Such small cirrhotic nodules with HCCs might simply be small, low grade DN, without the size or accumulation of pigment to declare itself as “special.”

The second category of small HCCs found incidentally in explants is rarer still. This consists of multiple very small HCCs, often with distinct morphologies and patterns of growth suggesting that they are independent lesions, arising in a very discrete cluster of neighboring, small, cirrhotic nodules in a liver otherwise devoid of HCC. Though no background DN is identified in these lesions, it perhaps represents the same process of HCC development from a prior clonal expansion as we have postulated for DN-related carcinogenesis. The clustering of so many nodules in a discrete area suggests that there is something distinctive about those clustered nodules. Relating this type of lesion to the

clustered cirrhotic nodules of identical clones, it lends support to the idea that the clonality is the important feature, the appearance as a DN merely an artifact of suppression of HSC activation. In clonal expansions in which HSC activation occurs at normal levels in response to injury then such clonal clusters occur and, just like DNs, can give rise to HCC. We may therefore suggest a broader conception of hepatocarcinogenesis as portrayed in the diagram (Fig. 1).

The Grey Zones: Areas of Diagnostic Uncertainty

This more generalized concept of early hepatocarcinogenesis can help to reconcile lesions, most often described by Japanese investigators, that do not match the classic descriptions of DNs. Most notably, lesions described as “early hepatocellular carcinoma”, which often have indistinct borders or are identified in the absence of fully established cirrhosis, may simply reflect differing stages of scarring within the neoplastic expansions as opposed to the surrounding liver. The indistinct nature of the lesions suggests that they are a different neoplastic pathway, but in fact may arise from a similar process as described in the Figure 1.



**Figure 1. Generalized scheme for human hepatocarcinogenesis.**

More difficult is the decision of where to draw the diagnostic line between “dysplasia” and “carcinoma.” An informal comparison of diagnoses for a range of hepatocellular neoplastic lesions amongst Japanese and non-Japanese pathologists

(unpublished data), shows a lack of consistency within and between those two groups when it comes to deciding “cancer” vs. “not yet cancer”. But there is great consensus amongst all the reviewing pathologists regarding more established carcinomas and low grade lesions. Not surprisingly, then, the “borderline” category is the current area of controversy and leads to the greatest confusion when trying to compare studies from different investigators.

Additional uncertainty in nodule characterization lies in the redundancy of so many adaptive or pathological changes in the liver, with each of many morphologic changes arising from very different causes. For example, fatty change in dysplastic nodules or early HCC may arise from clonal changes in lipid metabolism or sensitivity to alcohol toxicity, or to changes in the ratio of arterial to portal blood flow as the latter is lost during the neoplastic progression. Mallory bodies may also represent a clonal marker of neoplastic alterations in gene expression, but could arise from chronic cholestasis in a nodule with incomplete biliary drainage, or an altered response to alcohol or lipid metabolism.

Hepatocytes within portal tract or septal stroma, what have been referred to as may represent either invasion or non-neoplastic hepatocytes within the scar, as part of the injury/regeneration process affecting the liver as a whole. Exploiting the association of such intraseptal hepatocytes in non-neoplastic tissue with ductular reactions (highlighted by immunostaining for biliary type cytokeratins, i.e. CK7 or CK19), we have been able to improve our capacity to recognize true stromal invasion (authors unpublished data). The absence of a ductular reaction confirms that foci of intrastromal hepatocytes are invading and not part of a ductular-reaction mediated regenerative process.

The most interesting possible advances may come with sophisticated molecular techniques. Recently, a study by Nam et al performed gene array analysis on a range of hepatocellular neoplasia, including LGDN, HGDN, and mature HCC of histologic grades 1, 2, and 3. They were able to identify panels of genes where changes of gene expression (either up or down) could reliably distinguish LGDNs from HGDNs from grade 1 HCC. Likewise, the three grades of HCC could be distinguished from each other.

### Summary

In the last decade, careful examination of explanted cirrhotic livers in liver transplant centers around the world have confirmed the findings of the earlier Japanese investigators: that dysplastic nodules (by this or any other name) represent hepatic premalignant lesions in the setting of chronic liver disease. Careful examination of their gross and microscopic morphologies has led to our suggested hypothesis of pre-cirrhotic, spreading clonal expansions, resistant to scarring, which result in neoplastic islands of hepatic parenchyma. The resultant distinctive nodules, often marked by features suggestive of their clonality (such as increased pigment), are at increased risk for subsequent carcinomatous events, and thereby give rise to HCC. Specialized molecular and immunohistochemical studies confirm many aspects of this hypothesis.

In suggesting that some aspects of DN pathophysiology are not integral to the carcinogenetic pathway (i.e. inhibition of HSC inactivation), this hypothesis serves a broader purpose, explaining the various settings in which early HCCs are found in cirrhotic explants and in wedge resections of radiographically defined lesions. Discrepancies between Japanese and non-Japanese investigations regarding “dysplasia” and “early” HCCs can now be seen to

reflect not different biological pathways, but differences in detection, interpretation, and application of nomenclature.

These differences may fade away as increasing international collaborative work brings investigators of diverse nationalities into more regular contact, supporting movement toward a commonly acceptable nomenclature and set of diagnostic criteria. Ultimately, a reasoned understanding of the pathophysiology of these lesions, obtained by these initial histologic observations, through more detailed molecular and physiological studies, will hopefully lead to more efficient and available early detection, and perhaps chemoprevention approaches to hepatic malignancy.

### Selected References

*(Historically important series, nomenclature classification, reviews, key clinico-pathologic correlation studies; \*, of particular note).*

- \*1. Aihara T, Noguchi S, Sasaki Y, Nakano H, Imaoka S. Clonal analysis of regenerative nodules in hepatitis C virus-induced liver cirrhosis. *Gastroenterology* 107:1805-1811, 1994.
2. Aihara T, Noguchi S, Sasaki Y, Nakano H, Monden M, Imaoka S. Clonal analysis of precancerous lesion of hepatocellular carcinoma. *Gastroenterology* 111:455-461, 1996.
3. Falkowski O, West AB, Chiriboga L, et al. Intraseptal hepatocytes in cirrhosis: evidence for regeneration from stem cells. *Mod Pathol*
4. Ferrell L, Wright T, Lake J, Roberts J, Ascher N. Incidence and diagnostic features of macroregenerative nodules versus small hepatocellular carcinoma in cirrhotic livers. *Hepatology* 16: 1372-1381, 1992.
5. Furuya K, Nakamura M, Yamamoto Y, Toge K, Otsuka H. Macroregenerative nodule of the liver. A clinicopathological study of 345 autopsy cases of chronic liver disease. *Cancer* 61: 99-105, 1988.
6. Hytioglou P, Theise ND, Schwartz M, Mor E, Miller C, Thung SN. Macroregenerative nodules in a series of adult cirrhotic liver explants: Issues of classification and nomenclature. *Hepatology* 21: 703-708, 1995.
- \*7. International Working Party. Terminology of nodular hepatocellular lesions. *Hepatology* 22: 983-993, 1995.
8. Kojiro M. Pathology of early HCC-progression from early to advanced. *Hepato-Gastroenterology*, 45:1203-1205, 1998.
9. Maggioni M, Coggi G, Cassani B, Bianchi P, Romagnoli S, Mandelli A, et al. Molecular changes in hepatocellular dysplastic nodules on microdissected liver biopsies. *Hepatology* 32: 942-946, 2000.
- \*10. Nam SW, Park JY, Ramasamy A, Shevade S, Islam A, et al. Molecular changes from dysplastic nodule to hepatocellular carcinoma through gene expression profiling. *Hepatology*, 42: 809-818, 2005.
9. Okuda T, Wakasa K, Kubo S, Hamada T, Fujita M, Enomoto T, et al. Clonal analysis of hepatocellular carcinoma and dysplastic nodule by methylation pattern of X-chromosome linked human androgen receptor gene. *Cancer Lett* 164: 91-96, 2001.
10. Paradis V, Laurendeau I, Vidaud M, Bedossa P. Clonal analysis of macronodules in cirrhosis. *Hepatology* 28:953-958, 1998.

11. Park YN, Chae KJ, Kim YB, Park C, Theise ND. Apoptosis and proliferation in hepatocarcinogenesis related to cirrhosis. *Cancer* 92:2733-2738, 2001.
12. Park YN, Yang CP, Cubukcu O, Thung SN, Theise ND. Hepatic stellate cell activation in dysplastic nodules: evidence for an alternate hypothesis concerning human hepatocarcinogenesis. *Liver* 17:271-274, 1997.
13. Park YN, Yang CP, Fernandez GJ, Cubukcu O, Thung SN, Theise ND. Neoangiogenesis and sinusoidal "capillarization" in dysplastic nodules of the liver. *Am J Surg Pathol.* 22: 656-662, 1998.
14. Sakamoto M, Hirohashi S, Shimosato Y. Early stages of multistep hepatocarcinogenesis: Adenomatous hyperplasia and early hepatocellular carcinoma. *Hum Pathol* 22: 172-178, 1991.
15. Sakamoto M, Hirohashi S. Natural history and prognosis of adenomatous hyperplasia and early hepatocellular carcinoma: multi-institutional analysis of 53 nodules followed up for more than 6 months and 141 patients with single early hepatocellular carcinoma treated by surgical resection or percutaneous ethanol injection. *Jpn J Clin Oncol.* 28(10):604-8, 1998.
16. Seki S, Sakaguchi H, Kitada T, Tamori A, Takeda T, Kawada N, et al. Outcomes of dysplastic nodules in human cirrhotic liver: a clinicopathological study. *Clin Cancer Res* 6: 3469-3473, 2000.
17. Terada T, Terasaki S, Nakanuma Y. A clinicopathologic study of adenomatous hyperplasia of the liver in 209 consecutive cirrhotic livers examined by autopsy. *Cancer* 72: 1551-1556, 1993.
18. Theise ND, Lapook JD, Thung SN. A macroregenerative nodule containing multiple foci of hepatocellular carcinoma in a non-cirrhotic liver. *Hepatology* 17: 993-996, 1993.
19. Theise ND, Marcelin K, Goldfischer M, Hytioglou P, Ferrell L, Thung SN. Low proliferative activity in macroregenerative nodules: Evidence for an alternate hypothesis concerning human hepatocarcinogenesis. *Liver* 16: 134-139, 1996.
- \*20. Theise ND, Park YN, Kojiro M. Dysplastic nodules and hepatocarcinogenesis. *Clin Liv Dis* 6: 497-512, 2002.
21. Theise ND, Schwartz M, Miller C, Thung SN. Macroregenerative nodules and hepatocellular carcinoma in forty-four sequential adult liver explants with cirrhosis. *Hepatology* 16: 949-955, 1992.
22. Tsuda H, Hirohashi S, Shimosato Y, Terada M, Masegawa H. Clonal origin of atypical adenomatous hyperplasia of the liver and clonal identity with hepatocellular carcinoma. *Gastroenterology* 95: 1664-1666, 1988.