

**8TH ANNUAL MEETING
NORTH AMERICAN SOCIETY OF HEAD AND NECK PATHOLOGY
2005 COMPANION MEETING**

TIMELY TOPICS IN HEAD AND NECK PATHOLOGY

Benign Fibro-Osseous Lesions

*Craig B. Fowler, D.D.S., Col, USAF, DC
Department of Oral and Maxillofacial Pathology
Wilford Hall Medical Center
Lackland AFB, Texas*

CLASSIFICATION

I. Osseous Dysplasia

- A. Nonhereditary
 - 1. Periapical Osseous Dysplasia
 - 2. Focal Osseous Dysplasia
 - 3. Florid Osseous Dysplasia
- B. Hereditary
 - 1. Familial Gigantiform Cementoma

II. Fibro-osseous Neoplasms

- A. Conventional Ossifying Fibroma
- B. “Juvenile”, “Active”, or “Aggressive” Forms of Ossifying Fibroma

III. Fibrous Dysplasia

- A. Monostotic Fibrous Dysplasia
- B. Polyostotic Fibrous Dysplasia
- C. Polyostotic Fibrous Dysplasia with endocrinopathy (McCune-Albright)
- D. Craniofacial Fibrous Dysplasia

I. OSSEOUS DYSPLASIA

A. PERIAPICAL OSSEOUS DYSPLASIA

- 1. Keys to Diagnosis:
 - a. Predilection for middle aged black females
 - b. One or more circumscribed lesions in periapical areas of vital teeth
 - c. Painless, nonexpansile, usual location in anterior mandible
 - d. Radiolucent, mixed density (RL with opacities), or radiopaque with lucent rim

- e. Cellular fibrous stroma with woven or lamellar bone and/or oval relatively acellular “cementum-like” calcifications

B. FOCAL OSSEOUS DYSPLASIA

- 1. Keys to Diagnosis:
 - a. Predilection for middle aged black females
 - b. Typically solitary circumscribed lesion
 - c. Painless, nonexpansile, usual location in mandibular molar region, often in edentulous area
 - d. Usually mixed density (RL with opacities)
 - e. Difficult to remove, doesn't separate easily from surrounding bone, resulting in small hemorrhagic gritty fragments
 - f. Thick curvilinear trabeculae of woven and/or lamellar bone and/or oval “cementum-like” calcifications
 - g. Cellular fibrous stroma, more loosely arranged than in ossifying fibroma
 - h. Sinusoid-like vascular spaces adjacent to bony trabeculae, and free hemorrhage

C. FLORID OSSEOUS DYSPLASIA

- 1. Keys to Diagnosis:
 - a. Predilection for middle-aged black females
 - b. Painless, usually nonexpansile, involvement of two or more jaw quadrants
 - c. Multiple confluent lobular radiopaque masses in tooth-bearing areas
 - d. Early lesions show cellular fibrous tissue with trabeculae of woven bone and/or oval “cementum-like” calcifications without inflammation
 - e. Late-stage lesions show acellular, avascular, coalesced sclerotic bony masses
 - f. May be associated with superimposed infection and osteomyelitis
 - g. Sometimes associated with idiopathic bone cavities (simple bone cysts)

D. FAMILIAL GIGANTIFORM CEMENTOMA

- 1. Keys to Diagnosis:
 - a. Autosomal dominant with variable expressivity
 - b. Onset at young age
 - c. No racial predilection
 - d. Multiple quadrant involvement of radiopaque lesions similar to florid osseous dysplasia
 - e. Variable presence of rapidly expansile lesions, especially in anterior mandible

- f. Histologic features similar to other osseous dysplasias

II. FIBROOSSEOUS NEOPLASMS

A. CONVENTIONAL OSSIFYING FIBROMA

1. Keys to Diagnosis:
 - a. Typically solitary lesion, most often in mandible
 - b. Well demarcated radiolucent or mixed density lesion with smooth, often corticated borders
 - c. Maintains round/oval shape as the lesion enlarges (bowing of inferior border of mandible)
 - d. “Shells out” from surrounding bone intact or in large pieces
 - e. Relatively avascular cellular fibrous stroma, often with a storiform pattern
 - f. Retiform bone trabeculae, some with osteoblastic rimming and/or oval “cementum-like” calcifications

B. “JUVENILE”, “ACTIVE”, OR “AGGRESSIVE” FORMS OF OSSIFYING FIBROMA

1. Keys to Diagnosis (trabecular variant):
 - a. Usual onset in childhood or adolescence
 - b. Usually located in jaws with slight predilection for the maxilla
 - c. Well demarcated radiolucent lesion with small opacities or “frosted glass” appearance
 - d. Highly cellular fibrous stroma with “garland-like” strands of cellular osteoid
 - e. Variable presence of clustered multinucleated giant cells
 - f. Variable presence of myxoid areas with cystic degeneration
2. Keys to Diagnosis (psammomatoid variant):
 - a. Majority with onset in childhood or adolescence; however, some in adults.
 - b. Usual location in orbit or paranasal sinuses
 - c. Well demarcated mixed density lesion with loculated radiolucent areas or clouding of sinus
 - d. Highly cellular fibrous stroma often with whorled pattern containing closely packed spherical ossicles resembling psammoma bodies
 - e. Myxoid component with variable presence of thread-like or thorn-shaped calcifications
 - f. Aneurysmal bone cyst-like areas (blood-filled cysts and multinucleated giant cells)

III. CRANIOFACIAL FIBROUS DYSPLASIA

1. Keys to Diagnosis:
 - a. Onset during first and second decades
 - b. Painless enlargement of involved bone(s)
 - c. Typically contiguous involvement of maxillofacial and cranial bones
 - d. "Frosted glass" radiopacity with indistinct borders
 - e. Curvilinear woven bone trabeculae with minimal-to-no osteoblastic rimming in a cellular fibrous stroma blending into surrounding cancellous and cortical bone
 - f. Some lamellar bone formation is acceptable, especially in "mature" lesions; ovoid calcifications are rare

IV. REFERENCES:

1. El-Mofty S. Psammomatoid and trabecular juvenile ossifying fibroma of the craniofacial skeleton: two distinct clinicopathologic entities. *Oral Surg Oral Med Oral Pathol Oral Radiol Endod* 2002;93:296-304.
2. Brannon RB, Fowler CB. Fibro-osseous lesions: a review of current concepts. *Adv Anat Pathol* 2001;8:126-143.
3. Abdelsayed RA, Eversole LR, Singh BS, Scarbrough FE. Gigantiform cementoma: clinicopathologic presentation of 3 cases. *Oral Surg Oral Med Oral Pathol Oral Radiol Endod* 2001;9:438-44.
4. Su L, Weathers DR, Waldron CA. Distinguishing features of focal cemento-osseous dysplasias and cemento-ossifying fibromas. I. A pathologic spectrum of 316 cases. *Oral Surg Oral Med Oral Pathol Oral Radiol Endod* 1997;84:301-309.
5. Su L, Weathers DR, Waldron CA. Distinguishing features of focal cemento-osseous dysplasias and cemento-ossifying fibromas. II. A clinical and radiologic spectrum of 316 cases. *Oral Surg Oral Med Oral Pathol Oral Radiol Endod* 1997;84:540-549.
6. Summerlin D-J, Tomich CE. Focal cemento-osseous dysplasia: a clinicopathologic study of 221 cases. *Oral Surg Oral Med Oral Pathol* 78:611-620, 1994.
7. Waldron CA. Fibro-osseous lesions of the jaws. *J Oral Maxillofac Surg* 51:828-835, 1993.
8. Johnson LC, et al. Juvenile active ossifying fibroma. Its nature, dynamics, and origin. *Acta Otolaryngol* 1991;Suppl 488:1-40.
9. Young SK, et al. Familial gigantiform cementoma: classification and presentation of a large pedigree. *Oral Surg Oral Med Oral Pathol* 68:740-747, 1989.
10. Makek MS. So called "fibro-osseous lesions" of tumorous origin. Biology confronts terminology. *J Cranio-Maxillo-Fac Surg* 1987;15:154-67.
11. Waldron CA. Fibro-osseous lesions of the jaws. *J Oral Maxillofac Surg* 43:249-262, 1985.
12. Eversole LR, Leider AS, Nelson K. Ossifying fibroma: A clinicopathologic study of sixty-four cases. *Oral Surg Oral Med Oral Pathol* 60:505-511, Nov 1985.
13. Margo CE, et al. Psammomatoid (juvenile) ossifying fibroma the orbit. *Ophthalmology* 92:150-159, Jan 1985.
14. Melrose RJ, Abrams AM, Mills BG. Florid osseous dysplasia: A clinical- pathologic study of thirty-four cases. *Oral Surg Oral Med Oral Pathol*. 41:62-82, Jan 1976.
15. Waldron CA, Giansanti JS. Benign fibro-osseous lesions of the jaws: A clinical-radiologic-histologic review of sixty-five cases. Part II. Benign fibro-osseous lesions of periodontal ligament origin. *Oral Surg Oral Med Oral Pathol* 35:340-350, Mar 1973.
16. Waldron CA, Giansanti JS. Benign fibro-osseous lesions of the jaws: A clinical-radiologic-histologic review of sixty-five cases. Part I. Fibrous dysplasia of the jaws. *Oral Surg Oral Med Oral Pathol* 35:190-201, Feb 1973.

Non-Hodgkin's Lymphomas of the Salivary Glands

*Sherrie L. Perkins M.D., Ph.D.
Professor and Director, Hematopathology
University of Utah Health Sciences Center
and ARUP Laboratories
Salt Lake City, Utah*

I. PRIMARY SALIVARY GLAND NHL

Non-Hodgkin lymphoma (NHL) presenting in salivary glands as a primary site of disease is an uncommon lymphoma that may arise from acquired lymphoid tissue within the salivary gland itself or by extension from intra-glandular lymph nodes. Estimated incidence is <5% of all extranodal NHL and approximately 2-5% of all malignancies of salivary glands or 10% of NHL arising in the head and neck. Usually NHL of the salivary gland will present clinically as a slow increase in the size of a salivary gland. More rapid increases in size usually indicate more aggressive lymphomas. Unlike most other NHL, the strong association of salivary gland NHL with autoimmune disorders results in a strong female predominance and age >50years for these lesions. The parotid gland is the most common site of involvement, seen in approximately 70% of cases, but there may be involvement of any major or minor salivary gland (see Table 1), and lymphoma may involve multiple glands.

Table 1: Salivary Gland Involvement by NHL

Parotid	70%
Submandibular	20-25%
Minor salivary glands	5-10%

A. PATHOPHYSIOLOGY

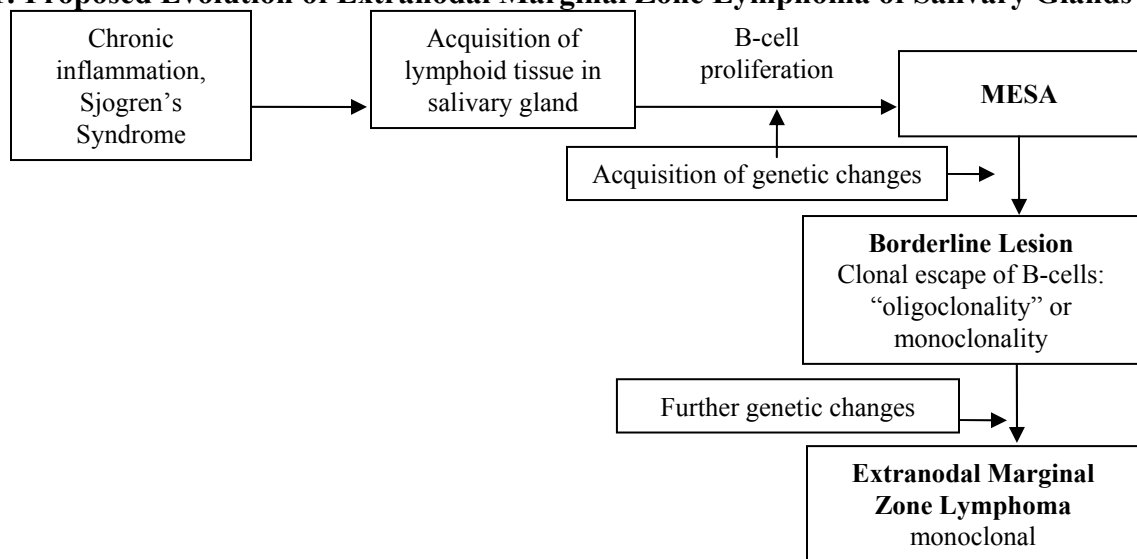
NHL arising in the salivary gland is usually of extranodal marginal zone or MALT (mucosal associated lymphoid tissue) lymphoma type (see Table 2). In order for this type NHL to develop, the salivary gland (which is usually devoid of a significant lymphoid component) must acquire lymphoid tissue secondary to long-standing chronic inflammation (i.e. long-standing sialolithiasis) or, more commonly, secondary to an autoimmune process, such as Sjogren's syndrome.

1. Lymphomas of Salivary Gland
 - a. Extranodal marginal zone lymphoma (MALT lymphoma)
 - b. Nodal lymphomas
 - i. *Follicular lymphoma*
 - ii. *Small lymphocytic lymphoma*
 - iii. *Diffuse large B-cell lymphoma*
 - iv. *Other (T-cell lymphoma, etc.)*

Most extranodal marginal zone lymphomas (EMZL) of the salivary gland arise in patients with Sjogren’s syndrome, and most will have a preceding history of myo-epithelial sialoadenitis (MESA), that is also known as lymphoepithelial sialoadenitis (LESA). Patients with Sjogren’s syndrome and MESA have a 44X increase in the incidence of development of EMZL of the salivary gland. Similarly, patients with MESA and no history of preceding or accompanying Sjogren’s syndrome also have a higher incidence of development of NHL, although the incidence is not well quantified. Development of EMZL of parotid glands has also been described in patients with HIV, hepatitis C and in immunocompetent children (15 cases in the literature). The lesions arising in the background of HIV infection have not been associated with EBV infection, suggesting some other etiologic agent may cause lymphomagenesis in this situation.

The introduction and accumulation of lymphoid tissue from inflammation, chronic infection or autoimmunity is thought to provide the necessary milieu for the development of lymphoma. Chronic immune stimulation will drive proliferation of the lymphoid cells and there may be selection or emergence of one or more dominant B-cell clones. Further genetic changes may eventually lead to clonal escape from control of proliferation and the development of NHL (see Figure 1). In some sites, such as the stomach, where a treatable etiologic agent for immune stimulation may be identified and eradicated (e.g. *Helicobacter pylori*), the decrease in lymphoid growth stimuli and subsequent decrease in proliferation may lead to regression of the lymphoma without classic chemotherapeutic approaches. Unfortunately the etiologic agents in salivary gland EMZL, in particular autoimmune stimulation secondary to Sjogren’s syndrome, are not amenable to this therapeutic approach and are more likely to require conventional therapy rather than responding to modulation of immune stimuli.

Figure 1: Proposed Evolution of Extranodal Marginal Zone Lymphoma of Salivary Glands



II. MESA

MESA is the most important preceding or pre-malignant condition associated with development of EMZL and is hypothesized to be the most common means whereby lymphoid tissue is introduced into the salivary gland and is allowed to persist long enough to allow for development of NHL. MESA is characterized by accumulation of lymphoid tissue, often centering on dilated ducts. Initially the lymphoid infiltrates may be focal and associated with acinar atrophy. The lymphoid tissue usually contains reactive follicles with small, irregular lymphocytes that infiltrate ductal epithelium. At this time the lymphoid infiltrate is composed of polyclonal B-cells and plasma cells with varying numbers of T-cells. Often the T-cell component is quite prominent. As the inflammatory process progresses, the ducts will condense with partial or total loss of the ductal lumina to form myoepithelial islands and subsequent atrophy of the acini as they are replaced by dense lymphoid tissue. To reflect the observation that some of the epithelial islands seen may be strictly of basal epithelial cells, this is also referred to as lymphoepithelial sialoadenitis (LESA) by some authors. All patients with Sjogren's syndrome will have MESA and benign lymphoepithelial lesions, although MESA may also be seen in patients without Sjogren's syndrome. Patients with HIV may have similar morphologic changes with dense lymphoid infiltrates and lymphoepithelial lesions, but are more likely to have cystic dilatation of the salivary ducts.

It is interesting to note that despite an inability to detect monoclonality by immunohistochemical staining, approximately 40% of MESA cases will show evidence of oligoclonality or monoclonality by molecular methods or PCR. This creates a situation in which there is a monoclonal population that is not morphologically NHL. In addition, many cases of MESA that demonstrate monoclonality will not develop into overt lymphoma. These cases have been termed by some authors to be "borderline" lesions or lymphoproliferative processes of uncertain malignant potential.

III. EXTRANODAL MARGINAL ZONE LYMPHOMAS (MALT LYMPHOMAS) OF SALIVARY GLAND

At some point, the lymphoid infiltrates of MESA are thought to acquire sufficient genetic alterations so as to lead to neoplastic or uncontrolled growth as NHL. It should be noted that development of definitive EMZL often involves gradual evolution of morphologic, immunophenotypic and molecular features. Recognition of "borderline" or early lymphoma-like lesions as a part of this spectrum has allowed pathologists and clinicians to be able to deal with lesions that monoclonal yet lack morphologic features of lymphoma, or cases in which malignant features are not well developed. Various criteria have been utilized to define lymphoma, although none is universally accepted. It is perhaps most useful to think of EMZL as part of an evolutionary spectrum of disease with both morphologic as well as determination of clonality by

molecular and immunohistochemical staining play a role in determination of diagnosis. A proposed scheme of classification of lymphoid infiltrates of the salivary gland is presented below (see Table 2).

Table 2: Proposed Classification of Lymphoid Proliferations of Salivary Glands

Benign:	MESA
Borderline lesions:	MESA with haloes of monocytoid B-cells MESA with monoclonal population by PCR
Malignant lesions:	
EMZL	EMZL of MALT type EMZL with extensive plasmacytic differentiation “High grade MALT lymphoma”
Other NHL	

Morphologically EMZL is characterized by diversity of the tumor cells. The tumor will contain a mixture of neoplastic small lymphoid cells, slightly larger cells with irregular nuclear contours (centrocyte-like cells), monocytoid cells with abundant pale cytoplasm, plasma cells and large transformed cells in varying numbers. In some cases plasma cell differentiation may be very prominent, giving rise to consideration of an extramedullary plasmacytoma. The neoplastic plasma cells will contain Dutcher bodies in about 50% of cases. Often distinguishing the precursor MESA from EMZL can be challenging, particularly as these may represent a continuum of disease with gradual evolution of MESA into NHL as well as a polymorphous appearance of the tumor cells. Because of significant morphologic overlap, it may be difficult to diagnose EMZL on the basis of fine needle aspiration, and often tissue excisional biopsy is required unless the FNA provides enough material to allow for ancillary studies such as immunophenotypic analysis for monoclonality or molecular studies.

Usually the first morphologic manifestation of NHL is expansion of the cuff of cells surrounding the myoepithelial islands, forming a halo of centrocyte-like and monocytoid cells. Coalescence of centrocyte-like and monocytoid cells into broad bands or sheets is also a histologic feature that is useful in distinguishing EMZL from MESA. It should be noted that while monocytoid cell haloes and bands are both considered histologic hallmarks of lymphoma, they may be absent in 10-15% of EMZL in the salivary gland and early monocytoid cuffing or haloes may be seen in some cases of MESA. The expansion of neoplastic cells will gradually continue, forming sheets of neoplastic B-cells that invade and replace the reactive follicles that are a prominent feature of MESA. The invasion of the tumor cells into reactive follicles may produce a pronounced nodular appearance of the tumor, leading to confusion with a follicle center cell lymphoma (follicular lymphoma). The tumor cells will also displace and destroy the myoepithelial island epithelium, forming lymphoepithelial lesions (LEL). Destruction of the epithelium may mask the LEL, and keratin stains may be required to identify them. EMZL may

diffusely replace the salivary gland, or may partially involve the gland with retention of the lobular architecture. Dilated ducts may provide a cystic appearance to the lesion, and are seen in about 50% of cases. Histiocytic proliferations and sclerosis are occasionally seen, but are not common features. Epithelioid histiocytes (seen in about 20% of cases) are highly associated with lymphoma rather than a reactive process. Most EMZL will remain localized to the salivary gland, or may involve more than one gland. Lymph node involvement is usually a late occurrence and may involve intra-glandular lymph nodes or adjacent cervical lymph nodes.

Some EMZL lymphomas will show evidence of a high grade transformation with increased numbers of large cells, often forming sheets or masses with a background of more typical low grade EMZL. Specific defining criteria for the diagnosis of large cell transformation or high grade EMZL are not well defined, but sheets of large transformed cells is thought to represent high grade transformation (high grade MALT lymphoma). Although de novo diffuse large B-cell lymphoma (DLBCL) may occur in the salivary gland, a high grade MALT may usually be distinguished from DLBCL by the presence of a low grade EMZL component in addition to the large cell areas. The clinical implication of a diagnosis of high-grade MALT is not clear, but many authors feel that they will not act as aggressively as DLBCL, and may be more likely to remain localized to the salivary gland. However, these patients are more likely to receive systemic chemotherapy due to the aggressive histology.

The immunophenotypic analysis of the tumor may be quite useful in identifying a EMZL, particularly if monoclonality is able to be demonstrated by kappa and lambda staining. It should be kept in mind, however, that there is often a background of polyclonal plasma cells and reactive germinal centers that may provide diagnostic confusion. As with many low grade NHLs, a significant reactive T-cell infiltrate is also often present. The lymphoid infiltrate will have a high proportion of B-cells that stain with B-cell markers such as CD20 and CD79a. The B-cells of EMZL are more likely to co-express CD43 and bcl-2 than are the B-cells of MESA. As noted above, both MESA and EMZL often have a prominent reactive T-cell infiltrate that may make interpretation of bcl-2 and CD43 co-expression difficult, as both these stains will mark reactive T-cells. Reactive germinal centers may be admixed with the neoplastic infiltrate, and these will be negative for bcl-2 stains. The neoplastic B-cells will not co-express CD5 or CD10 (see Table 4), although rare cases of EMZL have been described that show an unusual pattern of nuclear staining with CD10 if a t(11;18) is present.

Table 3: Immunophenotypic Profiles for Salivary Gland Lymphoid Infiltrates

	CD20	CD43 co-expression	CD5 co-expression	CD10 co-expression	bcl-2 co-expression	Monoclonal light chains
MESA	+	-	-	-	-	-
EMZL	+	+	-	_***	+*	+
Follicular Lymphoma	+	-	-	+	+(neoplastic follicles)	+
SLL	+	+	+	-	+	+

* May be negative in reactive follicles

** Some cases may show nuclear CD10 staining

MESA = Myoepithelial sialoadenitis

EMZL = Extranodal marginal zone lymphoma

SLL = Small lymphocytic lymphoma

Molecular analysis of EMZL usually shows a monoclonal rearrangement of both heavy and light chain immunoglobulin genes (reported in 60-90% of cases, dependent on study and primers used). As discussed above, MESA may show evidence of oligoclonality or monoclonality, suggesting that monoclonal populations may arise within this process and eventually emerge in the development of frank NHL. Clearly dependence on demonstration of a monoclonal population by molecular methods is not, by itself, sufficient to make a diagnosis of NHL in this setting.

Cytogenetic analysis has identified 2 different cytogenetic abnormalities that are associated with marginal zone lymphomas at extranodal sites. These include the t(14;18)(q32;q21) translocation that juxtaposes the MALT1 gene with IGH that is seen in about 20% of salivary gland EMZL. Another translocation, t(11;18)(q21;q21) is also seen in extranodal EMZL and causes fusion of the API2 (apoptosis inhibitor-2) gene to the MALT1 gene that is strongly associated with gastric MALT lymphomas and is rare in salivary gland tumors. Often tumors with the t(14;18)(q32;q21) will have additional cytogenetic abnormalities, such as trisomy 3 or trisomy 18, and quite complex karyotypes.

Clinical behavior of EMZL of the salivary gland is variable, but is considered to be low grade. Most often EMZL will remain localized to the salivary gland, often for many years. Dissemination may be to regional (intra-parotid or cervical) lymph nodes or to other mucosal sites including lung, conjunctiva or stomach, suggesting a possible mucosal homing pattern. Bone marrow involvement is rare.

Treatment of primary EMZL of salivary glands is variable and based on extent of disease as well as clinician preferences. Some patients may receive multi-agent chemotherapy, often with associated Rituximab (anti CD20). Other patients may be treated with surgical removal or

localized radiotherapy and watchful waiting, particularly if there is no involvement of adjacent lymph nodes or other sites. Most EMZL of salivary glands are considered indolent and have a prolonged clinical course. Many patients will receive minimal therapy and do well. However, it should be noted that some patients will die of EMZL.

IV. OTHER SALIVARY GLAND LYMPHOMAS

Other NHL seen in the salivary glands usually arise in lymph nodes adjacent to or embedded within the gland and extend into the glandular parenchyma. These are typically low-grade B-cell lymphomas such as follicular lymphoma and small lymphocytic lymphoma (SLL), with follicular lymphomas being the most commonly reported. It is important to recognize these other entities as the natural history of the disease is quite different than that of EMZL. Most often these will represent systemic diseases and transformation is a clearly defined adverse prognostic factor. These lymphomas are typically seen in patients without antecedent history of MESA or Sjogren's syndrome. Thus, the absence of MESA or LEL in remaining salivary gland is a helpful feature in identifying secondary involvement of a salivary gland by NHL. Also, most other low-grade lymphomas are characterized by more morphologic uniformity that is characteristic in EMZL. Immunohistochemical studies are also a useful adjunct to morphology in identifying non-EMZL processes in the salivary glands. As noted above, EMZL will typically have a characteristic CD5-, CD10- B-cell phenotype with co-expression of CD43 and bcl-2. In contrast, follicular lymphomas will express CD10 and bcl-2 while lacking CD5 and CD43 while SLL will express CD5, CD43 and bcl-2 while lacking CD10 (see Table 4). Rarely low-grade lymphomas, in particular follicular lymphomas, may arise in the lymphoid tissue of Warthin's tumors. The clinical course of these other B-cell lymphomas in salivary glands is identical to that of primary nodal disease of the same subtype.

High-grade lymphomas, such as diffuse large B-cell lymphoma or Burkitt lymphoma, have been described to involve salivary glands, usually as part of a spectrum of widespread disease. The most commonly seen high-grade morphology is that of diffuse large B-cell lymphoma, and it is important to distinguish from high grade MALT by features of lack of a low grade EMZL component or LEL.

Most NHL of the salivary glands is of B-cell phenotype, however case reports of primary T-cell lymphomas involving the salivary glands are in the literature (approximately 14 cases). Many T-cell lymphomas of the salivary gland have a T/natural killer phenotype, are seen primarily in Oriental patients and are associated with EBV infection (>50% of tumors positive). A few CD30 positive anaplastic large cell lymphomas have also been reported. The outcome for T-cell lymphomas involving the salivary gland is variable, but many have an aggressive clinical course. There is no association with preceding sialoadenitis in T-cell lymphoma cases.

V. CONCLUSIONS

Primary NHL of the salivary glands is usually EMZL or MALT-type lymphomas. These neoplasms arise in the milieu of acquired lymphoid tissue associated with chronic inflammation, autoimmunity or infection. The most common precursor lesion is MESA. The development of EMZL occurs as part of a spectrum of lymphoid lesions that include MESA, borderline lesions and lymphoma requiring integration of morphologic, immunohistochemical and molecular testing to define the disease process.

Other NHL may also involve the salivary glands but are usually a result of extension of disease from adjacent lymph nodes and a manifestation of systemic disease. These other lymphomas are important to identify as they have a different natural history than salivary gland EMZL and may require different approaches to therapy. Morphologic features, immunophenotype and molecular findings will help to identify these other types of NHL.

VI. REFERENCES

1. Abbodanzo SL. Extranodal marginal-zone B-cell lymphoma of the salivary gland. *Ann Diagnost Pathol* 5:264-254, 2001.
2. Ambrosetti A, Zanoetti R, Pattaro, C, et al. Most cases of primary salivary mucosa-associated lymphoid tissue lymphoma are associated with either Sjogren syndrome or hepatitis C virus infection. *Br J Haematol* 126:43-49, 2004.
3. Barnes L, Meyer EN, Prokopakis EP. Primary malignant lymphoma of the salivary glands. *Arch Otolaryngol Head Neck Surg* 124:573-577, 1998.
4. Chan JK, Tsang WY, Hui PK, et al. T-and T/natural killer-cell lymphomas of the salivary gland: a clinicopathologic, immunohistochemical and molecular study of six cases. *Hum Pathol* 28:238-246, 1997.
5. Chen CC, Rialow RB, Sonmez-Alpan E, Swerdlow SH. Classification of small B-cell lymphoid lesions using a paraffin section immunohistochemistry panel. *Appl Immunohistochemistry and Molec Meth* 8:1-13, 2000.
6. Cohen EG, Patel SG, Lin O, et al. Fine-needle aspiration biopsy of salivary gland lesions in a selected patient population. *Arch Otolaryngol Head Neck Surg* 130:773-778, 2004.
7. Dierlamm J, Wlodarska I, Michaux L, et al. Genetic abnormalities in marginal zone lymphomas. *Hematol Oncol* 18:1-9, 2000.
8. Diss TC, Wotherspoon AC, Speight P, et al. B-cell monoclonality, Epstein-Barr virus and t(14;18) in myoepithelial sialoadenitis and low grade B-cell MALT lymphoma of the parotid gland. *Am J Surg Pathol* 19:531-539, 1995.
9. Du M, Diss TC, Xu C, et al. Ongoing mutation on MALT lymphoma immunoglobulin gene suggests that antigen stimulation plays a role in clonal expansion. *Leukemia* 10:1190-1197, 1996.
10. Harris NL, Jaffe ES, Stein H, Vardiman JW. Pathology and Genetics of the Haematopietic and Lymphoid Tissues. WHO Classification of Tumors. IARC Press, Lyon, 2001.
11. Harris NL. Lymphoid proliferations of the salivary gland. *Am J Clin Pathol* 111:S94-S103, 1999.
12. Hew WSR, Carey FA, Kernohan NM, et al. Primary T-cell lymphoma of salivary gland: a report of a case and review of the literature. *J Clin Pathol* 55:61-63, 2002.
13. Hsi ED, Zuckerberg LR, Schnitzer B, Harris NL. Development of extrasalivary gland lymphoma in myoepithelial sialoadenitis. *Mod Pathol* 8:817-821, 1995.

14. His ED, Siddiqui J, Snitzer B, et al. Analysis of immunoglobulin gene heavy chain rearrangements in myoepithelial sialoadenitis by polymerase chain reaction. *Am J Clin Pathol* 106:498-503, 1996.
15. Hyjek E, Smith WJ, Issacson PG. Primary B-cell lymphoma of salivary glands and its relationship to myoepithelial sialoadenitis. *Hum Pathol* 19:766-776, 1988
16. Jaehne M, Ubmuller J, Jakel KT, Zscharber R. The clinical presentation of non-Hodgkin lymphomas of the major salivary glands. *Acta Otolaryngol* 121:647-651, 2001.
17. Jaffe ES. Lymphoid lesions of the head and neck: a model of lymphocyte homing and lymphomagenesis. *Mod Pathol* 15:255-263, 2002.
18. Joshi VV, Gagnon GA, Chadwick EG, et al. The spectrum of mucosa-associated lymphoid tissue lesions in pediatric patients infected with HIV: A clinicopathologic study of six cases. *Am J Clin Pathol* 107:592-599, 1997.
19. Yuen A, Jacobs C. Lymphomas of the head and neck. *Semin Oncol* 26:338-345, 1999.
20. Kato K, Oshima K, Shiokawa S, et al. Rearrangement of immunoglobulin heavy and light chains and VH family in thyroid and salivary gland lymphomas. *Pathol International* 52:747-754, 2002.
21. Kojima M, Nakamura S., Ichimura K, et al. Follicular lymphoma of the salivary gland. A clinicopathological and molecular study of six cases. *Int J Surg Pathol* 9:287-293, 2001.
22. Liu H, Ye H, Dogan A, et al. T(11;18)(q21;q21) is associated with advanced mucosa-associated lymphoid tissue lymphoma that expresses nuclear BCL-10. *blood* 98:1182-1187, 2001.
23. Malek SN, Hatfield AJ, Flinn IW. MALT lymphomas. *Curr Treat Options Oncol* 4:269-279, 2003.
24. Mo JQ, Dimashkieh H, Mallery SR, Swerdlow SH, Bove KE. MALT lymphoma in children: case report and review of the literature. *Pediatr Develop Pathol* 7:407-413, 2004.
25. Remstein ED, James CD, Kurtin PJ. Incidence and subtype of Api2-MALT1 fusion translocations in extranodal, nodal and splenic marginal zone lymphomas. *Am J Pathol* 156:1183-1190, 2000.
26. Simpson RHW, Sarsfield PTL. Benign and malignant lymphoid lesions of the salivary glands. *Curr Diagnostic Pathol* 4:91-101, 1997.
27. Steubel B, Lamprecht A, Dierlamm J, et al. T(14;18)(q32;q21) involving IGH and MALT1 is a frequent chromosomal aberration in MALT lymphoma. *Blood* 101:2335-2339, 2003.
28. Wolvius EB, van der Valk P, van der Wal JE, et al. Primary non-Hodgkins lymphoma of the salivary glands. An analysis of 22 cases. *J Oral Pathol Med* 25:177-181, 1996.
29. Ye H, Dogan A, Karran L, et al. BCL10 expression in normal and neoplastic lymphoid tissue. Nuclear localization in MALT lymphoma. *Am J Pathol* 157:1147-1154, 2000.
30. Zucca E, Conconi A, Roggero E, et al. Non-gastric MALT lymphomas: a survey of 369 European patients: The International Lymphoma Study Group. *Ann Oncol* 11:89-95, 2000.

Fine-Needle Aspiration Cytology of Salivary Gland Neoplasms

*Lester J. Layfield, M.D.
Professor and Chief, Surgical Pathology
University of Utah Health Sciences Center
Salt Lake City, Utah*

INTRODUCTION:

The salivary gland is the site of origin for a wide variety of benign and malignant neoplasms. These neoplasms present a varied but overlapping array of morphologic features resulting in a large number of difficult sets of differential diagnoses both histopathologically and cytologically. While architecture and circumscription are frequently helpful in the histopathologic differential diagnosis of salivary gland neoplasms, these clues are usually lacking in small biopsy specimens and cytologic preparations. Hence, fine-needle aspiration (FNA) cytology may fail to render a specific diagnosis despite abundant material. Regardless of this handicap, fine-needle aspiration remains an important diagnostic method for the workup of many salivary gland lesions. Reported diagnostic accuracy for fine-needle aspiration of the salivary glands has varied. Sensitivity has ranged from 73% to 88% and specificity from 90% to 100%. Certain neoplasms appear to be responsible for the majority of diagnostic errors. Mucoepidermoid carcinoma, monomorphic adenoma and adenoid cystic carcinoma appear to be the lesions most often associated with erroneous diagnoses. When appropriately used, FNA can reduce operative procedures on the salivary glands by one-third.

Because a large number of neoplasms occur within the salivary gland, and many of these have overlapping morphologies, a structured approach to the diagnosis of salivary gland neoplasms is recommended. Because benign mixed tumors (pleomorphic adenomas) comprise 60-70% of all parotid neoplasms and 40-60% of all submandibular gland tumors, one should first decide whether a smear specimen obtained from a salivary gland lesion is or is not a benign mixed tumor. Similarly, because of the relatively high frequency of Warthin's tumors and their characteristic cytomorphologic pattern, these neoplasms should be excluded before the systematic approach based on most prominent cytomorphologic feature is begun.

For differential diagnostic purposes, cytomorphologic patterns can be divided into the following categories:

1. Smears containing a prominence of cores or cords of stromal material.
2. Smears with a prominence of lymphoid cells.
3. Smears containing a prominent population of epidermoid epithelial cells.
4. Clear, granular or foamy cell-containing lesions.
5. Cystic lesions.

I. PLEOMORPHIC ADENOMA:

Pleomorphic adenomas are the most frequently aspirated lesion of the parotid salivary glands. Smears are usually cellular and contain an abundant admixture of stromal and cellular components. At times the myxoid-chondroid stroma is so abundant that it interferes with staining and visualization of the cellular component.

Diagnostic criteria for pleomorphic adenoma are:

1. Variable mixture of stroma, myoepithelial and epithelial components.
2. Stroma has myxoid-chondroid appearance that may appear feathery in air-dried or H&E-stained material.
3. Epithelial cells have small bland nuclei.
4. A squamous element may be present, and if the pleomorphic adenoma is infarcted may have an atypical appearance.
5. Some neoplasms may be predominantly cellular with only tiny amounts of stroma.

The vast majority of mixed tumors are benign, but rare malignant mixed tumors occur. These are characterized by marked atypia in the epithelial component which may have the appearance of adenocarcinoma. At times other subtypes of carcinomas may be present in examples of malignant mixed tumors. Malignant mixed tumors may also contain a chondrosarcomatous or osteosarcomatous component.

II. WARTHIN'S TUMOR:

Warthin's tumors are characterized by a grossly doughy consistency and characteristically occur in the elderly. Aspiration of these lesions will often contain a drop of cloudy fluid. Warthin's tumors may be bilateral.

Diagnostic criteria for Warthin's tumors include:

1. Classic three-component smear characterized by
 - a. Dirty proteinaceous background.
 - b. Population of small mature lymphocytes.
 - c. Small clusters and sheets of oncocytic epithelial cells.

Separation of Warthin's tumor from oncocytoma depends on the recognition of the three components within a smear. The epithelial cell component of Warthin's tumor and oncocytoma may be identical.

III. CHRONIC SIALADENITIS:

While chronic sialadenitis is not a neoplasm it often presents as a firm nodule involving all or a component of the salivary gland. Diagnostically, it is most problematic when occurring

in the submandibular gland, especially following radiation therapy for oral squamous cell carcinoma.

Diagnostic criteria for chronic sialadenitis are:

1. Scattered lymphocytes usually present in small numbers.
2. Tight clusters of epithelial cells with sharp cookie cutter-like edges.
3. The nuclear to cytoplasmic ratio is often high but the nuclei are relatively small and dark.
4. Cell clusters have smooth borders.

IV. SALIVARY GLAND LESIONS CHARACTERIZED BY A PROMINENCE OF SQUAMOUS OR EPIDERMOID CELLS:

An important diagnostic category of salivary gland lesions is those lesions characterized by a prominent and at times predominant number of epidermoid or squamous epithelial cells. Lesions with such an appearance include Warthin's tumors, infarcted Warthin's tumors, chronic sialadenitis, mucoepidermoid carcinomas, lymphoepithelial cysts and metastatic or primary squamous cell carcinomas of the salivary gland.

V. INFARCTED PLEOMORPHIC ADENOMA:

Occasional pleomorphic adenomas will undergo spontaneous infarction, but more often infarction of pleomorphic adenoma occurs subsequent to fine-needle aspiration or other operative procedure/trauma. Infarcted pleomorphic adenomas are characterized by:

1. A prominent amount of necrotic debris which may obscure cellular detail.
2. Reactive-appearing squamous cells.
3. Fragments of granulation tissue.
4. Frequently fragments of classic pleomorphic adenoma are found in other aspirates taken near the periphery of the lesion.

VI. MUCOEPIDERMOID CARCINOMA:

Mucoepidermoid carcinomas are cytologically divided into low grade and high grade forms. While the low grade form is cystic and cytologically characterized by intermediate cells, mucin-containing cells and a mucoid background substance, the high grade carcinomas contain a recognizable component of epidermoid cells. While many of these cells are clearly epidermoid in differentiation, the majority of cases will not show definitive keratinization and do not show keratin pearl formation. High grade mucoepidermoid carcinomas are characterized by:

1. Intermediate cells.
2. Atypical epidermoid cells.
3. Some cells contain intracytoplasmic mucin positive with PAS.
4. Nuclear atypia may be significant, consistent with a high grade carcinoma.

VII. SQUAMOUS CELL CARCINOMA:

While the majority of squamous cell carcinomas involving the parotid gland are metastatic, occasional primary squamous cell carcinomas of the parotid occur. It is impossible to cytologically distinguish between primary and secondary squamous carcinomas of the salivary gland. Squamous cell carcinomas occurring within the salivary gland are characterized by:

1. Aspirates are usually of high cellularity.
2. Immature and atypical squamous cells are invariably present.
3. Anucleate and keratinizing squamous cells may be seen.
4. Nuclear atypia is usually present.

VIII. LYMPHOCYTE-RICH LESIONS:

Salivary gland lesions in which there is a prominent if not predominant population of lymphocytes are relatively common. These lesions range from contamination of salivary gland aspirates by normal structures (intraparotid lymph nodes) to high grade lymphomas.

The differential diagnosis of a lymphocyte-rich smear from the salivary gland includes:

1. Intraparotid lymph node.
2. Benign lymphoepithelial lesion.
3. Warthin's tumor.
4. Lymphoepithelial cyst.
5. Primary lymphoma of a parotid lymph node.

Intraparotid lymph nodes are common and are intimately associated with the parotid glands. Because of this close association, hyperplastic intraparotid lymph nodes are commonly aspirated to exclude a salivary gland neoplasm.

Diagnostic criteria for an intraparotid lymph node include:

1. A mixed lymphoid infiltrate with a sequential range of maturation.
2. Relatively pure population of lymphoid cells.
3. Tingible body macrophages present.

IX. BENIGN LYMPHOEPITHELIAL CYST:

Benign lymphoepithelial cysts most commonly occur in immunocompromised individuals. The occurrence of these lesions is relatively common in patients infected with HIV but similar changes can be seen in immunosuppressed patients secondary to therapeutic immunosuppression associated with bone marrow transplantation or solid organ transplants.

Diagnostic criteria for benign lymphoepithelial cyst include:

1. A small amount of watery fluid in aspirated material.
2. A moderately cellular population of lymphocytes with a mixed appearance showing an orderly maturational sequence.

3. Scanty population of epithelial cells which may be squamous, columnar or mucoepidermoid in appearance.

X. BENIGN LYMPHOEPITHELIAL LESION:

Benign lymphoepithelial lesions are a component of Sjögren's syndrome.

Diagnostic criteria for benign lymphoepithelial lesions include:

1. A mixed population of lymphocytes with an orderly maturational sequence and lymphoglandular bodies in the background.
2. Epithelial/myoepithelial islands (aggregates of epithelioid cells).

XI. PRIMARY PAROTID LYMPHOMA:

Primary parotid lymphomas are relatively rare lesions and are usually of B-cell lineage, as the parotid gland is part of the mucosal-associated lymphoid tissue system.

Diagnostic criteria for primary parotid lymphoma include:

1. A monomorphous lymphoid population.
2. Lymphoglandular bodies in the background.
3. Lymphoid cells may appear atypical and enlarged.
4. Monoclonality by immunocytochemistry or flow cytometry.

XII. WARTHIN'S TUMOR:

Smears from Warthin's tumors may be dominated by a mixed lymphoid population. This population is often dominated by small mature lymphocytes. Within the population of small mature lymphocytes, numbers of sheets and clusters of oncocytic epithelial cells are scattered. The background has a dirty proteinaceous appearance.

XIII. CLEAR CELL LESIONS:

A variety of salivary gland lesions and metastases to the salivary gland may contain a population of epithelial cells with predominantly vacuolated or clear cytoplasm. Most of these lesions are uncommon, including the rare clear cell oncocytoma. Other clear cell lesions include:

1. Some examples of acinic cell neoplasms.
2. Mucoepidermoid carcinoma (low grade).
3. Primary clear cell carcinoma of the salivary gland.
4. Some examples of epithelial/myoepithelial carcinoma of the salivary gland.
5. Metastatic renal cell carcinoma.

XIV. ACINIC CELL NEOPLASM:

Acinic cell neoplasms are relatively infrequent but represent an important category in salivary gland neoplasia.

Diagnostic criteria for acinic cell carcinoma are:

1. Abundant cellular material in a clean background.
2. Cohesive clusters and sheets of cells.
3. Cells have a foamy, granular, vacuolated or clear cytoplasm.
4. Mildly atypical cells with variation in nuclear size are present. Marked nuclear pleomorphism is not seen.
5. The cytoplasm often contains red-purple granules in at least a small component of the cells. These granules are only seen in Romanowsky stained material.

XV. PRIMARY CLEAR CELL CARCINOMA:

Primary clear cell carcinomas of the salivary gland are uncommon neoplasms. They are characterized by:

1. Moderately abundant cellular material.
2. Single cells and clusters of cells.
3. Moderate nuclear atypia.
4. Abundant clear cytoplasm as seen on Papanicolaou and H&E stains. Air-dried material has a granular appearance to the cytoplasm.

XVI. METASTATIC RENAL CELL CARCINOMA:

Diagnostic criteria for metastatic renal cell carcinoma include:

1. Abundant cellular material.
2. Large cells with clear or granular cytoplasm. Cell population is often mixed.
3. Variable degrees of nuclear atypia.
4. Bloody background which may contain necrotic debris.
5. History or radiographic evidence of a renal primary.

XVII. STROMAL PROMINENT LESIONS:

Differential diagnosis of smears containing a prominent stromal component includes monomorphic adenoma, adenoid cystic carcinoma, epithelial myoepithelial carcinoma. The differential diagnosis between these lesions is important, as monomorphic adenomas are entirely benign and may be removed by limited excision, whereas adenoid cystic carcinomas often require a nerve procedure. Monomorphic adenomas are characterized by:

1. A large population of small uniform cells often forming 3-D clusters.
2. Variable amounts of hyaline or mauve stroma in course cords or globules.
3. Individual cells usually have scanty to modest amounts of cytoplasm and bland nuclei.
4. Some examples have individual cells and small sheets of cells.

5. Monomorphic adenomas are clinically painless with no evidence of nerve dysfunction.

XVIII. ADENOID CYSTIC CARCINOMA:

Smears are characterized by moderate to abundant material. The smears vary in appearance according to the subtype of adenoid cystic carcinoma present. Solid adenoid cystic carcinomas contain little stromal material and have a relatively small basaloid appearance with hyperchromatic nuclei. The characteristic cylindromatous picture is most distinctive, in which one finds rings of cells around central spheres of homogeneous waxy stroma. Separation from monomorphic adenoma and some pleomorphic adenomas may be difficult. A clinical history of nerve dysfunction or pain favors the diagnosis of adenoid cystic carcinoma. In addition, the stroma in adenoid cystic carcinomas is more solid and waxy than the stroma commonly seen in monomorphic adenomas. Adenoid cystic carcinoma cell nuclei are usually slightly larger than those seen in monomorphic adenomas, but distinction based purely on nuclear size is very difficult.

XIX. MYOEPITHELIAL EPITHELIAL CARCINOMA:

Diagnostic criteria are as follows:

1. Abundant cellular material.
2. Biphasic cell population.
3. Balls of cells with central pale core.
4. Naked myoepithelial cell nuclei in the background.
5. Cell aggregates composed of small dark epithelial cells and larger clear myoepithelial cells.

XX. CYSTIC LESIONS:

Cystic lesions of the salivary glands and salivary gland area include branchial cleft cysts, epidermal inclusion cysts, pilomatrixoma, Warthin's tumor, cystic pleomorphic adenoma, lymphoepithelial cyst and squamous cell carcinoma, acanthotic type. FNA of a pilomatrixoma can lead to the inappropriate diagnosis of solid adenoid cystic carcinoma or monomorphic adenoma. Pilomatrixomas occur within the dermis of the face and may overlie the salivary gland area causing diagnostic confusion. Careful palpation will usually reveal that the skin tumor is separate from the underlying salivary gland.

XXI. BRANCHIAL CLEFT CYST:

Branchial cleft cysts may lie within the upper neck and be confused with a salivary gland lesion. Diagnostic criteria for branchial cleft cyst include:

1. Squamous epithelium, usually of a mature appearance is most common but columnar epithelium may be found.
2. Anucleate squamous.
3. Dirty brown fluid containing macrophages.
4. Scanty lymphoid component which is mature in appearance and often composed of small mature lymphocytes.

XXII. CYSTADENOMA:

Diagnostic criteria of cystadenoma:

1. Background mucus.
2. Bland columnar mucus-containing cells.
3. Lack of intermediate or squamous epithelial cells.
4. Muciphages with abundant cytoplasm.

XXIII. CYSTADENOCARCINOMA:

Cystadenocarcinomas rarely occur within the salivary glands but these lesions may undergo needle aspiration leading to smears containing a mucoïd to watery fluid.

Diagnostic criteria include:

1. Background mucin.
2. Atypical columnar cells and cuboidal cells containing mucin.
3. Lack of intermediate and squamous cells helps to exclude mucoepidermoid carcinoma.

XXIV. MUCOEPIDERMOID CARCINOMAS:

Mucoepidermoid carcinomas must be considered in the differential diagnosis of cystic lesions in that low grade mucoepidermoid carcinoma may yield abundant watery to mucoïd fluid. When of low cellularity, they can be confused with a mucus retention reaction/mucocele. When no cellular component is identified, such smears are more consistent with a mucus retention reaction, but a mucoepidermoid carcinoma can never be entirely excluded on a cytologic basis due to sampling issues.

Polymorphous Low-Grade Adenocarcinoma: Diagnosis And Controversies

*Gary L. Ellis, D.D.S.
Director, Oral and Maxillofacial Pathology
Centers of Excellence
ARUP Laboratories
Salt Lake City, Utah*

I. FIRST REPORTS

- Freedman PD, Lumerman H: Lobular carcinoma of intraoral minor salivary glands. Oral Surg Oral Med Oral Pathol 1983;56:157-165.
- Batsakis JG, Pinkston GR, Luna MA, Byers RM, Sciubba JJ, Tillery GW: Adenocarcinoma of the oral cavity: a clinicopathologic study of terminal duct carcinomas. J Laryngol Otol 1983;97:825-835.
- Evans HL, Batsakis JG: Polymorphous low-grade adenocarcinoma of minor salivary glands: a study of 14 cases of a distinctive neoplasm. Cancer 1984;53:935-942.

II. SYNONYMS

1. Terminal duct carcinoma
2. Lobular carcinoma
3. Prior to 1984 called? Adenocarcinoma, NOS

III. CHARACTERISTIC HISTOPATHOLOGY

A. BLAND CYTOLOGIC FEATURES

1. Uniform cell and nuclear size
2. Uniform, lightly stained, round to oval nuclei
3. Small nucleoli
4. Few or no mitotic figures

B. VARIETY OF GROWTH PATTERNS – EVEN WITHIN SAME TUMOR

1. Solid
2. Cribriform
3. Tubular
4. Hyalinized
5. Thin cords
6. Cyclonic

C. INFILTRATION

1. Frequent perineural growth
2. Does a papillary pattern exist and, if so, is it diagnostically important?

Confusing!

- Mills SE, Garland TA, Allen MS: Low-grade papillary adenocarcinoma of palatal salivary gland origin. Am J Surg Pathol 1985;8:367-374.

- Evans HL, Luna MA: Polymorphous low-grade adenocarcinoma: a study of 40 cases with long-term follow up and an evaluation of the importance of papillary areas. Am J Surg Pathol 2000;24:1319-1328.

Table 1.

Significant papillary areas	42%
Recurrence	32%
Lymph node metastases	15%
Distant metastases	7.5%
Death rate	12.5%

3. Correlations

- Papillary growth with lymph node metastases
- Positive surgical margins with local recurrence
- No correlation with survival
 - Castle JT, Thompson LD, Frommelt RA, Wenig BM, Kessler HP. Polymorphous low-grade adenocarcinoma: a clinicopathologic study of 164 cases. Cancer 1999;86:207-219

Table 2.

Largest series in literature	
No papillary configurations	
Recurrence rate	9%
Metastatic rate	1%
Death rate	1%

4. My thoughts

- Mills et al.'s Low-grade papillary adenocarcinoma of palatal salivary gland origin is not PLGA.

I prefer to classify it as Papillary Cystadenocarcinoma

Figure 1. Patients' Age Distribution for Polymorphous Low-grade Adenocarcinoma

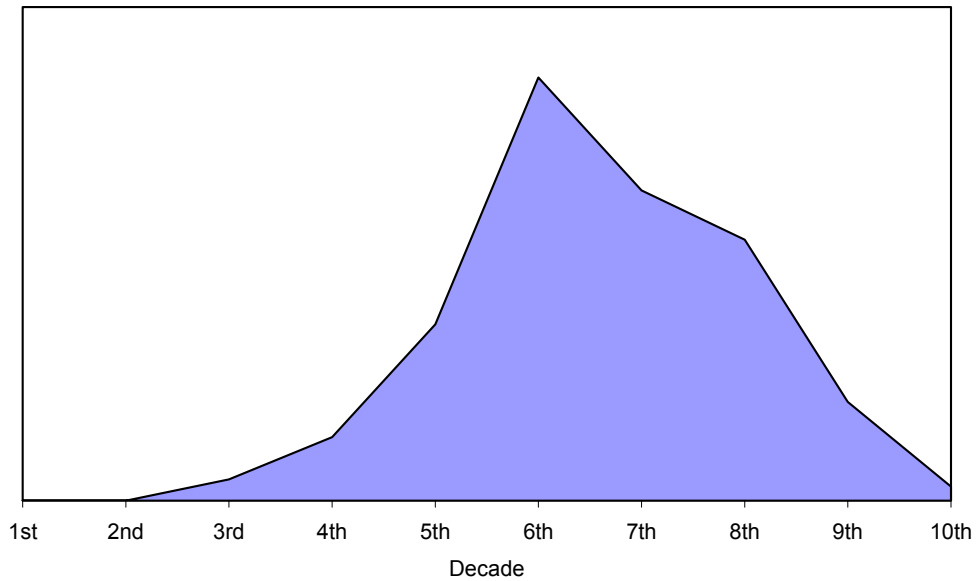


Figure 2. Sites of Occurrence

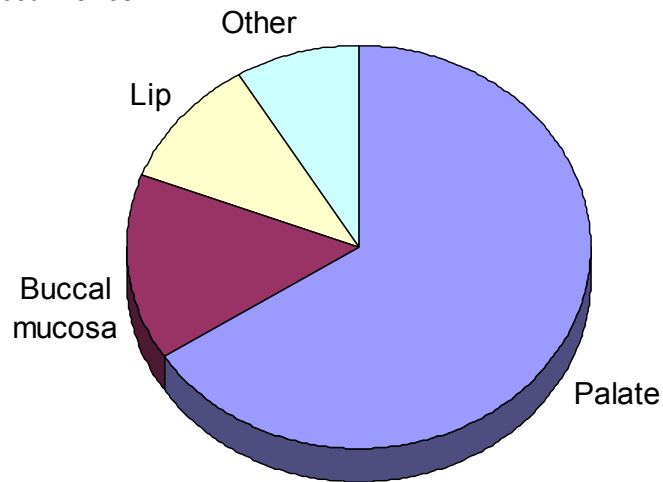
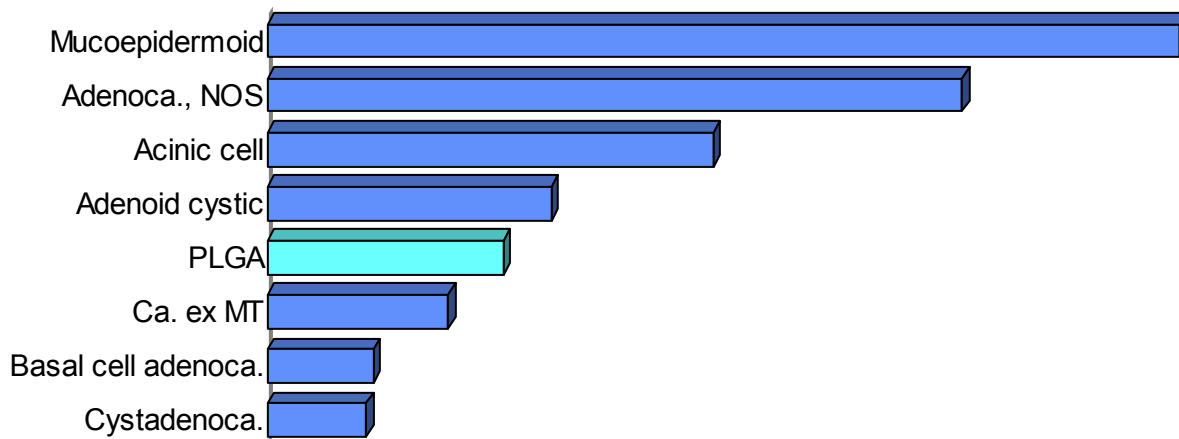


Figure 3. Relative Incidence



D. DIFFERENTIAL DIAGNOSIS

1. Adenoid Cystic Carcinoma
2. Pleomorphic Adenoma

IV. ADENOID CYSTIC CARCINOMA

A. CHARACTERIZED BY:

1. Ductal and myoepithelial differentiation
2. Clear cytoplasm and angular, hyperchromatic nuclei

B. HISTOLOGIC TYPES

1. Cribriform
2. Tubular
3. Solid

C. BIOLOGIC BEHAVIOR

1. 5-year survival
 - a. Cribriform/tubular ~ 90%
 - b. Solid type ~ 45%
2. 15-year survival
 - a. Cribriform/tubular ~ 45%
 - b. Solid type ~ 5%

Figure 4. Immunohistochemistry

	Ker	SMA	S100	P63	GFAP	C-kit
PLGA	+++	-/+	++	++	-/+	+
ACC	++	++	+++	+++	+/-	+++

Ker = cytokeratin
 SMA = smooth muscle actin
 GFAP = glial fibrillary acidic protein

Figure 5. Patients' Age Distribution for Adenoid Cystic Carcinoma

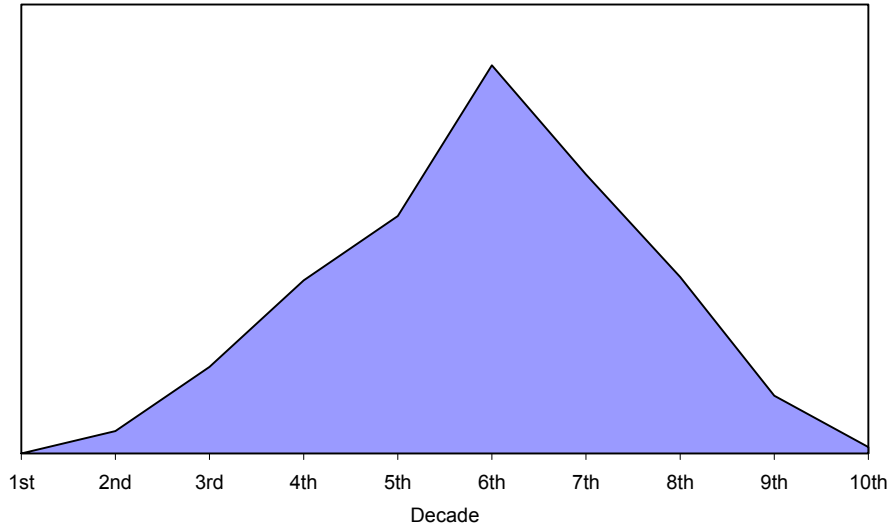
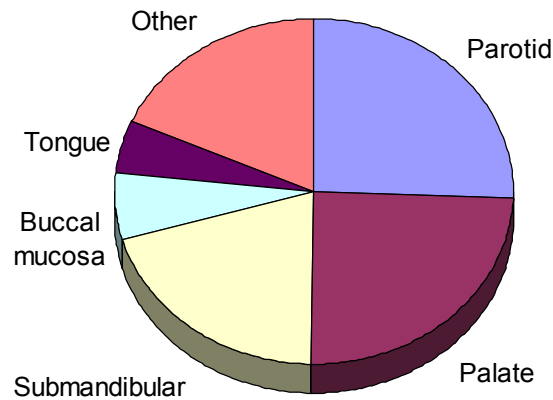


Figure 6. Sites of Occurrence



V. PLEOMORPHIC ADENOMA

A. HISTOLOGIC FEATURES

1. Multiple growth patterns: most diverse of any neoplasm
2. Myxochondroid areas
3. Bland cytologic features

4. Combinations of ductal cells and epithelioid, spindled, and plasmacytoid myoepithelial cells
5. No invasion: major gland tumors usually encapsulated, but minor gland tumors often unencapsulated
6. Usually strongly immunoreactive for GFAP, S100 protein, cytokeratin, and p63, and often reactive for SMA

Figure 7. Immunohistochemistry

	Ker	SMA	S100	P63	GFAP	Calponin
PLGA	+++	-/+	++	++	-/+	-/+
PA	++	++	+++	+++	+++	++

Ker = cytokeratin

SMA = smooth muscle actin

GFAP = glial fibrillary acidic protein

B. BIOLOGIC BEHAVIOR

1. Near zero recurrences when excised with 1 cm margins around tumors
2. High recurrence rate when enucleated or surgically incised before removal
3. 6 to 8% rate of malignant transformation; longer duration increases risk of transformation

Figure 8. Patients' Age Distribution for Pleomorphic Adenoma

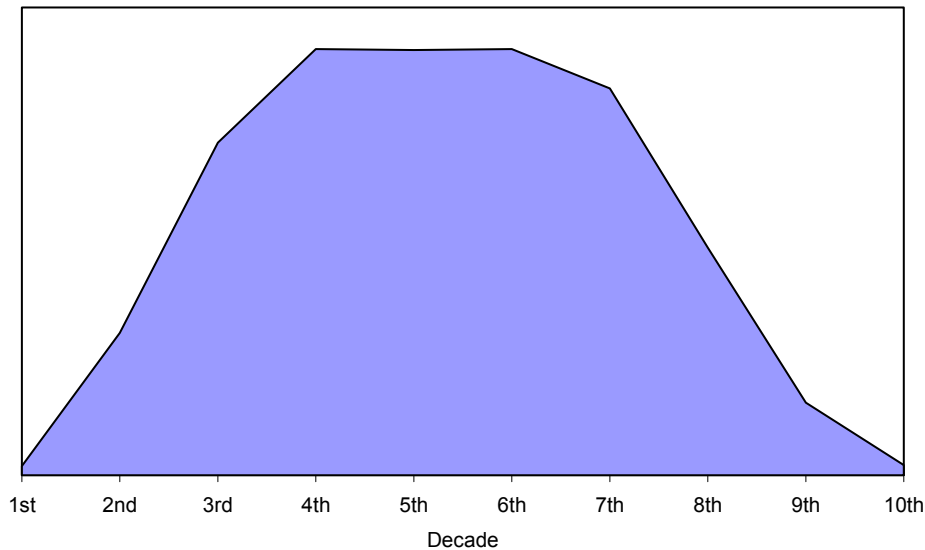


Figure 9. Sites of Occurrence

