

MYOFIBROBLASTIC MALIGNANCIES – A CONTINUING CONTROVERSY

Cyril Fisher MD DSc
Royal Marsden Hospital, London, UK

THE MYOFIBROBLAST

Myofibroblasts are modified fibroblasts which were first identified in granulation tissue, where they are probably derived from local fibroblasts¹, and which form the principal component of a number of reactive and benign soft tissue lesions. Under mechanical stress, the fibroblasts acquire cytoplasmic actin-containing microfilaments or stress fibres which express β - and γ -actins and impart contractility to the cell. The stress fibres are continuous at the cell surface with the fibronexus adhesion complex²⁻⁵. With continuing mechanical tension, these 'proto-myofibroblasts', under the influence of transforming growth factor β 1 and cellular fibronectin, become terminally differentiated myofibroblasts^{4,6}. These cells have better-developed fibronexus and cytoplasmic stress fibres (expressing α SMA, and sometimes desmin and smooth muscle myosin), enabling more effective contractility. In wound healing, as epithelialization is completed, the myofibroblasts are presumed to disappear by apoptosis^{2,4,7}. In other situations myofibroblasts or myofibroblast-like cells might be derived from (vascular) smooth muscle cells or from pericytes⁸, which seem to be related to smooth muscle cells, or by metaplasia from epithelial cells as seen in spindle carcinomas⁹.

Morphology Myofibroblasts are stellate or bipolar cells, with nuclei which are elongated and tapered or wavy like those of fibroblasts, or shorter, ovoid, and pale staining, with distinct, punctate small central nucleoli. Cell boundaries are indistinct, and the cytoplasm is sparse, lightly eosinophilic, or amphophilic. There is sometimes a paranuclear pale zone representing the Golgi complex. Ultrastructurally, the nuclei are indented, and the cytoplasm has abundant rough endoplasmic reticulum and peripheral bundles of thin cytoplasmic filaments (stress fibres) with dense areas. Other features include Golgi complex, collagen secretion granules in Golgi-derived vesicles, and a specific cell-stromal attachment, the fibronexus. This is a transmembrane complex of intracellular microfilaments in continuity with extracellular, longitudinally disposed fibronectin fibrils. It is absent in smooth muscle¹⁰.

Smooth muscle cells differ from myofibroblasts additionally by the presence throughout the cytoplasm of myofibril bundles with focal dense bodies, and by their surface features which include pinocytosis-like vesicles or caveolae, cell membrane thickenings and interrupted or continuous external lamina. These features are variably developed in leiomyosarcomas, in which the lesional cells can resemble myofibroblasts¹¹. In the latter, however, the cytoplasmic filaments form a peripheral band, there is more rough endoplasmic reticulum and the surface specialisations are absent.

Fibroblasts are spindle shaped cells with tapered nuclei and variable amounts of rough endoplasmic reticulum which can be inactive or active (distended with secretory products), so that the cells can be slender (often with a wavy nucleus) or plump. They lack external lamina, pinocytosis and myofibrils. A number of fibroblastic lesions, however, have a component of myofibroblasts and it is possible that cells can modulate between the two morphological and functional states.

Immunohistochemistry Fibroblasts lack myoid markers and express only vimentin. Myofibroblasts, according to circumstance, display heterogeneous cytoskeletal immunophenotypes and actin isoforms: combinations include vimentin with α -smooth muscle actin, desmin, both or neither, and myosin^{12, 13}. Desmin is expressed less frequently in myofibroblastic neoplasms than in smooth muscle tumors¹⁴. Nonetheless, both types of neoplasms can on occasion have detectable desmin, MSA and SMA. Recently, calponin has been demonstrated as a sensitive (but not specific) marker of myofibroblasts, which are usually negative for h-caldesmon, a marker of smooth muscle differentiation¹⁵. CD117 is sometimes positive in the cytoplasm of myofibroblasts, depending on technical considerations¹⁶. However, membranous staining is usually lacking.

Distribution Myofibroblasts occur in the stroma of rare normal tissues (reviewed by Desmouliere and Gabbiani¹⁷ and Eyden et al⁸), and are a major constituent of inflammatory and reparative granulation tissue. Their functions, appearance and immunoprofile vary in granulation tissue in relation to the phase of activity, and with increasing collagenization of the stroma; the cells appear more fibroblast-like. This variation is reflected in the differing stages of reactive lesions such as nodular fasciitis, and contributes to the range of appearances seen in pathological lesions. In the soft tissues, these include reactive and pseudosarcomatous conditions, and benign and malignant tumors. In the latter, they occur both as neoplastic cells and as a component of the reactive stroma.

PATHOLOGY OF MYOFIBROSARCOMA

Malignant tumors of myofibroblasts are rare lesions which have recently become better defined. The term myofibrosarcoma to indicate a malignant tumor of myofibroblasts was suggested by Ghadially, by analogy with the term fibrosarcoma¹⁸. Myofibrosarcomas display a range of differentiation, from fasciitis-like to frankly sarcomatous. Low and intermediate grade myofibrosarcomas can be distinguished from pleomorphic myofibrosarcomas, which are malignant fibrous histiocytoma-like tumors. Other low-grade malignant tumors with myofibroblastic differentiation are inflammatory myofibroblastic tumor and congenital fibrosarcoma. These tumors, which have characteristic and consistent genetic abnormalities, are not usually categorized as myofibrosarcomas but are described briefly below.

Table 1 Malignant tumors with myofibroblastic differentiation

Myofibroblastic sarcomas

Low grade

myofibrosarcoma

inflammatory myofibroblastic tumor

infantile fibrosarcoma

Intermediate grade

myofibrosarcoma

High grade

pleomorphic myofibrosarcoma (MFH)

Other malignant tumors with myofibroblastic differentiation

Dermatofibrosarcoma ('myoid' areas) (questionable)

Epithelioid sarcoma

Spindle cell carcinoma

Low-grade myofibrosarcoma is a distinctive neoplasm, examples of which were formerly classified as other types of sarcoma, or misinterpreted as reactive lesions. It has been described in soft tissues and bone as a fasciitis- or fibrosarcoma-like spindle cell sarcoma which infiltrates locally but rarely metastasizes. The first case is sometimes attributed to Crocker and Murad in 1969¹⁹, although the myofibroblast was not characterized until 1971. Stiller and Katzenkamp observed myofibroblasts in well-differentiated fibrosarcoma in 1975²⁰, and Vasudev and Harris reported the first 'sarcoma of myofibroblasts' 3 years later²¹.

In the next 20 years only 6 adult and 6 paediatric examples of low or intermediate grade myofibrosarcoma were described²²⁻²⁶. All but two of the reported cases arose in the head and neck region in both soft tissue (postauricular region, face, tonsil, scalp, neck, and thyroid) and bone (mandible, maxilla). Three further examples were included in a study of 200 adult soft tissue sarcomas²⁷. In 1998 Mentzel et al described 18 low-grade myofibroblastic sarcomas, of which five had supportive ultrastructural findings²⁸ (although their Fig 11 in fact shows features of smooth muscle cells). Their tumors occurred in 10 males and 7 females between 19-72 years. Five were located in the oral cavity (including four in the tongue), and seven in extremities. Based on the mitotic index, at least one case was likely to have been of intermediate grade malignancy. Montgomery et al subsequently reported 15 myofibrosarcomas (10 low grade and 5 intermediate grade, using the NCI system), of which 9 were ultrastructurally confirmed²⁹. These showed similar clinical features with 11 in men and 4 in women aged 33 to 73 years. 5 lesions involved the head and neck (3 in the oral cavity), and others were located in extremities, trunk and retroperitoneum; three were intraosseous (skull, tibia). Some 10 examples have since been reported in salivary gland³⁰, bone (two in each of femur, ilium, and maxilla)^{31, 32} and breast^{33, 34}, but not all have ultrastructural confirmation³¹.

The age range is 7-85 (mean 40) with a slight male predominance and tumor size ranging between 1.5 and 17 cm. Low-grade myofibrosarcomas can be located superficially in the subcutis or submucosa, but more commonly arise in deeper soft tissue. They are partially circumscribed, but the majority infiltrate irregularly along connective tissue septa or into skeletal muscle. The tumors are composed of mostly bland stellate or spindled cells with tapered or ovoid nuclei with small nucleoli, and scanty or moderate amounts of eosinophilic cytoplasm with variably distinct cell boundaries. These are arranged in fibrosarcoma-like sweeping fascicles, sheets or storiform whorls, with variable collagenous or myxoid stroma and usually scanty inflammation. In places, the patterns mimic those of nodular fasciitis. All cases, however, display focal nuclear atypia. This is usually mild, with scattered enlarged hyperchromatic nuclei, but larger atypical cells are sometimes seen. Mitotic activity is variable but abnormal mitotic figures and necrosis are rare. Occasionally, more cellular areas with polygonal cells are seen, as well as osteoclast-like giant cells. Recurrences tend to be more pleomorphic^{29, 35}, but in one example a breast metastasis from a grade 2 myofibrosarcoma was bland and fasciitis-like²⁹.

Electron microscopy shows myofibroblasts with variable RER, filaments, and in some cases minimal external lamina, and rarely fibronectin fibrils and fibronexus, as well as collagen secretion granules.

Immunohistochemistry Most low-grade myofibrosarcomas express actin, and about a half express desmin, usually in fewer cells^{28, 29}. These antigens can appear together or separately, with either a desmin positive/SMA negative or desmin negative/SMA positive immunophenotype²⁸. The SMA staining can at least focally be discerned as a peripheral rim,

beneath the cell membrane. In addition, calponin is diffusely positive in most cases, whereas h-caldesmon is detected with only focal expression in an occasional case³⁶. These findings, which are similar to those in nodular fasciitis, are potentially useful in the distinction from leiomyosarcoma, which usually displays both caldesmon and calponin. Some myofibrosarcomas display fibronectin³⁷. Cytokeratin and EMA and CD34²⁸ are sporadically positive, and S100 protein exceptionally²⁶.

Behavior Clinically, myofibrosarcomas are generally indolent, but can relapse and metastasize even after a long period. Follow-up in 11 patients with low grade tumors revealed local recurrence in 2 cases, and metastases in one. In the series of Montgomery et al, 4 of 9 low grade tumors, and three of four intermediate grade 2 tumors recurred (one twice), and one grade 2 tumor metastasized to lung after 12 months.

Differential diagnosis Myofibrosarcomas resemble benign myofibroblastic lesions, including nodular fasciitis and fibromatosis, as well as other sarcoma subtypes, notably leiomyosarcoma and fibrosarcoma. The diagnosis is usually made on clinical and morphologic grounds; immunohistochemistry is of limited value.

Nodular fasciitis typically appears suddenly and grows rapidly. It does not usually exceed 5 cm in diameter and is most often located in the subcutis. There is a zoning of appearances with myxoid, cellular and fibrous areas, often in different parts of the same lesion, and nuclear atypia and necrosis are absent. Myofibrosarcoma is more cellular and uniform than nodular fasciitis, and infiltrates more widely including into skeletal muscle and bone. Fibromatosis infiltrates skeletal muscle, with muscle fibres showing atrophy rather than separation by tumor as in myofibrosarcoma. There are parallel-aligned, uniform myofibroblasts dispersed in dense collagen with slit-like blood vessels and mast cells, and cytological atypia is absent.

Table 2. Immunohistochemistry of smooth muscle and fibro/myofibroblastic tumors

	Des	SMA	MSA	S100	EMA	CK	CD34	Calp	hCald
Leiomyosarcoma	+	+	+	+	+	+	±	+	+
Myofibrosarcoma	±	+	±	-*	-	-*	-*	+	-*
Fibrosarcoma*	-	-	-	-	-	-	-	-	-

± = inconsistently reported; * = very occasional positive.

des = desmin SMA = smooth muscle actin, MSA = muscle specific actin (HHF 35)

ema = epithelial membrane antigen; CK = cytokeratin; calp = calponin; hcald = heavy caldesmon

Some myofibrosarcomas closely resemble leiomyosarcoma. The latter, however, typically has alternating fascicles of cells that are less tapered and nuclei that are blunt-ended with scattered paranuclear vacuoles. There is more widespread caldesmon expression. Adult-type fibrosarcoma, on the other hand, has a herringbone fascicular architecture, and cells with scanty cytoplasm and elongated tapered nuclei. There is usually more intercellular collagen than in myofibrosarcoma. In fibrosarcoma, immunohistochemical markers are usually absent (Table 2). The differential diagnosis can include other spindle cell sarcomas such as synovial sarcoma or MPNST as well as some examples of angiosarcoma and spindle

cell rhabdomyosarcoma. These have their specific morphologic accompaniments and immunophenotype. In relevant locations, eg head and neck or breast, spindle cell carcinoma needs to be excluded by use of antibodies to several types of cytokeratin.

Pleomorphic myofibrosarcoma Pleomorphic sarcomas of malignant fibrous histiocytoma (MFH) type are fascicular or storiform neoplasms composed of atypical spindle and polygonal cells, which do not show a specific direction of differentiation. Pleomorphic myofibrosarcoma is a pleomorphic high grade sarcoma in which there is myofibroblastic differentiation, which is usually detected by electron microscopy. Such differentiation has been recognized since the earliest ultrastructural studies of MFH, in which the lesional cells have the appearances of fibroblasts, some of which are plump and histiocyte-like. Some show myofibroblastic features^{27, 38, 39}, including a rare fibronexus⁴⁰. The proportion of MFH with myofibroblasts depends partly on sample size and the thoroughness of the observer but has been varied between 27% and 100% in quantitative studies⁴¹⁻⁴⁷. In the largest series so examined, 56% of 32 MFH of all types had detectable myofibroblasts, with a mean of 3% (range 0-22%) of myofibroblasts per case⁴⁷.

There are, however, few fully documented reports of pleomorphic myofibrosarcoma. Eyden et al described 2 cases in soft tissue in 1991²⁶, and some low-or intermediate-grade myofibrosarcomas have recurred as pleomorphic tumors^{25, 29}. Montgomery et al examined a series of 7 cases, compared them with undifferentiated pleomorphic sarcomas, and found the two types of sarcoma to be clinically and morphologically indistinguishable⁴⁸. A subset has been described in the head neck in children²⁵, but the tumors predominantly involve extremities in adults. Histologically, most pleomorphic myofibrosarcomas are composed of spindle and polygonal cells arranged at least focally in a storiform pattern, with occasional fascicular areas. Large polygonal cells with abundant cytoplasm are seen which mimic rhabdomyoblasts. Fibrosis, myxoid change, necrosis and inflammation are variable.

Immunohistochemistry Actin and desmin have been described in pleomorphic sarcomas in the absence of morphological or ultrastructural evidence of smooth muscle differentiation^{49, 50}, as well as in some with ultrastructurally confirmed myofibroblastic differentiation³⁹. In ultrastructurally defined pleomorphic myofibrosarcomas, SMA and desmin were positive respectively in 57% and 43% of cases⁴⁸; none of the myofibrosarcomas studied expressed h-caldesmon³⁶, which argues against their being poorly differentiated leiomyosarcomas. In the same study, SMA and desmin were found respectively in 33% and 27% of undifferentiated pleomorphic sarcomas, suggesting that myofibroblastic (and, possibly, smooth muscle) differentiation is more readily detected by immunohistochemistry than electron microscopy.

Behavior Pleomorphic myofibrosarcoma, like other types of pleomorphic sarcoma, is a high-grade malignancy. In the series of Montgomery et al, with a median follow up period of 41 months, 29% of pleomorphic myofibrosarcomas recurred, 71% metastasized, and 43% of patients died of disease⁴⁸. Among the non-myofibroblastic sarcomas, with a median follow up of 47 months, 35% recurred, 59% metastasized, and 41% of patients died of disease. Thus, pleomorphic myofibrosarcoma is clinically similar to MFH, and myofibroblastic differentiation appears to confer no survival advantage.

Differential Diagnosis Pleomorphic myofibrosarcoma is histologically indistinguishable from MFH. With immunohistochemistry, myofibroblastic differentiation can be inferred from the presence of SMA positivity in large polygonal or pleomorphic spindle cells, especially if the staining is accentuated at the periphery of cell. The differential diagnosis

includes pleomorphic liposarcoma and pleomorphic rhabdomyosarcoma, as well as non-mesenchymal tumors such as melanoma and sarcomatoid carcinoma. The former is defined by the presence of pleomorphic lipoblasts in an otherwise featureless pleomorphic MFH-like sarcoma, and can also have epithelioid areas. The latter has rhabdomyoblastic differentiation, manifested as large round cells with eosinophilic cytoplasm, strap cells with cross-striations, and immunohistochemical reactivity for desmin in cytoplasm and myogenin in nuclei.

OTHER SARCOMAS WITH MYOFIBROBLASTIC DIFFERENTIATION

Inflammatory myofibroblastic tumor (IMT) usually arises within the abdomen (retroperitoneum or mesentery) as a solitary or multicentric mass with a peak incidence in childhood or adolescence^{51, 52}. Similar cases have been termed inflammatory fibrosarcoma⁵³, but this and IMT are considered to represent a single entity with a spectrum of morphology and behaviour⁵². Microscopically, there are fasciitis-like, fascicular and sclerosing areas, with a prominent chronic inflammatory infiltrate including numerous plasma cells. (Figs 10, 11) Pleomorphism is rare although atypical cells can sometimes be seen. Most IMT are positive for smooth muscle actin, and a smaller number for desmin; some cases (especially those in a submesothelial location) are cytokeratin positive. About 30-40% of IMT stain for ALK⁵⁴⁻⁵⁶, especially abdominal and pulmonary IMT in the first decade. EM shows a mixture of cells with fibroblastic and myofibroblastic features^{53, 57, 58}.

Many IMT have clonal abnormalities involving 2p22-24^{59, 60}. Fusion of the anaplastic lymphoma kinase (ALK) gene, located on 2p23, which encodes a tyrosine kinase receptor, with the gene for tropomyosin 3 (TPM3-ALK) or tropomyosin 4 (TPM4-ALK) is seen in some of the tumors⁶¹. A novel transcript involving ALK and CLTC (clathrin heavy chain gene, localized to 17q23) has also been described in 2 cases⁶².

About a third of IMT recur locally and a few, for which there are no histological predictive factors, progress to frank sarcoma⁶³⁻⁶⁵. The differential diagnosis includes sclerosing fibro-inflammatory lesions, fibromatosis, low grade myofibrosarcoma, inflammatory leiomyosarcoma and follicular dendritic cell sarcoma.

Infantile fibrosarcoma (IFS) is a further tumor of borderline malignancy that is generally included on accounts of myofibroblastic malignancies but which is a genetically distinct entity. IFS occurs predominantly in the first 4 years of life as a cellular tumor with parallel or herringbone fascicles of fairly uniform darkly staining ovoid spindle cells with mitotic activity but without cytological atypia or pleomorphism. A small subset of tumors contain immature small round cells. Ultrastructurally these tumours are composed of fibroblasts and myofibroblasts and immunohistochemistry shows smooth muscle actin in about a third of cases, and desmin in a quarter. CD34 and S100 protein expression are occasionally seen.

Chromosomal abnormalities described in IFS include trisomy 11, random gains of chromosomes 8, 11, 17 and 20⁶⁶, deletion of long arm of 17⁶⁷; and a t(12;13) translocation⁶⁸. A specific translocation t(12;15)(p13;q25) resulting in fusion of ETV6 and NTRK3 genes has been identified in IFS⁶⁹⁻⁷¹. This has also been found in cellular variants of congenital mesoblastic nephroma, a renal tumor resembling IFS^{72, 73}.

Up to 30% of IFS recur, but, unlike in adult fibrosarcoma, metastases are rare, with a frequency of 5% or less in published series. However, local complications of the tumour can be fatal⁷⁴.

Myofibroblasts in malignant tumors with epithelial differentiation Epithelioid sarcoma is a mesenchymal tumor in which the predominant differentiation is epithelial but which also shows morphologic and ultrastructural differentiation towards myofibroblasts^{75,76}. This occurs mainly towards the edges of the tumor nodules by apparent transition from epithelioid cells, and is associated with expression of smooth muscle and muscle specific actins but not desmin⁷⁷. Similar differentiation can be seen in sarcomatoid carcinoma⁹.

THE CONCEPT OF MYOFIBROSARCOMA

Controversy has surrounded the myofibrosarcoma concept for several reasons. First, there is a close relationship between fibroblast and myofibroblasts: in many fibroblastic lesions, at least some cells show differentiation to myofibroblasts. The proportion of neoplastic myofibroblasts required is not defined and fibrosarcoma and myofibrosarcoma might represent a continuum. It appears from the observations described above, however, that a group of sarcomas can be recognized which are composed predominantly of myofibroblasts.

Also, myofibroblasts resemble fibroblasts and it remains difficult to be certain of myofibroblastic differentiation without electron microscopy; yet, the ultrastructural definition of the neoplastic myofibroblast is not agreed^{11,78}. The debate principally concerns whether stress fibers and the fibronexus, a characteristic ultrastructural feature of reactive myofibroblasts, must be present for a diagnosis of myofibrosarcoma. In neoplastic cells, subcellular features can be incompletely or abnormally developed, so that the fibronexus has not been an absolute requirement for most investigators. Nevertheless, this structure has been observed in neoplastic cells in a number of such sarcomas²⁴; indeed, due to being overlooked or misinterpreted as external lamina, it has perhaps been illustrated more frequently in published reports than it has been recognized by their authors¹⁴. In reality, identification of a cell type requires summation of several features, and the fibronexus is only one feature used to define myofibroblastic differentiation. Despite the superficial similarity of cytoplasmic filament patterns in both myofibroblasts and smooth muscle cells, the surface specialisations of the two cell types differ; unlike myofibroblasts, smooth muscle cells have external lamina, cell membrane plaques and caveolae. Finally, the cells of myofibrosarcoma and those of fibromatosis, an accepted myofibroblastic lesion, are ultrastructurally similar. It is noteworthy that in the case of Gabbiani et al, a metastasising myofibrosarcoma of pleura²², the fibronexus is not mentioned in their description of the ultrastructure, which corresponds to that accepted by most authors today.

It can be concluded that the fibronexus, whether completely or incompletely formed, is seen in some myofibrosarcomas, and in other cases the ultrastructure, in morphology and immunohistochemistry, are sufficiently distinctive to allow diagnosis.

With immunohistochemistry, neoplastic smooth muscle cells and myofibroblasts can both display actins and desmin, but the latter is less often seen in myofibroblastic neoplasms. Also, in myofibroblastic sarcomas, the actin staining is often manifested as a peripheral rim (correlating with the ultrastructural location of filament bundles) rather than throughout the cell⁴⁸. The absence or rarity of h-caldesmon in both benign and malignant myofibroblastic lesions additionally supports their separate identity.^{15,79}

References

1. Gabbiani G, Ryan GB, Majno G. Presence of modified fibroblasts in granulation tissue and their possible role in wound contraction. *Experientia* 1971;27:549-550.

2. Gabbiani G. The cellular derivation and the life span of the myofibroblast. *Pathol Res Pract* 1996;192:708-711.
3. Desmouliere A, Geinoz A, Gabbiani F, Gabbiani G. Transforming growth factor-beta 1 induces alpha-smooth muscle actin expression in granulation tissue myofibroblasts and in quiescent and growing cultured fibroblasts. *J Cell Biol* 1993;122:103-111.
4. Gabbiani G. The myofibroblast in wound healing and fibrocontractive diseases. *J Pathol* 2003;200:500-503.
5. Hinz B, Mastrangelo D, Iselin CE, et al. Mechanical tension controls granulation tissue contractile activity and myofibroblast differentiation. *Am J Pathol* 2001;159:1009-1020.
6. Tomasek JJ, Gabbiani G, Hinz B, et al. Myofibroblasts and mechano-regulation of connective tissue remodelling. *Nat Rev Mol Cell Biol* 2002;3:349-363.
7. Darby I, Skalli O, Gabbiani G. α -smooth muscle actin is transiently expressed by myofibroblasts during experimental wound healing. *Lab Invest* 1990;63:21-29.
8. Eyden BP, Ponting J, Davies H, et al. Defining the myofibroblast: normal tissues, with special reference to the stromal cells of Wharton's jelly in human umbilical cord. *J Submicrosc Cytol Pathol* 1994;26:347-355.
9. Balercia G, Bhan AK, Dickersin GR. Sarcomatoid carcinoma: an ultrastructural study with light microscopic and immunohistochemical correlation of 10 cases from various anatomic sites. *Ultrastructural Pathol* 1995;19:249-263.
10. Eyden B. The fibronexus in reactive and tumoral myofibroblasts: further characterisation by electron microscopy. *Histol Histopathol* 2001;16:57-70.
11. Erlandson RA. Diagnostic Transmission Electron Microscopy of Tumors, with clinico-pathological, immunohistochemical and cytogenetic correlations. New York: Raven; 1994a.
12. Skalli O, Gabbiani G, Babaï, et al. Intermediate filament proteins and actin isoforms as markers for soft tissue tumor differentiation and origin. II. Rhabdomyosarcomas. *Am J Pathol* 1988;130:515-531.
13. Schürch W, Seemayer TA, Gabbiani G. Myofibroblast. In Sternberg SS, ed. *Histology for Pathologists*. 2nd Edn. New York, Raven Press 1997:129-165.
14. Eyden B. The myofibroblast: an assessment of controversial issues and a definition useful in diagnosis and research. *Ultrastruct Pathol* 2001;25:39-50.
15. Ceballos KM, Nielsen GP, Selig MK, O'Connell JX. Is anti-h-caldesmon useful for distinguishing smooth muscle and myofibroblastic tumors? An immunohistochemical study. *Am J Clin Pathol* 2000;114:746-753.
16. Miettinen M. Are desmoid tumors kit positive? *Am J Surg Pathol* 2001;25:549-550.
17. Desmouliere A, Gabbiani G. The role of the myofibroblast in wound healing and fibrocontractive diseases. in *The molecular and cellular biology of wound repair* 2nd Edn Ed Clark RAF 1996:391-423.
18. Ghadially FN. *Diagnostic Electron Microscopy of Tumours*. London: Butterworths; 1980. p136.
19. Crocker DJ, Murad TM. Ultrastructure of fibrosarcoma in a male breast. *Cancer* 1969;23:891-899.

20. Stiller D, Katenkamp D. Cellular features in desmoid fibromatosis and well-differentiated fibrosarcomas: an electron microscopic study. *Virchows Arch A Pathol Anat Histol* 1975;369:155-164.
21. Vasudev KS, Harris M. A sarcoma of myofibroblasts. An ultrastructural study. *Arch Pathol Lab Med* 1978;102:185-188.
22. d'Andiran G, Gabbiani G. A metastasizing sarcoma of the pleura composed of myofibroblasts. *Prog Surg Pathol* 1980;2:31-40.
23. Taccagni G, Rovere E, Masullo M, et al. Myofibrosarcoma of the breast: review of the literature on myofibroblastic tumors and criteria for defining myofibroblastic differentiation. *Am J Surg Pathol* 1997;21:489-496.
24. Eyden BP, Christensen L, Tagore V, Harris M. Myofibrosarcoma of subcutaneous soft tissue of the cheek. *J Submicrosc Cytol Pathol* 1992;24:307-313.
25. Smith DM, Mahmoud HH, Jenkins JJ, 3rd, et al. Myofibrosarcoma of the head and neck in children. *Pediatr Pathol Lab Med* 1995;15:403-418.
26. Eyden BP, Banerjee SS, Harris M, Mene A. A study of spindle cell sarcomas showing myofibroblastic differentiation. *Ultrastruct Pathol* 1991;15:367-378.
27. Fisher C. The value of electronmicroscopy and immunohistochemistry in the diagnosis of soft tissue sarcomas: a study of 200 cases. *Histopathology* 1990;16:441-454.
28. Mentzel T, Dry S, Katenkamp D, Fletcher CD. Low-grade myofibroblastic sarcoma: analysis of 18 cases in the spectrum of myofibroblastic tumors. *Am J Surg Pathol* 1998;22:1228-1238.
29. Montgomery E, Goldblum JR, Fisher C. Myofibrosarcoma: a clinicopathologic study. *Am J Surg Pathol* 2001;25:219-228.
30. Bisceglia M, Magro G. Low-grade myofibroblastic sarcoma of the salivary gland. *Am J Surg Pathol* 1999;23:1435-1436.
31. Bisceglia M, Tricarico N, Minenna P, et al. Myofibrosarcoma of the upper jawbones: a clinicopathologic and ultrastructural study of two cases. *Ultrastruct Pathol* 2001;25:385-397.
32. Watanabe K, Ogura G, Tajino T, et al. Myofibrosarcoma of the bone: a clinicopathologic study. *Am J Surg Pathol* 2001;25:1501-1507.
33. Gocht A, Bosmuller HC, Bassler R, et al. Breast tumors with myofibroblastic differentiation: clinico-pathological observations in myofibroblastoma and myofibrosarcoma. *Pathol Res Pract* 1999;195:1-10.
34. Lucin K, Mustac E, Jonjic N. Breast sarcoma showing myofibroblastic differentiation. *Virchows Arch* 2003.
35. Kuhnen C, Homann HH, Mentzel T. Myofibroblastic sarcoma of the thoracic wall. Change in appearance in tumour recurrence. *Pathologie* 2003;24:128-135.
36. Fisher C, Goldblum JR, Montgomery E. Calponin and h-caldesmon in sarcomas of myofibroblasts. *Mod Pathol* 2003;16:11A.
37. Eyden BP, Christensen L. Leiomyosarcoma versus myofibrosarcoma: observations and terminology. *Ultrastruct Pathol* 1993;17:231-239.
38. Fu Y-S, Gabbiani G, Kaye GI, Lattes R. Malignant soft tissue tumours of probable histiocytic origin (malignant fibrous histiocytomas): general considerations and electron microscopic and tissue culture studies. *Cancer* 1975;35:176-198.

39. Hirose T, Kudo E, Hasegawa T, et al. Expression of intermediate filaments in malignant fibrous histiocytomas. *Hum Pathol* 1989;20:871-877.
40. Watanabe K, Ogura G. Fibronexus in "malignant fibrous histiocytoma" of the bone: a case report of pleomorphic myofibrosarcoma. *Ultrastruct Pathol* 2002;26:47-51.
41. Churg AM, Kahn LB. Myofibroblasts and related cells in malignant fibrous and fibrohistiocytic tumors. *Hum Pathol* 1977;8:205-218.
42. Tsuneyoshi M, Enjoji M, Shinohara N. Malignant fibrous histiocytoma. An electron microscopic study of 17 cases. *Virchows Arch A Pathol Anat* 1981;392:135-145.
43. Reddick RL, Michelitch H, Triche TJ. Malignant soft tissue tumors (malignant fibrous histiocytoma, pleomorphic liposarcoma, and pleomorphic rhabdomyosarcoma): an electron microscopic study. *Hum Pathol* 1979;10:327-343.
44. Harris M. The ultrastructure of benign and malignant fibrous histiocytomas. *Histopathology* 1980;4:29-44.
45. Weiss LM, Warhol MJ. Ultrastructural distinctions between adult pleomorphic rhabdomyosarcomas, pleomorphic liposarcomas, and pleomorphic malignant fibrous histiocytomas. *Hum Pathol* 1984;15:1025-1033.
46. Hoffman MA, Dickersin GR. Malignant fibrous histiocytoma: an ultrastructural study of eleven cases. *Hum Pathol* 1983;14:913-922.
47. Fukuda T, Tsuneyoshi M, Enjoji M. Malignant fibrous histiocytoma of soft parts: an ultrastructural quantitative study. *Ultrastructural Pathol* 1988;12:117-129.
48. Montgomery E, Fisher C. Myofibroblastic differentiation in malignant fibrous histiocytoma (pleomorphic myofibrosarcoma): a clinicopathological study. *Histopathology* 2001;38:499-509.
49. Schürch W, Bégin LR, Seemayer TA, et al. Pleomorphic soft tissue myogenic sarcomas of adulthood: A reappraisal in the mid-1990s. *American Journal of Surgical Pathology* 1996;20:131-147.
50. Lawson CW, Fisher C, Gatter K. An immunohistochemical study of differentiation in malignant fibrous histiocytoma. *Histopathology* 1987;11:375-383.
51. Coffin CM, Humphrey PA, Dehner LP. Extrapulmonary inflammatory myofibroblastic tumor: a clinical and pathological survey. *Semin Diagn Pathol* 1998;15:85-101.
52. Coffin CM, Dehner LP, Meis-Kindblom JM. Inflammatory myofibroblastic tumor, inflammatory fibrosarcoma, and related lesions: an historical review with differential diagnostic considerations. *Semin Diagn Pathol* 1998;15:102-110.
53. Meis JM, Enzinger FM. Inflammatory fibrosarcoma of the mesentery and retroperitoneum. A tumor closely simulating inflammatory pseudotumor. *Am J Surg Pathol* 1991;15:1146-1156.
54. Chan JK, Cheuk W, Shimizu M. Anaplastic lymphoma kinase expression in inflammatory pseudotumors. *Am J Surg Pathol* 2001;25:761-768.
55. Coffin CM, Patel A, Perkins S, et al. ALK1 and p80 expression and chromosomal rearrangements involving 2p23 in inflammatory myofibroblastic tumor. *Mod Pathol* 2001;14:569-576.
56. Cessna MH, Zhou H, Sanger WG, et al. Expression of ALK1 and p80 in inflammatory myofibroblastic tumor and its mesenchymal mimics: a study of 135 cases. *Mod Pathol* 2002;15:931-938.

57. Coffin CM, Watterson J, Priest JR, Dehner LP. Extrapulmonary inflammatory myofibroblastic tumor (inflammatory pseudotumor) - A clinicopathologic and immunohistochemical study of 84 cases. *Am J Surg Pathol* 1995;19:859-872.
58. Meis-Kindblom JM, Kjellstrom C, Kindblom LG. Inflammatory fibrosarcoma: update, reappraisal, and perspective on its place in the spectrum of inflammatory myofibroblastic tumors. *Semin Diagn Pathol* 1998;15:133-143.
59. Su LD, Atayde-Perez A, Sheldon S, et al. Inflammatory myofibroblastic tumor: cytogenetic evidence supporting clonal origin. *Mod Pathol* 1998;11:364-368.
60. Griffin CA, Hawkins AL, Dvorak C, et al. Recurrent involvement of 2p23 in inflammatory myofibroblastic tumors. *Cancer Res* 1999;59:2776-2780.
61. Lawrence B, Perez-Atayde A, Hibbard MK, et al. TPM3-ALK and TPM4-ALK oncogenes in inflammatory myofibroblastic tumors. *Am J Pathol* 2000;157:377-384.
62. Bridge JA, Kanamori M, Ma Z, et al. Fusion of the ALK gene to the clathrin heavy chain gene, CLTC, in inflammatory myofibroblastic tumor. *Am J Pathol* 2001;159:411-415.
63. Donner LR, Trompler RA, White RR. Progression of inflammatory myofibroblastic tumor (inflammatory pseudotumor) of soft tissue into sarcoma after several recurrences. *Hum Pathol* 1996;27:1095-1098.
64. Biselli R, Boldrini R, Ferlini C, et al. Myofibroblastic tumours: neoplasias with divergent behaviour. Ultrastructural and flow cytometric analysis. *Pathol Res Pract* 1999;195:619-632.
65. Hussong JW, Brown M, Perkins SL, et al. Comparison of DNA ploidy, histologic, and immunohistochemical findings with clinical outcome in inflammatory myofibroblastic tumors. *Mod Pathol* 1999;12:279-286.
66. Schofield DE, Fletcher JA, Grier HE, Yunis EJ. Fibrosarcoma in infants and children. Application of new techniques. *Am J Surg Pathol* 1994;18:14-24.
67. Gorman PA, Malone M, Pritchard J, Sheer D. Deletion of part of the short arm chromosome 17 in a congenital fibrosarcoma. *Cancer Genet Cytogenet* 1990;48:193-198.
68. Strehl S, Ladenstein R, Wrba F, et al. Translocation (12;13) in a case of infantile fibrosarcoma. *Cancer Genet Cytogenet* 1993;71:94-96.
69. Knezevich SR, McFadden DE, Tao W, et al. A novel ETV6-NTRK3 gene fusion in congenital fibrosarcoma. *Nat Genet* 1998;18:184-187.
70. Bourgeois JM, Knezevich SR, Mathers JA, Sorensen PH. Molecular detection of the ETV6-NTRK3 gene fusion differentiates congenital fibrosarcoma from other childhood spindle cell tumors. *Am J Surg Pathol* 2000;24:937-946.
71. Sheng WQ, Hisaoka M, Okamoto S, et al. Congenital-infantile fibrosarcoma. A clinicopathologic study of 10 cases and molecular detection of the ETV6-NTRK3 fusion transcripts using paraffin-embedded tissues. *Am J Clin Pathol* 2001;115:348-355.
72. Knezevich SR, Garnett MJ, Pysher TJ, et al. ETV6-NTRK3 gene fusions and trisomy 11 establish a histogenetic link between mesoblastic nephroma and congenital fibrosarcoma. *Cancer Res* 1998;58:5046-5048.

73. Rubin BP, Chen CJ, Morgan TW, et al. Congenital mesoblastic nephroma t(12;15) is associated with ETV6-NTRK3 gene fusion: cytogenetic and molecular relationship to congenital (infantile) fibrosarcoma. *Am J Pathol* 1998;153:1451-1458.
74. Coffin CM, Jaszcz W, O'Shea PA, Dehner LP. So-called congenital-infantile fibrosarcoma: does it exist and what is it? *Pediatr Pathol* 1994;14:133-150.
75. Fisher C. Epithelioid sarcoma: the spectrum of ultrastructural differentiation in seven immunohistochemically defined cases. *Hum Pathol* 1988;19:265-275.
76. Blewitt RW, Aparicio SG, Bird CC. Epithelioid sarcoma: a tumour of myofibroblasts. *Histopathology* 1983;7:573-584.
77. Miettinen M, Fanburg-Smith JC, Virolainen M, et al. Epithelioid sarcoma: an immunohistochemical analysis of 112 classical and variant cases and a discussion of the differential diagnosis. *Hum Pathol* 1999;30:934-942.
78. Lagace R, Seemayer TA, Gabbiani G, Schurch W. Myofibroblastic sarcoma. *Am J Surg Pathol* 1999;23:1432-1435.
79. Miettinen MM, Sarlomo-Rikala M, Kovatich AJ, Lasota J. Calponin and h-caldesmon in soft tissue tumors: consistent h-caldesmon immunoreactivity in gastrointestinal stromal tumors indicates traits of smooth muscle differentiation. *Mod Pathol* 1999;12:756-762.

GENE EXPRESSION PROFILING OF SOFT TISSUE TUMORS

Matt van de Rijn MD PhD,
Stanford University Medical Center, Stanford, CA

Introduction:

High throughput microarray technologies are a discovery tool that allow for the determination of mRNA levels for many thousands of genes in a single experiment, a process referred to as gene expression profiling. Soft tissue tumors are rare lesions in which a large number of clinically relevant different diagnostic entities have been described. Relatively few truly diagnostic markers exist and many of these markers are not specific for a single entity. Global gene expression profiling allows for a systematic search of all human genes for novel diagnostic and prognostic markers and for potential therapeutic targets. Many groups have applied this technology to study soft tissue tumors¹⁻⁹. Using the same arrays, gene copy number changes can be determined on a gene-by-gene basis using DNA derived from fresh frozen tissue or from paraffin embedded material, a process called array-based comparative genomic hybridization (aCGH)⁹⁻¹¹. Gene expression profiling and aCGH yield a wealth of data and the combination of data from gene expression profiling and aCGH can help focus attention on genes that are not only highly expressed in certain tumors but are also affected on a genomic level. Tissue microarrays are an efficient method to extend and validate the findings obtained from the initial “discovery” phase of the research, performed with cDNA microarrays. Recent developments allow formalin fixed material represented on TMAs to be examined not only by immunohistochemistry (IHC) but also by in situ hybridization (ISH). While the datasets obtained through gene arrays can measure several million datapoints or more, TMA datasets usually consist of several thousand datapoints. This nevertheless is more than can be interpreted from a simple table and we have developed software to aid in the management of these TMA datasets. The amount of information stored in histologic images far exceeds that contained in a fluorescence level for a spot in a gene array. Therefore rapid review of digital images is a necessity¹². I will give several examples of discoveries made by these relatively new techniques.

Examples:

1 Epidermal Growth Factor Receptor as a potential therapeutic target in synovial sarcoma.

In a gene expression profiling study we noted high levels of epidermal growth factor receptor (EGFR) mRNA in synovial sarcoma⁶. We subsequently confirmed EGFR protein expression using a TMA with 46 synovial sarcomas¹³. As a result, the EORTC started a study using Erisa/ZD1839 as a targeted inhibitor of epidermal growth factor receptor. This trial is now accruing patients in The Netherlands, Belgium and France with other countries to follow (van Oosterom, personal communication, Sept 2003, Helsinki). This shows that gene expression profiling is a powerful tool to highlight targets for directed therapies in specific tumor subtypes.

2 The PDGFb pathway highlighted by gene array analysis in DFSP.

In DFSP, the PDGFb gene was known to play a role in tumorigenesis as it was involved in the t(17;22) that fuses this gene to collagen 1a1¹⁴. In a recent study on DFSP we confirmed the significance of the PDGF pathway by showing that DFSP has high levels of PDGFb⁹. In addition we found that the receptor for PDGFb was also very highly expressed, thus mimicking the tumorigenic autocrine loop previously constructed in fibroblasts and glioblastoma cells¹⁵. We showed that 2 other proteins, BRB2 and Protein Kinase C, that play roles in the PDGF pathway, were also highly and specifically expressed in DFSP. Finally, by aCGH we showed that BRB2 and PRKC are located on an amplified part of chromosome 17, presumably as part of the ring chromosome often seen in these tumors⁹. These experiments demonstrate that the PDGF pathway plays an important role in DFSP and that this pathway may be a good target in treatment of this tumor.

3 DOG1 a novel marker for GIST.

Others and we have shown that GISTs have a unique and specific gene expression profile^{6,7,9}. In the last year we have started to study a number of GIST specific genes, one of which will be highlighted here. In gene arrays studies we found that expression for FLJ10261, a hypothetical protein at that time, was very high in gastrointestinal stromal

tumors but low in most other sarcomas. We generated an antiserum (S284) against the peptides derived from the sequence for this hypothetical protein, and obtained very strong immunoreactivity with GISTs and mast cells, mimicking closely the reactivity of anti-kit/CD117 antisera. A cross reactivity between S284 and kit antisera on a possible shared epitope on the two proteins could be excluded by in situ hybridization experiments showing that mRNA was present in S284 reactive lesions but not in those that failed to react for this serum. Having proven the existence of an mRNA and protein derived from this sequence, we named the gene “Discovered on GIST-1” (DOG1). Next we identified on a 421 case STT TMA a subset of GIST-like lesions that failed to react for kit but did react for DOG1 by IHC and ISH. Subsequently, through collaboration with Drs Chris Corless and Mike Heinrich we could show that this subset of lesions consisted of the newly described subset of GISTs that do not have a mutation in the kit gene but instead carry a mutation in the PDGRFa gene¹⁶. Clinically this may be a relevant marker, as many diagnosticians require kit reactivity today before a diagnosis of “GIST” is rendered, with the FDA considering making this a requirement¹⁷. Thus the clinical significance of DOG1 as a marker is obvious as patients with GISTs that fail to react for kit antigen run the risk of not receiving imatinib mesylate (Gleevec) therapy¹⁶. Immunofluorescence studies on the GIST882 cell line (DR Jonathan Fletcher) have shown membrane staining for DOG1, consistent with the 8 transmembrane regions implied from its DNA sequence. The spatial relationship, if any, to kit, using the GIST882 cell line and its potential role as a therapeutic target will need to be determined.

References:

1. Segal NH, Pavlidis P, Antonescu CR, Maki RG, Noble WS, DeSantis D, Woodruff JM, Lewis JJ, Brennan MF, Houghton AN, Cordon-Cardo C: Classification and subtype prediction of adult soft tissue sarcoma by functional genomics. *American Journal of Pathology* 2003, 163:691-700
2. Segal NH, Pavlidis P, Noble WS, Antonescu CR, Viale A, Wesley UV, Busam K, Gallardo H, DeSantis D, Brennan MF, Cordon-Cardo C, Wolchok JD, Houghton

- AN: Classification of clear-cell sarcoma as a subtype of melanoma by genomic profiling. *Journal of Clinical Oncology* 2003, 21:1775-1781
3. Skubitz KM, Skubitz AP: Differential gene expression in leiomyosarcoma. *Cancer* 2003, 98:1029-1038
 4. Ren B, Yu YP, Jing L, Liu L, Michalopoulos GK, Luo JH, Rao UN: Gene expression analysis of human soft tissue leiomyosarcomas. *Human Pathology* 2003, 34:549-558
 5. Nagayama S, Katagiri T, Tsunoda T, Hosaka T, Nakashima Y, Araki N, Kusuzaki K, Nakayama T, Tsuboyama T, Nakamura T, Imamura M, Nakamura Y, Toguchida J: Genome-wide analysis of gene expression in synovial sarcomas using a cDNA microarray. *Cancer Research* 2002, 62:5859-5866
 6. Nielsen TO, West RB, Linn SC, Alter O, Knowling MA, O'Connell JX, Zhu S, Fero M, Sherlock G, Pollack JR, Brown PO, Botstein D, van de Rijn M: Molecular characterisation of soft tissue tumours: a gene expression study.[comment]. *Lancet* 2002, 359:1301-1307
 7. Allander SV, Nupponen NN, Ringner M, Hostetter G, Maher GW, Goldberger N, Chen Y, Carpten J, Elkahlon AG, Meltzer PS: Gastrointestinal stromal tumors with KIT mutations exhibit a remarkably homogeneous gene expression profile. *Cancer Research* 2001, 61:8624-8628
 8. Allander SV, Illei PB, Chen Y, Antonescu CR, Bittner M, Ladanyi M, Meltzer PS: Expression profiling of synovial sarcoma by cDNA microarrays: association of ERBB2, IGFBP2, and ELF3 with epithelial differentiation.[comment]. *American Journal of Pathology* 2002, 161:1587-1595
 9. Linn SC, West RB, Pollack JR, Zhu S, Hernandez-Boussard T, Nielsen TO, Rubin BP, Patel R, Goldblum JR, Siegmund D, Botstein D, Brown PO, Gilks CB, van de Rijn M: Gene expression patterns and gene copy number changes in dermatofibrosarcoma protuberans. *American Journal of Pathology* 2003, in press.
 10. Pollack JR, Perou CM, Alizadeh AA, Eisen MB, Pergamenschikov A, Williams CF, Jeffrey SS, Botstein D, Brown PO: Genome-wide analysis of DNA copy-number changes using cDNA microarrays. *Nature Genetics* 1999, 23:41-46

11. Pollack JR, Sorlie T, Perou CM, Rees CA, Jeffrey SS, Lonning PE, Tibshirani R, Botstein D, Borresen-Dale AL, Brown PO: Microarray analysis reveals a major direct role of DNA copy number alteration in the transcriptional program of human breast tumors. *Proceedings of the National Academy of Sciences of the United States of America* 2002, 99:12963-12968
12. Liu CL, Prapong W, Natkunam Y, Alizadeh A, Montgomery K, Gilks CB, van de Rijn M: Software tools for high-throughput analysis and archiving of immunohistochemistry staining data obtained with tissue microarrays. *American Journal of Pathology* 2002, 161:1557-1565
13. Nielsen TO, Hsu FD, O'Connell JX, Gilks CB, West RB, Liu CL, Botstein D, Brown PO, van de Rijn M: Tissue microarray analysis of novel synovial sarcoma immunohistochemical markers. *American Journal of Pathology* 2003, 163:1449-1456
14. Simon MP, Pedeutour F, Sirvent N, Grosgeorge J, Minoletti F, Coindre JM, Terrier-Lacombe MJ, Mandahl N, Craver RD, Blin N, Sozzi G, Turc-Carel C, O'Brien KP, Kedra D, Fransson I, Guilbaud C, Dumanski JP: Deregulation of the platelet-derived growth factor B-chain gene via fusion with collagen gene COL1A1 in dermatofibrosarcoma protuberans and giant-cell fibroblastoma. *Nature Genetics* 1997, 15:95-98
15. Westermark B, Heldin CH: Platelet-derived growth factor in autocrine transformation. *Cancer Research* 1991, 51:5087-5092
16. Heinrich MC, Corless CL, Duensing A, McGreevey L, Chen CJ, Joseph N, Singer S, Griffith DJ, Haley A, Town A, Demetri GD, Fletcher CD, Fletcher JA: PDGFRA activating mutations in gastrointestinal stromal tumors. *Science* 2003, 299:708-710
17. Fletcher CD, Fletcher JA: Testing for KIT (CD117) in gastrointestinal stromal tumors: another HercepTest? *American Journal of Clinical Pathology* 2002, 118:163-164

Neoplasms with Perivascular Epithelioid Cell Differentiation (PEComas): An Update

Andrew L. Folpe, M.D.

Emory University, Atlanta, GA

Introduction

The World Health Organization defines PEComas as “mesenchymal tumors composed of histologically and immunohistochemically distinctive perivascular epithelioid cells”. The concept of a family of neoplasms derived from these distinctive cells was first advanced by Bonetti and co-workers in a letter published in the American Journal of Surgical Pathology in 1992, in which they noted the presence in both angiomyolipoma (AML) and clear cell “sugar” tumor of the lung (CCST) of “an unusual cell type... immunoreactive with melanocytic markers, and exhibit(ing) an epithelioid appearance, a clear-acidophilic cytoplasm, and a perivascular distribution”.

The PEComa family of tumors has subsequently grown to include AML, CCST, lymphangiomyomatosis (LAM), and a variety of unusual visceral, intra-abdominal and soft tissue/bone tumors, described under the terms “clear cell myomelanocytic tumor of the falciform ligament/ligamentum teres” (CCMMT), “abdominopelvic sarcoma of perivascular epithelioid cells” and “primary

extrapulmonary sugar tumor” (PEST), among others. There is a strong association between PEComas and the tuberous sclerosis complex (TSC).

Perivascular epithelioid cells

PEC are characterized by perivascular location, often with a radial arrangement of cells around the vascular lumen. Careful examination of PEComas will invariably reveal diagnostic blood vessels, in which the PEC appear to comprise the muscular wall, replacing the normal smooth muscle and collagen. Typically, the cells in an immediate perivascular location are most epithelioid and spindled cells resembling smooth muscle are seen away from vessels. PEC may accumulate large amounts of lipid, mimicking adipocytes or lipoblasts; such cells are usually found away from the blood vessels. Great variation is seen in the relative proportion of epithelioid, spindled and lipid-distended cells, accounting for their potential confusion with carcinomas, smooth muscle tumors and adipocytic tumors. PEC have clear to lightly eosinophilic cytoplasm, rather than the dense eosinophilia of true smooth muscle cells. Occasionally, PEC show a perinuclear eosinophilic zone, with surrounding clear cell change. They typically have small, centrally placed, normochromatic, round to oval nuclei with small nucleoli, although striking hyperchromasia and nuclear irregularity may be present.

“Cell of Origin”

No normal counterpart to the PEC has ever been identified in any organ.

Historical Timeline

- 1900: First use of term “angiomyolipoma” (Grawitz).
- 1911: Association between TSC and renal AML noted (Fischer).
- 1937: First description of LAM (Burrell and Ross).
- 1951: Complete histopathological description of AML (Morgan et al).
- 1963: CCST described (Liebow and Castleman).
- 1968: Term “lymphangiomyomatosis” coined (Frack et al).
- 1973: Association between LAM and TSC noted (Valensi).
- 1974: Association of AML and LAM described (Monteforte and Kohnen)
- 1976: Hepatic AML described (Ishak).
- 1988: Report of CCST with hepatic metastases (Sale and Kulander).
- 1991: Report of sarcomatous renal AML with lung metastases (Ferry et al).
- 1991: HMB-45 positivity and ultrastructural confirmation of pre-melanosomes in AML (Weeks and Malott, Pea et al) and in CCST (Gaffey et al).
- 1992: Term “perivascular epithelioid cell” coined (Bonetti et al).
- 1993: HMB-45 positivity in LAM described (Chan et al).
- 1994: Dopa oxidase expression identified in AML, confirming melanogenesis (Kaiserling et al).
- 1994: Second report of sarcomatous AML with lung metastases (Abdulla et al).
- 1994: LOH for TSC 1 and TSC2 demonstrated in AML (Green et al)
- 1996: Clonality demonstrated in AML (Green et al).
- 1996: CCST of pancreas reported (Zamboni et al).
- 1997: Epithelioid AML described (Eble et al).
- 1997: CCST reported in association with LAM in a patient with TSC (Flieder and Travis).
- 1999: CCST/LAM hybrid reported (Hironaka and Fukayama).
- 1999: Epithelioid hepatic AML described (Tsui et al).
- 1999: Clonal alternations noted in AML by CGH.
- 2000: Multiple reports of histologically and clinically malignant AML (Martignoni et al, Dalle et al, Radin and Ma, Ribalta et al).
- 2000: Clear cell myomelanocytic tumor of the falciform ligament described (Folpe et al, Tanaka et al).
- 2000: Report of uterine PEComas (Michal and Zamecnik).
- 2001: Monotypic AML of nasal cavity reported (Banerjee et al).
- 2001: PEComas (5 malignant, 3 benign) reported in ileum, rectum, pelvis, vulva, atrial septum (Bonetti et al, Tazelaar et al).
- 2002: Second series of uterine PEComas (Vang and Kempson).
- 2002: PEComas reported in thigh (Folpe et al), breast (Govender et al), bone (Insabato et al).
- 2003: PEComas reported in thigh (Diment and Colecchia), uterus (Greene et al), bladder (Pan et al).

Clinical Features

AML is the most common PEComa, with a reported prevalence of 0.13% in healthy adults. Renal AML are found in approximately 48% of patients known to have tuberous sclerosis complex (TSC). The presence of multiple AML is diagnostic of TSC. However, approximately 80% of patients with AML do not have TSC. The prevalence of LAM is very low, with an estimated 1000 affected patients in the United States in 2001. Between 0.1 and 2.3 % of TSC patients develop LAM.

Approximately 47% of patients with LAM will also develop AML's. CCST is extremely rare, with only approximately 40 reported cases. CCST has been reported in association with LAM and TSC. PEComas at other sites are extremely uncommon and are only very rarely associated with TSC.

Renal AML have a mean age of diagnosis of 45-55 years for non-TSC patients and 25-35 for TSC patients. Males outnumber females by 4:1. For unknown reasons, hepatic AML are far more common in women than in men. LAM occurs almost exclusively in women, with a mean age at presentation in the early 30's, although exceptional cases have been documented in men. CCST show a slight female predominance, with a mean age at presentation of 57 years. CCMMT usually occur in young girls, with a mean age at diagnosis of 11 years. Uterine PEComas have a mean age at diagnosis of 54 years. Almost all other reported PEComas have been in women, with a wide age range.

Histopathology

AML usually present as expansile, non-infiltrative masses, which may have extensive hemorrhage. Classic AML shows triphasic histology, with tortuous, thick-walled blood vessels, irregularly arranged sheets and bundles of myoid-appearing PEC, and lipid-distended PEC (so-called "adipocytes"). Both thick-walled vessels with walls composed of PEC and vessels with normal smooth muscle wall are present in AML; the latter most likely represent in-growth of normal host blood vessels. Cases with relative predominance of the myoid-appearing or lipid-distended PEC may be mistaken for smooth muscle or adipocytic tumors, respectively. Occasional cases of AML may show striking cytologic atypia, multinucleation, mitotic activity and focal necrosis ("atypical AML"). AML may also show almost exclusively epithelioid morphology ("epithelioid AML") and mimic carcinoma. Cases described as epithelioid AML with clear cell change and extra-pulmonary CCST appear to represent the same entity, and their distinction is arbitrary.

In the lung, LAM consists of a proliferation of myoid-appearing PEC distributed around bronchial lymphatics, interlobular septae and pleura. Rare cases show prominent clear cell change, giving the appearance of multiple CCST arranged in a LAM-like distribution. LAM of lymph nodes or the thoracic duct is characterized by a perilymphatic proliferation of PEC.

Pulmonary CCST are peripherally located, unencapsulated tumors composed of typical

PEC arrayed around thin-walled vessels. Entrapment of alveoli is seen. Extra-pulmonary CCST may entirely resemble their pulmonary counterparts, but often display nuclear atypia, mitotic activity and necrosis.

As originally described, CCMMT differs somewhat from other PEComas in that it is predominantly a spindle cell lesion. CCMMT consists of relatively uniform, moderate sized cells arranged in fascicles and nests, arranged around an elaborate capillary network, reminiscent of renal cell carcinoma. The histologic features of CCMMT, CCST and epithelioid AML show great overlap, supporting the view that these are simply morphologic variants of a single pathologic entity.

Immunohistochemistry

The PEC is characterized by co-expression of melanocytic markers, such as gp 100 protein (mAb HMB-45), Melan-A, tyrosinase, and microphthalmia transcription factor, and muscle markers, such as smooth muscle actin, pan-muscle actin, muscle myosin and calponin. Desmin is less often positive and cytokeratin and S100 protein are usually absent. It should be recognized, however, that some PEComas do express S100 protein, and this finding does not exclude this diagnosis. The most sensitive melanocytic markers for the diagnosis of PEComa are HMB-45, Melan-A and microphthalmia transcription factor. In AML, co-expression of melanocytic and smooth muscle markers is seen in both myoid-appearing and lipid-distended PEC,

confirming the unitary nature of these two morphologic variants. As a general rule, exclusively epithelioid tumors tend to express melanocytic markers more strongly than myoid markers, with the opposite found in predominantly spindled PEComas.

Genetics

The genes involved in TSC are TSC1 on chromosome 9q34 and TSC2 on chromosome 16p13.3. The protein products of TSC1, hamartin, and TSC2, tuberlin, function as tumor suppressors and loss of heterozygosity at these loci and absence of their associated proteins has been shown in both TSC-associated and sporadic AML and LAM. A small number of CCMMT have also been shown to lack tuberlin expression. Although AML was previously considered a hamartoma, recent evidence including cytogenetic demonstration of clonal abnormalities, comparative genetic hybridization studies, and X-chromosome inactivation studies strongly supports its neoplastic origin.

Prognosis

Clear criteria for malignancy in PEComas have not been elaborated. It is widely acknowledged that AML may show striking atypical features, as described above, but behave in a benign fashion. The difficulty in confidently recognizing malignancy in AML is compounded by the well-known existence of multicentric AML and AML arising in lymph nodes. It appears fair to state that classic triphasic AML are invariably benign, even in the presence of atypical cytologic features. However, clinically malignant (i.e.,

metastatic) AML, usually of the epithelioid type, have been convincingly documented. Malignant PEComas with both sarcoma-like and carcinoma-like histology have been reported to arise in pre-existing benign AML. Clinically malignant pulmonary and extra-pulmonary CCST have been reported. On the basis of these prior reports, it appears that PEComas displaying any combination of infiltrative growth, marked hypercellularity, nuclear enlargement and hyperchromasia, high mitotic activity, atypical mitotic figures, and coagulative necrosis should be regarded as malignant. Malignant PEComas are aggressive sarcomas that frequently result in the death of affected patients.

Conclusions

Although AML has been known for quite some time, it has only recently become clear that it is part of a family of tumors that may arise in essentially any location in the body. The members of this remarkable family of tumors, now known as PEComas, are characterized by the distinctive morphology of their constituent PEC, and by their unusual "myomelanocytic" immunophenotype. Although it had been thought that all AML and related lesions were benign, it is increasingly obvious that many PEComas are both histologically and clinically malignant. With the discovery of the genetic underpinnings of TSC and the TSC-related tumors, it is anticipated that further study will greatly increase our understanding of the pathogenesis of the PEComas.

Selected References

1. Folpe AL. Tumors of the perivascular epithelioid cell (PEComas). In: Fletcher C.D.M., Unni K.K., Mertens F. (Eds.): World Health Organization Classification of Tumors. Pathology and Genetics of Tumors of Soft tissue and Bone. IARC Press: Lyon 2002.
2. Bonetti F, Pea M, Martignoni G, Zamboni G. PEC and sugar [letter]. American Journal of Surgical Pathology 1992;16(3):307-8.
3. Gomez MR. Phenotypes of the tuberous sclerosis complex with a revision of diagnostic criteria. Ann N Y Acad Sci 1991;615:1-7.
4. Kelly J, Moss J. Lymphangiomyomatosis. Am J Med Sci 2001;321(1):17-25.
5. Eble JN. Angiomyolipoma of kidney. Semin Diagn Pathol 1998;15(1):21-40.
6. Tsui WM, Colombari R, Portmann BC, Bonetti F, Thung SN, Ferrell LD, et al. Hepatic angiomyolipoma: a clinicopathologic study of 30 cases and delineation of unusual morphologic variants. American Journal of Surgical Pathology 1999;23(1):34-48.
7. Folpe AL, Goodman ZD, Ishak KG, Paulino AF, Taboada EM, Meehan SA, et al. Clear cell myomelanocytic tumor of the falciform ligament/ligamentum teres: a novel member of the perivascular epithelioid clear cell family of tumors with a predilection for children and young adults. Am J Surg Pathol 2000;24(9):1239-46.

8. Vang R, Kempson RL. Perivascular Epithelioid Cell Tumor ('PEComa') of the Uterus: A Subset of HMB-45-Positive Epithelioid Mesenchymal Neoplasms With an Uncertain Relationship to Pure Smooth Muscle Tumors. *Am J Surg Pathol* 2002;26(1):1-13.
9. Bonetti F, Martignoni G, Colato C, Manfrin E, Gambacorta M, Faleri M, et al. Abdominopelvic sarcoma of perivascular epithelioid cells. Report of four cases in young women, one with tuberous sclerosis. *Mod Pathol* 2001;14(6):563-8.
10. Tazelaar HD, Batts KP, Srigley JR. Primary extrapulmonary sugar tumor (PEST): a report of four cases. *Mod Pathol* 2001;14(6):615-22.
11. L'Hostis H, Deminiere C, Ferriere JM, Coindre JM. Renal angiomyolipoma: a clinicopathologic, immunohistochemical, and follow-up study of 46 cases. *American Journal of Surgical Pathology* 1999;23(9):1011-20.
13. Eble JN, Amin MB, Young RH. Epithelioid angiomyolipoma of the kidney: a report of five cases with a prominent and diagnostically confusing epithelioid smooth muscle component. *American Journal of Surgical Pathology* 1997;21(10):1123-30.
14. Gaffey MJ, Mills SE, Askin FB, Ross GW, Sale GE, Kulander BG, et al. Clear cell tumor of the lung. A clinicopathologic, immunohistochemical, and ultrastructural study of eight cases. *Am J Surg Pathol* 1990;14(3):248-59.
15. Chan JK, Tsang WY, Pau MY, Tang MC, Pang SW, Fletcher CD. Lymphangiomyomatosis and angiomyolipoma: closely related entities characterized by hamartomatous proliferation of HMB-45-positive smooth muscle [see comments]. *Histopathology* 1993;22(5):445-55.
16. Bonetti F, Pea M, Martignoni G, Doglioni C, Zamboni G, Capelli P, et al. Clear cell ("sugar") tumor of the lung is a lesion strictly related to angiomyolipoma--the concept of a family of lesions characterized by the presence of the perivascular epithelioid cells (PEC). *Pathology* 1994;26(3):230-6.
17. Weeks DA, Malott RL, Arnesen M, Zuppan C, Aitken D, Mierau G. Hepatic angiomyolipoma with striated granules and positivity with melanoma--specific antibody (HMB-45): a report of two cases. *Ultrastructural Pathology* 1991;15(4-5):563-71.
18. Zavala-Pompa A, Folpe AL, Jimenez RE, Lim SD, Cohen C, Eble JN, et al. Immunohistochemical study of microphthalmia transcription factor and tyrosinase in angiomyolipoma of the kidney, renal cell carcinoma, and renal and retroperitoneal sarcomas: comparative evaluation with traditional diagnostic markers. *Am J Surg Pathol* 2001;25(1):65-70.
19. Pea M, Bonetti F, Martignoni G, Henske EP, Manfrin E, Colato C, et al. Apparent renal cell carcinomas in tuberous sclerosis are heterogeneous: the identification of malignant epithelioid angiomyolipoma.

American Journal of Surgical Pathology
1998;22(2):180-7.

20. Cibas ES, Goss GA, Kulke MH, Demetri GD, Fletcher CD. Malignant epithelioid angiomyolipoma ('sarcoma ex angiomyolipoma') of the kidney: a case report and review of the literature. *Am J Surg Pathol* 2001;25(1):121-6.

21. Ferry JA, Malt RA, Young RH. Renal angiomyolipoma with sarcomatous transformation and pulmonary metastases. *Am J Surg Pathol* 1991;15(11):1083-8.

22. van Slegtenhorst M, de Hoogt R, Hermans C, Nellist M, Janssen B, Verhoef S, et al. Identification of the tuberous sclerosis gene TSC1 on chromosome 9q34. *Science* 1997;277(5327):805-8.

23. Anonymous. Identification and characterization of the tuberous sclerosis gene on chromosome 16. The European Chromosome 16 Tuberous Sclerosis Consortium. *Cell* 1993;75(7):1305-15.
suppressor. *Human Molecular Genetics* 1994;3(10):1833-4.

24. Yu J, Astrinidis A, Henske EP. Chromosome 16 loss of heterozygosity in tuberous sclerosis and sporadic lymphangiomyomatosis. *Am J Respir Crit Care Med* 2001;164(8 Pt 1):1537-40.

25. Kattar MM, Grignon DJ, Eble JN, Hurley PM, Lewis PE, Sakr WE, et al. Chromosomal analysis of renal angiomyolipoma by comparative genomic hybridization: evidence for clonal origin. *Human Pathology* 1999;30(3):295-9.

26. Cheng L, Gu J, Eble JN, Bostwick DG, Younger C, MacLennan GT, et al. Molecular genetic evidence for different clonal origin of components of human renal angiomyolipomas. *Am J Surg Pathol* 2001;25(10):1231-6.

27. Green AJ, Sepp T, Yates JR. Clonality of tuberous sclerosis hamartomas shown by non-random X-chromosome inactivation. *Human Genetics* 1996;97(2):240-3.

THE MANY FACES OF OSTEOSARCOMA

Andrew Rosenberg MD
Massachusetts General Hospital, Boston, MA

**Advantages and Pitfalls of Cytogenetic, Molecular
Cytogenetic, and Molecular Diagnostic Testing in Bone
and Soft Tissue Tumors**

Julia A. Bridge, M.D.

International Society of Bone and Soft Tissue Pathology
2004

INTRODUCTION

The pathogenesis of bone and soft tissue tumors is a multistep process stemming from somatic mutations that impair the regulation of normal cell development, cell proliferation, and other fundamental cellular activities. The elucidation of this process has been challenging because the genetic events are unique for different mesenchymal tumor subtypes. However, enormous progress has been achieved with the advancement of cytogenetic and molecular genetic techniques. As a result, relevant oncogenes and tumor suppressor genes have been identified and localized, and new gene constructs and their protein products that result from translocations during sarcomagenesis have been determined. The identification of tumor-specific genetic markers for bone and soft tissue tumors such as Ewing sarcoma has added a new dimension to the formulation of a diagnosis and the resolution of cellular origin. Many of the genetic markers appear to have prognostic value, and studies are under way to determine their potential applications as specific therapeutic targets.

GENETIC APPROACHES COMMONLY USED AS DIAGNOSTIC AIDS

CYTOGENETIC ANALYSIS

Specimen Requirements

Tissue submitted for cytogenetic analysis must be fresh (not frozen or fixed in formalin) because living, dividing cells are required. A mesenchymal tumor sample submitted for cytogenetic analysis should be representative of the neoplastic process and preferably be part of the specimen submitted for pathologic study. Ideally, a 1 to 2 cm³ (approximately 0.5 to 1.0 g) fresh sample is provided for analysis. Also, small biopsy specimens or fine-needle aspirates (less than 500 mg) can be analyzed successfully, but prolonged culture may be needed to produce enough cells for examination. Necrotic tissue and nonneoplastic tissue should be dissected from the sample. The tumor tissue should be transported to the laboratory in sterile culture media or buffer solution (such as Hank's buffered salt solution) as soon as possible after surgical removal. Specimens sent over long distances (requiring 24 to 48 hours for delivery) to cytogenetic laboratories can be transported at room temperature or refrigerated (not frozen) in sterile isotonic saline or, preferably, culture media containing serum.

Cell Culture and Chromosome Banding

The basic process of cell culturing is the same for all bone and soft tissue lesions. Briefly, sterile tumor tissue is minced mechanically with scissors or a scalpel and enzymatically disaggregated by incubation in collagenase (24). The resulting single cells and small cell clusters are incubated at 37°C and 5 percent CO₂ and are inspected daily under an inverted microscope for growth. When an optimal number of mitoses is observed, the proliferating cells are arrested in mid-division. The time that a bone or soft tissue tumor may be cultured to attain satisfactory karyotypic findings varies depending on the histopathologic type, grade of tumor, tumor cellularity, and size of specimen submitted for analysis. A short-term culture usually results in a sufficient number of mitoses in 10 days or less. Lengthy culture times should be avoided because undesired overgrowth by normal fibroblasts is more likely to occur.

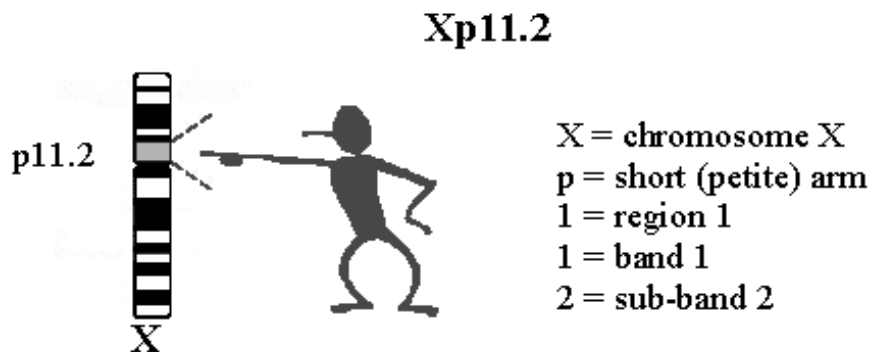
An alternative to tissue culture is direct harvest. With this technique, endemic dividing cells are arrested after a 1- to 12-hour incubation in colchicine and culture medium. This method is useful for obtaining fast or preliminary results but is limited by the *in vivo* mitotic index. Thus, direct harvest is most useful for high-grade tumors. Also, for best success, it is imperative that the laboratory receive the tissue sample within 1 hour after biopsy.

Chromosomes, as they appear in a metaphase spread, consist of tightly coiled DNA and protein. A karyotype is the somatic chromosomal complement of an individual or species. For humans, the normal karyotype consists of 46 chromosomes aligned in a standard sequence according to size, centromere location, and banding pattern. G-banding is the most common form of banding. This is attributable to the relative ease of performing the technique, the reliability of the results, and the permanence of the preparations. G-bands can be obtained with Giemsa or Wright stains pretreated with

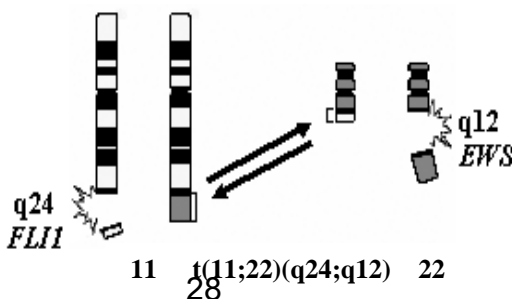
trypsin or phosphate buffer, respectively. The number of alternating light and dark bands detectable with G-banding in the haploid genome varies with the level of chromosomal contraction in each metaphase cell, but it is in the range of 350 to 550 bands per haploid set. One band represents approximately 5 to 10×10^6 base pairs (bp) of DNA. A relationship exists between the different types of bands and gene density, base composition, and replication time; however, the functional basis for the interdependence of these features of chromosome structure and behavior is not known.

Nomenclature

An international system for designating bands in human chromosomes was introduced at the 1971 conference in Paris. In this system, the short and long arms are divided into several regions, each defined as an area of chromosome lying between two adjacent landmarks. Landmarks are defined as consistent and distinct morphologic features important for identifying chromosomes. (Strictly, landmarks, like bands, are features of staining rather than morphologic features.) Regions are numbered consecutively from the centromere to the telomere (distal end of a chromosome) on each arm; within each region, the individual bands are numbered in the same direction. Thus, the complete designation of a band consists of the chromosome number, a letter to indicate the short or long arm, a number for the region, and a number for the band and subband; for example, Xp11.2 refers to the short arm of chromosome X, region 1, band 1, subband 2.



The two major types of chromosomal abnormalities are numerical and structural. Numerical abnormalities manifest as changes in complete sets of chromosomes (i.e., triploid [3N] or tetraploid [4N] complements) or in the number of individual chromosomes (i.e., loss of a single chromosome [monosomy] or gain of a single chromosome [trisomy]). Structural abnormalities of chromosomes result from chromosomal breakage and rejoining of the broken ends to form new combinations. A frequently observed structural abnormality is translocation. In a reciprocal translocation, chromosomal material is exchanged between two or more nonhomologous chromosomes. An example of the shorthand system used to describe numerical and structural aberrations is $47,XY,+8,t(11;22)(q24;q12)$, in which 47 indicates the total chromosome number, XY indicates the sex constitution, and +8 indicates an extra copy, trisomy, of chromosome 8. The “t” is an abbreviation for translocation and in this example specifies an exchange of chromosomal material between the long arms of chromosomes 11 and 22 at bands q24 and q12, respectively. The 11;22 translocation is a characteristic rearrangement in Ewing sarcoma, and trisomy 8 is a frequent secondary anomaly in this neoplasm.



Advantages and Limitations of Conventional Cytogenetic Analysis

Table 1: Conventional Cytogenetic Analysis

Advantages	Limitations
Provides global information in a single assay. <ul style="list-style-type: none"> • includes primary & secondary anomalies • knowledge of anticipated anomaly or histologic diagnosis not necessary 	Requires fresh tissue. <ul style="list-style-type: none"> • although direct preparations can be performed, cell culture is typically required (1-10 days).
Variants undetectable by interphase FISH or RT-PCR may be uncovered.	<ul style="list-style-type: none"> • may encounter complex karyotypes with suboptimal morphology. • submicroscopic or cryptic rearrangements may result in a false negative result.
Diagnostically useful. <ul style="list-style-type: none"> • sensitive and specific • can be performed on fine needle aspirates 	Normal karyotypes may be observed following therapy-induced tumor necrosis or overgrowth of normal supporting stromal cells.
Provides direction for molecular studies of pathogenetically important genes.	Difficulties encountered with bone tumors include low cell density and the release of cells from the bone matrix.

MOLECULAR CYTOGENETICS

A revolutionary tool in the analysis and characterization of chromosomes and chromosomal abnormalities has been the development of in situ hybridization (ISH) techniques. Hybridization refers to the binding or annealing of complementary DNA or RNA sequences that serve as probes. With this approach, specific nucleic acid sequences can be detected in morphologically preserved chromosomes, cells, or tissue sections.

Molecular cytogenetic assays typically are performed with chromosome-specific probes labeled with fluorescent dyes such as fluorescein and rhodamine and detected with fluorescence microscopy (fluorescence in situ hybridization [FISH]). Alternatively, hybridization signals can be detected with peroxidase or alkaline phosphatase, but these approaches are generally less sensitive.

Specimen Requirements

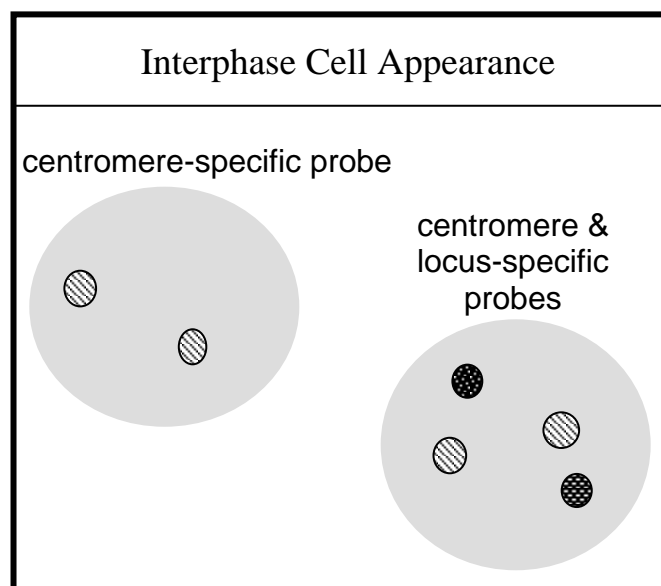
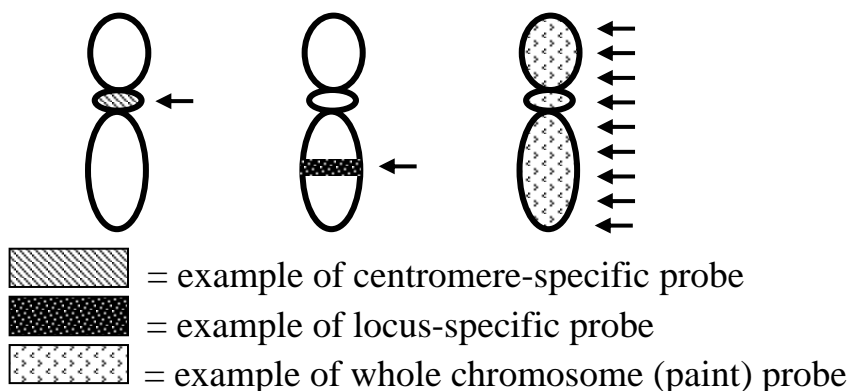
This technique can be performed on fresh or aged samples (such as blood smears, touch imprint cytologic preparations, or cytospin preparations), paraffin-embedded tissue sections, and disaggregated cells retrieved from fresh, frozen, or paraffin-embedded material. Blood smears, touch imprint cytologic preparations, and cytospin preparations are air-dried and subsequently fixed in methanol:glacial acetic acid (3:1) for 5 minutes. To visualize an anomaly within a specific region of a tumor or within a specific cell type, a 4- to 6- μm -thick paraffin-embedded tissue section can be used. Analysis of thin sections, however, is limited because portions of most nuclei are lost during sectioning, and this may lead to false-positive results in the evaluation of chromosomal deletions or losses. For the most accurate assessment of subtle aneuploidy changes, the preferred approach is to obtain whole or intact nuclei by disaggregating and releasing cells from a much thicker (50 to 60 μm) section. FISH is a same day or overnight procedure, depending on the probes used or the type of specimen analyzed (or both).

Probes

Chromosomal probes (complementary DNA sequences) frequently used to examine bone and soft tissue tumors can be divided into three categories:

- Centromere-specific
tandemly repeated monomers or α -satellite sequences (171 bp) that are unique for each chromosome. Useful for chromosome enumeration.
- Locus-specific
single copy probes homologous to specific targets (15- >500 kb). Often used for assessing oncogenes or tumor suppressor genes.
- “Paint” or whole chromosome
comprised of probe mixtures with homology at multiple sites along the target chromosomes. Useful for characterizing structural chromosomal anomalies.

Chromosome Probe Examples



Technical variations

Conventional karyotyping is limited by its inability to detect cryptic translocations or to identify marker chromosomes accurately. With recently developed universal chromosome painting techniques, all chromosomes can be analyzed simultaneously. Two similar approaches have been developed: spectral karyotype analysis (SKY) and multifluor fluorescence in situ hybridization (M-FISH). Both techniques are based on the principle that the differential display of colored fluorescent chromosome-specific paints provides a complete analysis of the human chromosomal complement. With the use of combinations of 23 different colored paints as a “cocktail probe,” subtle differences in fluorochrome labeling profiles after hybridization with the cocktail probe allow the computer to assign a unique color to each chromosome pair. Thus, abnormal chromosomes in the karyotype of a tumor can be identified by the pattern of color distribution along the axis of the chromosome so that rearrangements between different chromosomes lead to a distinct transition from one color to another at the position of the breakpoint, greatly facilitating the identification of subtle or cryptic rearrangements. This technique is suited particularly to solid tumors in which the complexity of the karyotypes may often mask the presence of recurrent chromosomal aberrations.

Advantages and Limitations of Molecular Cytogenetic Analysis

Table 2: Molecular Cytogenetic Analysis

Advantages	Limitations
Can be performed on metaphase or interphase cell preparations (fresh, frozen or paraffin-embedded material). <ul style="list-style-type: none"> • can localize anomaly within specific cells or tissue types 	More targeted approach; not screening tool (generally requires prior knowledge of anomaly of interest). <ul style="list-style-type: none"> • exceptions would be CGH & SKY
Can provide results when tissue is insufficient or unsatisfactory for cytogenetic analysis, when conventional cytogenetics has failed to yield results or when cryptic rearrangements are present.	Still a relatively gross approach when contrasting other molecular approaches capable of detecting single base mutations.
Diagnostically useful. <ul style="list-style-type: none"> • sensitive and specific 	<ul style="list-style-type: none"> • requires fluorescence microscopy (signal fading). • interpretation may be challenging when analyzing suboptimal specimens (i.e., background fluorescence or autofluorescence, particularly with paraffin-embedded material).
Rapid turn-around time.	FISH nomenclature not consistent among laboratories.

REVERSE TRANSCRIPTION – POLYMERASE CHAIN REACTION ANALYSIS (RT-PCR)

Translocations, or exchange of chromosomal material between two or more nonhomologous chromosomes, are encountered frequently as tumor-specific anomalies in mesenchymal neoplasms. These tumor-specific translocations serve as important guides for molecular biologists conducting positional cloning studies of the genes at the translocation breakpoints. The most common genetic consequence of these translocation events is the fusion of two genes, one from each translocation partner, resulting in the formation of a chimeric gene. The fusion proteins encoded by these chimeric genes are not found in normal cells and are tumor-specific.

In sarcomas, the fusion genes most often code for aberrant transcription factors that result in inhibition of normal cellular differentiation, cell cycle activation, and loss of responsiveness to extracellular signals (Table 3). Note that new cytogenetic as well as molecular genetic variants continue to be defined. Cytogenetic variants are defined as differing chromosomal translocation partners [i.e. t(1;13) and t(2;13) in alveolar rhabdomyosarcoma] and molecular variants are often the result of genomic breakpoint differences that lead to distinct fusion product exon combinations. For example, the two most frequent exon combinations in Ewing sarcoma-associated *EWS/FLI1* fusion transcripts include fusion of *EWS* exon 7 to *FLI1* exon 6 (type 1) and fusion of *EWS* exon 7 to *FLI1* exon 5 (type 2). These molecular variants can be detected by their unique RT-PCR product band size. The identity of less common or unexpected product band sizes should be confirmed utilizing additional approaches such as direct sequencing or digestion with specific restriction endonucleases.

Table 3: Characteristic and Variant Chromosomal Translocations and Associated Fusion Genes in Bone and Soft Tissue Sarcomas

Neoplasm	Translocation	Fusion gene(s)
Alveolar soft part sarcoma ^a	t(X;17)(p11.2;q25.3)	<i>TFE3/ASPL</i>
Alveolar rhabdomyosarcoma	t(2;13)(q35;q14) t(1;13)(p36;q14) t(X;2)(q13;q35)	<i>PAX3/FKHR</i> <i>PAX7/FKHR</i> <i>PAX3/AFX</i>
Clear cell sarcoma	t(12;22)(q13;q12)	<i>EWS/ATF1</i>
Congenital fibrosarcoma ^b	t(12;15)(p13;q25)	<i>ETV6/NTRK3</i>
Dermatofibrosarcoma protuberans	t(17;22)(q22;q13)	<i>COL1A1/PDGFB</i>
Epithelioid hemangioendothelioma	t(1;3)(p36;q25)	?
Ewing sarcoma/pPNET	t(11;22)(q24;q12) t(21;22)(q22;q12) t(7;22)(q22;q12) t(17;22)(q21;q12) t(2;22)(q33;q12) inv(22)(q12q12)	<i>EWS/FLI1</i> <i>EWS/ERG</i> <i>EWS/ETV1</i> <i>EWS/EIAP</i> <i>EWS/FEV</i> <i>EWS/ZSG</i>
Extraskeletal myxoid chondrosarcoma	t(9;22)(q22-31;q12) t(9;17)(q22;q11)	<i>EWS/CHN^c</i> <i>TAF2N/CHN</i>
Malignant hemangiopericytoma	t(12;19)(q13;q13)	?
Myxoid/round cell liposarcoma	t(12;16)(q13;p11) t(12;22)(q13;q12)	<i>TLS^d/CHOP</i> <i>EWS/CHOP</i>
Synovial sarcoma	t(X;18)(p11.2;q11.2) t(X;20)(p11.2;q13.3) ^e	<i>SYT/SSX1</i> <i>SYT/SSX2</i> <i>SYT/SSX4</i> <i>SSI8LI/SSX1^e</i>

^aThis translocation is seen also in a subset of pediatric renal neoplasms.

^bThis translocation is seen also in congenital mesoblastic nephromas.

^cAlso referred to as *TEC*.

^dAlso referred to as *FUS*.

^eThe *SSI8LI* gene localized to chromosome 20 shows strong homology to *SSI8* (*SYT*). Storlazzi et al. *Genes Chromosom Cancer* 37:195-200, 2003.

Specimen Requirements

The highly specific gene rearrangements that occur from chromosomal translocation in bone and soft tissue tumors can be identified with reverse transcriptase polymerase chain reaction (RT-PCR) analysis. The PCR technique uses specific synthetic primers to amplify a section of a gene in vitro. With the additional step of reverse transcription (mRNA → cDNA), PCR can be carried out on RNA. Snap frozen tissue is preferred for RNA extraction and RT-PCR analysis, but this procedure can also be performed on archival (paraffin-embedded) material if the RNA is of sufficient quality.

RT-PCR analysis is remarkably sensitive. It may allow for the detection of abnormalities present in cells too few to be identified with traditional cytogenetic or FISH methods. It may be suitable for the detection or monitoring of minimal residual disease. Also, RT-PCR analysis is not dependent on successful cell culture and, similar to FISH, it is rapid, with a short turnaround time. Compared with

cytogenetic analysis, the greatest disadvantage of RT-PCR analysis is the inability to detect chromosomal anomalies other than those for which the test was designed. With conventional cytogenetic analysis, all major chromosomal abnormalities, including those not initially anticipated by the clinician or laboratorian, may be uncovered.

Advantages and Limitations of RT-PCR Analysis

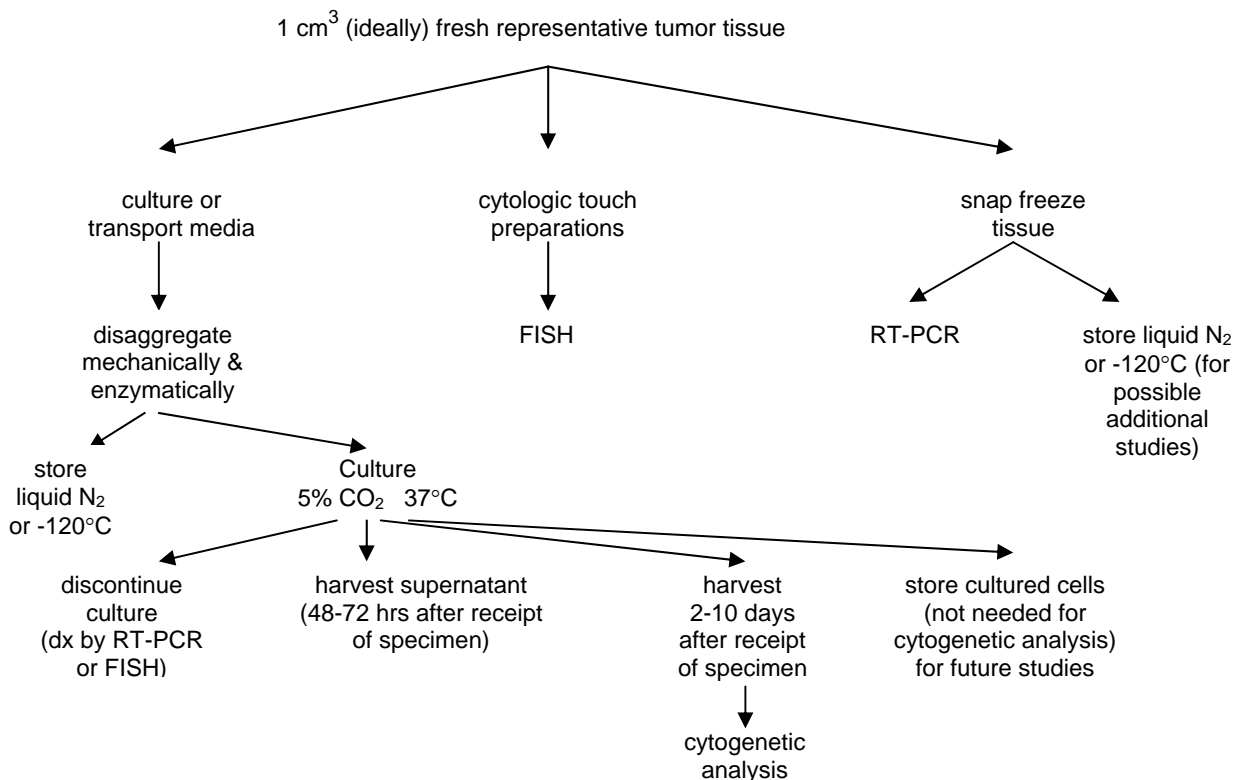
Table 4: RT-PCR Analysis

Advantages	Limitations
Can be performed on fresh, frozen or paraffin-embedded material. <ul style="list-style-type: none"> tissue quantity requirement is small 	Not all sarcomas exhibit characteristic fusion gene transcripts.
Can provide results when tissue is insufficient or unsatisfactory for cytogenetic analysis, when conventional cytogenetics has failed to yield results or when cryptic rearrangements are present.	Targeted approach; not screening tool. <ul style="list-style-type: none"> requires prior knowledge of fusion transcript.
Diagnostically useful. <ul style="list-style-type: none"> sensitive and specific rapid turn-around-time. 	RNA quality may be inadequate secondary to RNA degradation.
Because of its remarkable sensitivity, RT-PCR may be useful for the detection of minimal residual disease or early relapsed disease.	<ul style="list-style-type: none"> devised primer sets may not detect unusual molecular variants (false negative). identification of some product bands may require validation by additional approaches such as direct sequencing, transfer and hybridization with internal oligonucleotide probes, digestion with specific restriction endonucleases, or re-amplification with internal primers (nested RT-PCR).

CONCLUSIONS

Dramatic advances in cytogenetic and molecular biologic techniques have furthered our understanding of sarcomagenesis. Cytogenetic and molecular genetic assays have a direct, potentially decisive role in the examination of bone and soft tissue tumors, and many such assays are used routinely for diagnostic and prognostic purposes in molecular pathology laboratories. However, genetic analysis is not a panacea for histopathologic study, but rather it is a powerful adjunct to complement conventional microscopy and radiographic assessment in the formulation of an accurate diagnosis. By virtue of their exquisite sensitivity, molecular techniques appear superior to standard methods in the assessment of minimal residual disease or early relapse of disease. Future advancements will include the development of a new class of antineoplastic agents based on the underlying biologic events in bone and soft tissue sarcomas for the clinical management of these malignancies.

Summary: Recommended Processing of Tissue for Genetic Analyses (Algorithm Approach)



REFERENCES

- Barr FG et al. Molecular assays for chromosomal translocations in the diagnosis of pediatric soft tissue sarcomas. *JAMA* 273:553-7, 1995.
- Bridge JA, Orndal C. Cytogenetic analysis of bone and joint neoplasms. In: T. Helliwell (ed), Pathology of Bone and Joint Neoplasms, W.B. Saunders Co., Philadelphia, 1999, pp 59-78.
- Bridge JA, Sandberg AA. Cytogenetic and molecular genetic techniques as adjunctive approaches in the diagnosis of bone and soft tissue tumors. *Skel Radiol* 29:249-58, 2000.
- Epstein RJ. Gene and protein analysis. In: Human Molecular Pathology, Cambridge University Press, 2003.
- Gersen SL, Keagle MB. The Principles of Clinical Cytogenetics. Humana Press, New Jersey, 1999.
- Kushner BH et al. Clinically critical impact of molecular genetic studies in pediatric solid tumors. *Med Pediatr Oncol* 33:530-5, 1999.
- Kwok S et al. Avoiding false positive with PCR. *Nature* 339:237-8, 1989.
- Ladanyi M, Bridge JA. Contribution of molecular genetic data to the classification of sarcomas. *Hum Pathol* 31:532-8, 2000.
- Mark, HFL. Medical Cytogenetics. Marcel Dekker, Inc., New York, 2000.
- Mascarello JT et al. As currently formulated, ISCN FISH nomenclature make it not practical for use in clinical test reports or cytogenetic databases. *Genet Med* 5:370-7, 2003.
- Mnicol AM, Farquharson MA. In situ hybridization and its diagnostic applications in pathology. *J Pathol* 182:250-61, 1997.
- Naito N et al. A reverse transcriptase-polymerase chain reaction assay in the diagnosis of soft tissue sarcomas. *Cancer* 89:1992-8, 2000.
- Peter M et al. A multiplex real-time PCR assay for the detection of gene fusions observed in solid tumors. *Lab Invest* 81:905-12, 2001.
- Schwartz X. Fishing for a better language. *Genet Med* 5:345-6, 2003.
- Shipley J, Fisher C. Chromosome translocations in sarcomas and the analysis of paraffin-embedded material. *J Pathol* 184:1-3, 1998.

SMOOTH MUSCLE TUMORS OF SOFT TISSUE:

Criteria of Malignancy and Prognostic Factors

Sharon W. Weiss, M.D.

Emory University School of Medicine, Atlanta, GA, USA

INTRODUCTION

The most significant question related to soft tissue smooth muscle tumors is whether one can accurately and reproducibly separate benign tumors from malignant ones. Stated in another manner, are all smooth muscle tumors of soft tissue fundamentally malignant but differ only in the degree of malignancy? Or are there two subsets, one benign and one malignant? This lecture will address the current criteria for separating leiomyomas from leiomyosarcomas and discuss prognostic factors in the latter.

SMOOTH MUSCLE DIFFERENTIATION

The initial approach to evaluating smooth muscle tumors is clearly establishing myoid (as opposed to myofibroblastic) differentiation of the cells. Differentiated smooth muscle have an elongated, fusiform shape, centrally located cylindrical nucleus occasionally indented by a clear perinuclear vacuole, and deeply eosinophilic cytoplasm due to the presence of clumps of myofilaments which are arranged parallel to the cell axis. The cells are arranged in fascicles intersecting one another at right angle. Myofilamentous material can sometimes be appreciated on hematoxylin and eosin-stained sections, but is better seen in trichrome preparations where it appears as red parallel "hairs" or "streaks extending the length of the cell. Occasionally the cytoplasm may have a "clotted" appearance due to clumped myofilamentous material. The cytoplasm of a smooth muscle cell is diffusely actin positive (alpha smooth muscle actin, muscle specific actin) and commonly desmin positive depending on the type of smooth muscle cell and level of differentiation. It should be noted in passing that desmin may be expressed anomalously by several non-myogenic neoplasms (e.g. tenosynovial giant cell tumor, angiomatoid fibrous histiocytoma, melanoma, desmoplastic small round cell tumor).³ Thus a tumor which bears little resemblance to a smooth muscle tumor should not be interpreted as such simply because desmin is present. Typically anomalous desmin is present as dot-like immunoreactivity in a cell.

In contrast myofibroblasts have an appearance intermediate between a smooth muscle cell and fibroblast.⁴ Although classically defined by ultrastructural features (modestly developed endoplasmic reticulum and peripheral myofilaments with focal densities, indented nuclei, and fibronexus junctions)⁵ they possess certain characteristic light microscopic features as well. In contrast to smooth muscle cells, they range from spindled to stellate in shape with vesicular nuclei and more lightly staining eosinophilic

cytoplasm. The immunophenotype of myofibroblasts varies depending on its functional state. However, alpha smooth muscle actin is considered the most reliable marker. It is located peripherally within myofibroblasts in a characteristic “tram track” pattern.³

LEIOMYOMAS OF DEEP SOFT TISSUE (L-DST)

The very existence of L-DST has been questioned over the years because of their apparent rarity and the fact that with long term follow up some apparent "leiomyomas" have behaved aggressively.^{6,7} However, the appearance of two recent studies of reasonable size with excellent follow up supports the view that leiomyomas of deep soft tissue exist, but they should be diagnosed cautiously using **stringent histologic criteria**.^{8,9} Criteria common to both studies were that the lesions should have **no cytological atypia and no coagulative necrosis**. Defined in this manner both studies found that mitotic activity was also usually absent. When mitotic activity is encountered it is usually present in retroperitoneal/abdominal leiomyomas for the reasons discussed. L-DST segregate into two distinct subtypes.

Somatic soft tissue leiomyomas affect the sexes equally, develop in the extremities, usually the thigh and are frequently calcified. They are composed of mature-appearing smooth muscle cells with abundant eosinophilic cytoplasm which, by definition, lack atypia and necrosis and generally are amitotic (<1mitoses/50 HPF). Follow up in 11 of 13 cases revealed no recurrence or metastasis within a follow up period of approximately 5 yr. (range 5-97 mos.).⁸

Retroperitoneal/abdominal leiomyomas occur preferentially in women during the perimenopausal period usually in the pelvic retroperitoneum. In some cases the lesions may be multiple.^{8,9} Histologically these lesions resemble uterine leiomyomas and are composed of intersecting fascicles of slender mature smooth muscle cells sometimes displaying a cord-like pattern, hydropic change, stromal hyalinization, and fatty change. These tumors are commonly positive for estrogen/progesterone receptor proteins. Unlike somatic soft tissue leiomyomas, 20% of retroperitoneal/abdominal leiomyomas display low levels of mitotic activity (1-5/50 HPF). Despite this feature, less than 10% of lesions recur and none has metastasized in follow up periods averaging from 42-142 mos.^{7,8} The striking female predilection of this type of leiomyoma suggests they arise from hormonally sensitive smooth muscle and are functionally similar to uterine leiomyomas. Like uterine leiomyomas mitotic activity probably does not signify malignancy in the absence of other adverse histologic parameters (e.g. atypia, coagulative necrosis). The location of these lesions and the fact that many women have had hysterectomies years previously suggests that these are not simply detached or parasitic uterine leiomyomas.⁸

SOFT TISSUE LEIOMYOSARCOMA

Leiomyosarcomas can be divided into several subgroups: cutaneous, major vessel, and soft tissue.² Cutaneous lesions are a distinct clinicopathologic entity that arise from pilar structures and when restricted to the dermis have an excellent prognosis with little or no risk of dissemination. Major vessel leiomyosarcoma (e.g. inferior vena cava, renal vein) are extremely rare and pose special management problems. Soft tissue leiomyosarcomas

are the principal lesions which come to the attention of the general surgical pathologist. Because of the difference in prognosis it is useful to discuss these as two groups, those arising in the retroperitoneum and body cavities and those arising in the peripheral or somatic soft tissues of the extremities.

Retroperitoneal/abdominal leiomyosarcomas account for about three quarters of all leiomyosarcomas.¹⁰⁻¹⁴ They develop preferentially in women with a peak incidence in the 7th decade. Symptoms are non specific and referable to a mass lesion in most instances. The majority occur in the retroperitoneum followed by pelvic retroperitoneum and abdominal cavity. Virtually all tumors are >5 cm and most >10 cm. when first detected. These lesions vary greatly in the degree of differentiation, but certain generalizations can be made related to malignant features. Virtually all lesions reported as leiomyosarcomas possess some degree of nuclear atypia and minimum mitotic rate of 1-4/10 HPF. In addition, about 50-75% have areas of coagulative necrosis. The prognosis is poor with 80-95% of patients dying of disease within follow up periods ranging from 2-5 yrs.¹⁰⁻¹⁴ Thus far it has been difficult to identify independent prognostic factors in this disease. In particular neither size nor mitotic activity closely correlates with outcome. This probably reflects the fact that in the retroperitoneum sarcomas tend to be extremely large and thus the advantage associated with small tumor size is a moot point.

Somatic soft tissue leiomyosarcomas develop in either superficial (subcutis) or deep soft tissues of the extremities where they are usually intimately associated with a small vessel. Despite this relationship few are associated with symptoms of vascular compromise as occurs with leiomyosarcomas arising from major vessels. These lesions are considerably smaller (averaging approximately 5 cm in diameter) than retroperitoneal leiomyosarcomas when first detected.¹⁵⁻¹⁷ All lesions possess atypia and mitotic activity but the latter varies from as few as <1/10 HPF in our experience. Approximately one half of patients die of metastatic disease. Various prognostic factors have been correlated with outcome including age (>62 yr.), size (>4cm), necrosis, FFCC grade, and vascular invasion,^{15,16} and whether the tumor has been "disrupted" due to a previous biopsy or incomplete excision.¹⁵ The concept that a previous biopsy or incomplete excision places a patient at increased risk to develop metastasis is a relatively novel one in soft tissue. Since "disruption" occurs most often with large, deep lesions, it is not clear whether it represents a "surrogate marker" of large deep lesions or whether it is a reflection of tumor dislodgment and entry into the blood stream. However, it does appear that L-SST have an unexpectedly aggressive course given their overall size and grade when first detected and that feature may well relate to its angiocentricity. Although mitotic activity is certainly important in establishing a diagnosis of malignancy, it has not been possible to closely link actual mitotic rates with outcome.^{15,16} Thus, once the diagnosis of malignancy has been made by a combination of atypia and any level of mitotic activity, the actual level of mitotic activity per se does not provide incremental prognostic information concerning metastatic risk.

SMOOTH MUSCLE TUMORS IN IMMUNOCOMPROMISED PATIENTS

Smooth muscle tumors occur in immunocompromised patients at a greater frequency than the general population. Initially reported following renal transplantation

and immunosuppression primarily in children, smooth muscle tumors have now been reported in patients with various types of organ transplants, in patients with AIDS, and in patients with congenital immunodeficiency.¹⁸⁻²³ The common denominator in all cases appears to be EBV infection in the setting of immunocompromise. EBV can be detected by in situ hybridization in virtually all tumors studied and EBV surface receptor protein (CD21) in some. EBV gene expression patterns correspond to those observed in post-transplantation lymphoproliferative (PT-LPD) and not with other EBV-associated malignancies (e.g. Burkitt's lymphoma)²³. Like PT-LPD, EBV-associated smooth muscle tumors can have a variable outcome depending on the immune status of the patient. Patients have responded to antiviral therapy and others to reduction in immunosuppression, although without such intervention an untoward outcome may be anticipated.

Owing to the paucity of illustrations associated with the sparse number of reports, it is difficult to characterize the tumors. In most cases mitotic activity has been noted. Peculiar to this form of smooth muscle tumor has been the observation that the muscle walls of vessels adjacent to the tumors have displayed proliferative changes suggestive of early or pre-malignant changes. In addition, we have noted infiltration of the tumor by atypical lymphocytes. Whether these changes are sufficiently prevalent to allow the diagnosis of EBV-associated smooth muscle tumors on hematoxylin and eosin stained slides will await further descriptions. Since the immune status of the patient appears to play a more significant role in outcome than an actual histologic assessment, it seems prudent to label these lesions "EBV-associated smooth muscle tumor" rather than leiomyoma or leiomyosarcoma. In fact, it now appears that patients with multiple tumors may in fact have multifocal rather than metastatic disease. This suggestion has been proposed by authors who have noted clonally-distinct EBV populations in different lesions from the same patient.

CONCLUSIONS

To return to our original question, what conclusions can be made concerning benignancy and malignancy in smooth muscle tumors. Because of sample sizes, we cannot categorically rule out the possibility that smooth muscle tumors represent a continuum in which there is variable risk of malignant behavior, as has been suggested for gastrointestinal stromal tumors.

- However, the data suggest that a subset of smooth muscle tumors can comfortably be labelled "leiomyomas."
- Atypia appears to be the most useful way in separating benign smooth muscle tumors from malignant ones. Mitotic activity parallels atypia in the majority of smooth muscle tumors. Somatic leiomyomas tend to have little or no mitotic activity (<1/50 HPF) whereas abdominal/retroperitoneal leiomyomas have low levels (1-5/50 HPF) similar to uterine leiomyomas. Abdominal/retroperitoneal "leiomyomas" with higher levels of mitotic activity are better considered of uncertain malignant potential until further data is forthcoming.

- Smooth muscle tumor with atypia should provisionally be considered malignant and confirmed by identifying mitotic activity through careful observation and sampling. In the absence of mitotic activity, it is probably best to label the lesion of “uncertain malignant potential” since the concept of “symplastic leiomyomas” of soft tissue has not been well established.
- Location appears to be the most important prognostic factor for soft tissue leiomyosarcomas with retroperitoneal lesions having a significantly worse prognosis than somatic soft tissue ones.
- There are virtually no histologic factors that are of prognostic importance for retroperitoneal leiomyosarcomas as the majority of lesions have a fatal outcome regardless of appearance or level of mitotic activity. On the other hand age, size, vascular invasion, and grade seem to influence outcome for somatic leiomyosarcomas. “Disruption” of these tumor also appears important but whether it relates to early access to the blood stream or serves as a surrogate marker for size and depth is unclear.
- EBV-associated smooth muscle tumors occur in the setting of immunocompromise and are best regarded as lesions in which the immune status of the patient is more predictive of outcome than traditional histologic parameters.

References:

1. Myhre-Jensen, O: A consecutive 7-year series of 1331 benign soft tissue tumors: clinicopathologic data: comparison with sarcomas. *Acta orthop scand* 1981;52:287-293.
2. Weiss, SW, Goldblum, JR, "Leiomyosarcoma," in Enzinger and Weiss's *Soft Tissue Tumors*, 4th ed. St Louis, Mosby-Harcourt, 2001, pp. 727-748.
3. Folpe, AL, Gown, AM, "Immunohistochemistry for analysis of soft tissue tumors," in Enzinger and Weiss's *Soft Tissue Tumors*, 4th ed. Weiss, SW, Goldblum, JR, Mosby-Harcourt, St. Louis, 2001.
4. Gabbiani, G, Serini, G: Mechanisms of myofibroblast activity and phenotypic modulation. *Experimental Cell Research* 1999;250:273-283.
5. Eyden, B, The myofibroblast: An assessment of controversial issues and a definition useful in diagnosis and research. *Ultrastructural Pathology* 2001;25:39-50.
6. Kilpatrick, SE, Mentzel, T, Fletcher, CDM: Leiomyoma of deep soft tissue: clinicopathologic analysis of a series. *Am J Surg Pathol* 1994;18:576-582.
7. Fletcher, CDM, Kilpatrick, SE, Mentzel, T: The difficulty of predicting behavior of smooth-muscle tumors in deep soft tissue. (letter). *Am J Surg Pathol* 1995;19:116-117.
8. Billings, SD, Folpe, AL, Weiss, SW: Do leiomyomas of deep soft tissue exist? An analysis of highly differentiated smooth muscle tumors of deep soft tissue supporting two distinct subtypes. *Am J Surg Pathol* 2002;25:1134-1142.
9. Paal, E, Miettinen, M: Retroperitoneal leiomyomas: a clinicopathologic and immunohistochemical study of 56 cases with a comparison to retroperitoneal leiomyosarcomas. *Am J Surg Pathol* 2001;25:1355-1363.
10. Shmookler, BM, Lauer, DH: Retroperitoneal leiomyosarcoma: a clinicopathologic analysis of 36 cases. *Amer J Surg Pathol* 1983;7:269-280.
11. Wile, AG, Evans, HL, Romsdahl, MM: Leiomyosarcoma of soft tissue: a clinicopathologic study. *Cancer* 1981;48:1022-1032.
12. Hashimoto, H, Tsuneyoshi, M, Enjoji, M: Malignant smooth muscle tumors of the retroperitoneum and mesentery: a clinicopathologic analysis of 44 cases. *J Surg Oncol* 1985;28:177-186.
13. Ranchod, M, Kempson, RL: Smooth muscle tumors of the gastrointestinal tract and retroperitoneum. *Cancer* 1977;39:255-262.

14. Rajani, P, Smith, TA, Reith, JD, Goldblum, JR: Retroperitoneal leiomyosarcomas unassociated with the gastrointestinal tract: a clinicopathologic analysis of 17 cases. *Mod Pathol* 1999;12:21-28,.
15. Farshid, G, Pradhan, M: Goldblum, J, Weiss, SW: Leiomyosarcoma of somatic soft tissues: a tumor of vascular origin with multivariate analysis of outcome in 42 cases. *Am J Surg Pathol* 2002;26:14-24.
16. Gustafson, P, Willen, Baldestorp, B et al: Soft tissue leiomyosarcoma: a population-based epidemiologic and prognostic study of 48 patients including DNA content. *Cancer* 1992;70:114-119.
17. Hashimoto, H, Daimaru, Y, Tsuneyoshi, M, Enjoji, M: Leiomyosarcoma of the external soft tissues: Clinicopathologic, immunohistochemical, and electron microscopic study. *Cancer* 1986;57:2077-2088.
18. Boman, F, Gultekin, H, Dickman, PS, Latent Epstein-Barr virus infection demonstrated in low grade leiomyosarcomas of adults with acquired immunodeficiency syndrome, but not in adjacent Kaposi's lesion or smooth muscle tumors in immunocompetent patients. *Arch Pathol Lab Med* 1997; 121:834-838.
19. Brichard, B, Smets, F, Sokal, E, Clapuyt, P et al: Unusual evolution of an Epstein Barr virus-associated leiomyosarcoma occurring after liver transplantation. *Pediatric Transplantation* 2001;5:365-369.
20. Lee, E, Locker, Nalesnik, M, et al: The association of Epstein Barr virus with smooth muscle tumors occurring after organ transplantation. *N Engl J Med* 1995;332:19-25.
21. McClain, KL, Leach, CT, Jesnon, HB et al: Association of Epstein-Barr virus with leiomyosarcomas in young people with AIDS. *N Engl J Med* 1995;332:12-18.
22. Jenson, HB, Leach, CT, McClain, KL, et al: Benign and malignant smooth muscle tumors containing Epstein Barr virus in children with AIDS. *Leukemia and Lymphoma* 1997;27:303-14.
23. Rogatsch, H, Bonatti, H, Menet, A et al: Epstein-Barr virus-associated multicentric leiomyosarcoma in an adult patient after heart transplantation: case report and review of the literature. *Amer J Surg Pathol* 2000;245:614-21.